

Original Article

Structural observations on spermatogenic cells of Japanese quail (*Coturnix coturnix japonica*) pre-pubertally exposed to dibutyl phthalate: a light and transmission electron microscopy study

Musa Zakariah^{a, d *}, Reneilwe. A. Molele^c, Mohammed A. A. Mahdy^e, Mohammed I. A. Ibrahim^f, Lyndy. J. McGaw^b

^a *Department of Anatomy and Physiology, Faculty of Veterinary Science, University of Pretoria, Private Bag X04, Onderstepoort, Pretoria 0110, South Africa.*

^b *Phytomedicine Programme, Department of Paraclinical Sciences, Faculty of Veterinary Science, University of Pretoria, Private Bag X04, Onderstepoort, 0110 Pretoria, South Africa.*

^c *Department of Production Animal Studies, Faculty of Veterinary Science, University of Pretoria, Private Bag X04, Onderstepoort, Pretoria, 0110, South Africa*

^d *Department of Veterinary Anatomy, Faculty of Veterinary Medicine, PMB 1069 University of Maiduguri, Maiduguri, Nigeria.*

^e *Department of Anatomy and Embryology, Faculty of Veterinary Medicine, South Valley University, Qena 83523, Egypt*

^f *Department of Basic Science, University of West Kordofan, West Kordofan State, Sudan.*

*Corresponding author: M. Zakariah.

Department of Veterinary Anatomy, Faculty of Veterinary Medicine, PMB 1069 University of Maiduguri, Maiduguri, Nigeria.

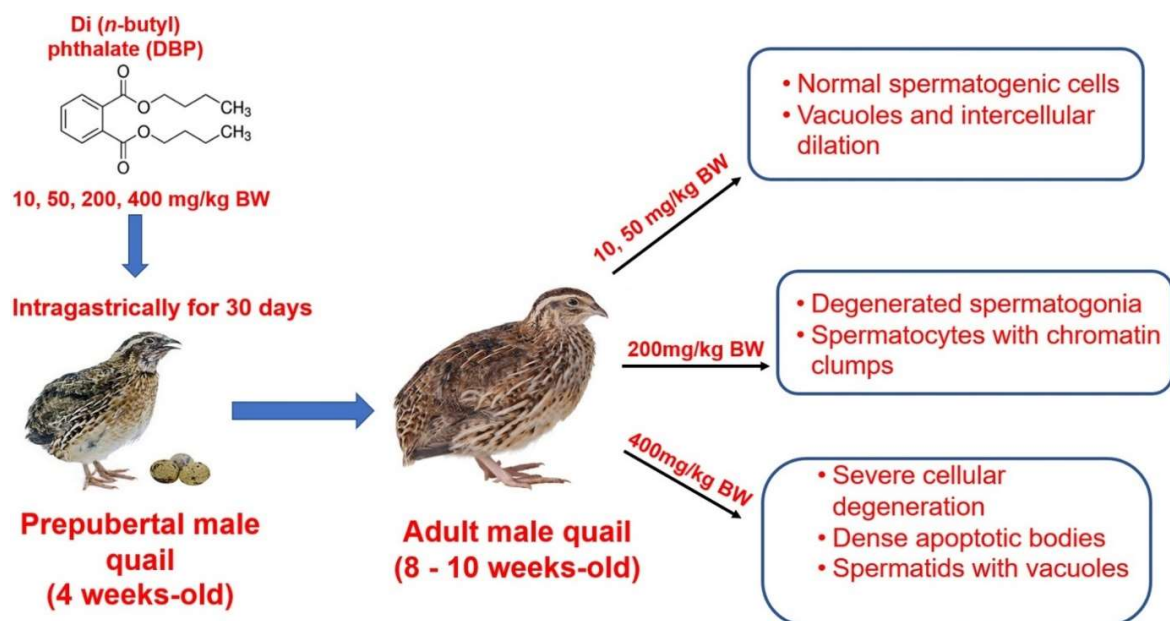
Email: mzakariah@unimaid.edu.ng

Tel.: +2347036155225.

Highlights

- Dibutyl Phthalate (DBP) induces germ cell degenerations in the testis of the Japanese quail.
- Spermatogenic cells of the Japanese quail seem/appear to be more sensitive to DBP.
- Electron microscopy is a sensitive technique in evaluating germ cells.
- DBP is a potent disruptor of spermatogenesis in the quail.
- Only spermatids were recognized in the high dose of the DBP treated group.

Graphical abstract



Abstract

Exposure to dibutyl phthalate (DBP) induces testicular damage in mammals. However, studies on the effects of DBP on spermatogenic cells in birds are grossly lacking. Therefore, this study was designed to determine the effects of the pre-pubertal exposure to DBP on the histology and ultrastructure of spermatogenic cells in the testis of adult Japanese quail (*Coturnix coturnix japonica*). The birds were randomly divided into five dosage groups at the age of 4 weeks. The control group received a corn oil vehicle only

(a dose of 1 ml/kg body weight), while the other four experimental groups received a daily dosage of 10, 50, 200, 400 mg/kg body weight of DBP (dissolved in corn oil), respectively with the aid of gastric lavage, for 30 days. Testicular samples were processed and examined by light microscopy and transmission electron microscopy. Histopathological evaluation revealed vacuole formation, germ cell degenerations, and the absence of spermatogenic cell series. Ultrastructurally, chromatin clumps in spermatocyte and degenerated spermatogonia with ruptured nuclear membranes resting on the distorted basement membranes were observed. Others were intracytoplasmic vacuoles in round spermatids and fragments of dense apoptotic bodies. In conclusion, the findings of the present study reveal that spermatogenic cells of Japanese quails seem to be more sensitive to DBP-induced degeneration compared to mammalian species studied. The Japanese quail could be used to monitor environmental contamination with low doses of DBP.

Keywords: Dibutyl phthalate; Degeneration; Japanese quails; Spermatogenic cells

1. Introduction

Phthalate esters (PAEs) have been used as plasticizers since 1921. They are added to polyvinyl chloride (PVC) to increase its strength, durability, and flexibility (FDA, 2001). Phthalates have attracted considerable concerns because millions of tons of this chemical are produced annually and used for the manufacturing of plastics (Guerra et al., 2010).

Dibutyl phthalate (DBP) is one of the PAEs that have been implicated in male infertility (Boekelheide et al. 2009, Salama et al. 2013, Lara et al. 2017, Ma et al. 2017). They are ubiquitously distributed as, these chemicals are not covalently bond to the

polymer matrix and, as a result, they leach easily into the environment (FDA, 2001) and accumulate in the air, freshwater, wastewater, groundwater, and soil (Gao & Wen, 2016).

PAEs are classified as endocrine-disrupting chemicals (EDCs) (Biro et al., 2013). Their chemical structures are closely related to those of hormones. They can bind directly either as agonists or antagonists to hormone receptors, thereby disrupting or enhancing the effect of the hormones (Swedenborg et al., 2009). In addition, EDCs interfere with the function of steroidogenic enzymes responsible for the biosynthesis of active steroid hormones, such as cytochrome P450 enzymes, steroid reductases, and hydroxysteroid dehydrogenases (Sanderson, 2006, Lara et al. 2017). Furthermore, they may cross the placental barrier and induce developmental disturbances to the offspring (Diamanti-Kandarakis et al., 2009).

In males, Sertoli cells, germ cells, and interstitial Leydig cells are targets of phthalates (Ward et al., 1998). Exposure to phthalates is associated with increasing incidences of hormone-associated diseases, such as genital abnormality, abnormal sperm morphology, and prostate cancer (Crain et al., 2008). In addition, phthalates and their metabolites can hamper motility, concentration, and morphology of germ cells, as well as increase the rate of DNA damage (Karačonji et al., 2017). Furthermore, phthalates induce hypospadias, abnormal urethral openings, in young males (Cai et al., 2015).

Di-n-butyl phthalate (DBP) is one of the most extensively used phthalates in industrial manufacturing of several products, such as cosmetics, children's toys, car interiors, food packaging materials, inks, adhesives, and paints (Przybylińska and Wyszowski, 2016, Gao & Wen, 2016). Exposure to DBP occurs through oral ingestion, the dermal route, or inhalation. Metabolites of phthalate have been detected in urine, seminal fluid, saliva, and

breast milk (Wittassek et al., 2011, Swan, 2008). DBP reduces the production of testosterone and insulin-like factor3 (insl3) mRNA in fetal rat testes, thereby disrupting the spermatogenic process (Wilson et al., 2004). Even though the exact mechanism of action of DBP is still unclear, the literature on the effects of DBP in the male reproductive system of mammalian species is well documented (Nelli and Pamanji, 2017, Spade et al., 2015, Aly et al., 2016, Park et al., 2002). However, there is insufficient data on the effects of DBP on the biology of spermatogenic cells in avian species. Therefore, the present study aims to investigate the effects of DBP exposure on developing germ cells in the testis of Japanese quail.

2. Materials and Methods

2.1 Chemical used for the study

The test compound used in the present study was Di (*n*-butyl) phthalate DBP (CAS Number 84-74-2 technical grade, purity>99.8%, PN61840625001730) (Sigma-Aldrich (Pty) Ltd, Johannesburg, South Africa).

2.2 Experimental animals and management

Newly hatched, pre-sexed male Japanese quails (*Coturnix coturnix japonica*) (n=25) were obtained from the Aviary Unit, Irene Animal Improvement Research Station, Pretoria. The quails were acclimatized for two weeks prior to the experiment at the poultry facility (brooder cages) located in the Poultry Research Unit (University of Pretoria). Then birds were transferred into battery cages of dimensions 49cm x 95cm x 51cm. At hatch, the temperatures were first adjusted at 35-37°C and then slowly decreased by 0.5°C/day

until a temperature of 16°C to 23°C was reached at 4 weeks of age. Thereafter, the birds were kept under a controlled photoperiod (16L: 8D, schedule of light-dark cycle), at 25°C \pm 2°C with a relative humidity of 50% \pm 5%, until the age of 10 weeks.

The birds were identified individually using wing-tags, fed on a standard commercial diet with rich protein content (Obaro Feeds, Pretoria, South Africa), and tap water was provided *ad libitum*. All procedures were carried out in line with the guidelines for the care and use of laboratory and research animals. The experimental protocol was approved by the Animal Ethics Committee (AEC) of the University of Pretoria, South Africa (issued vide No. AEC/A065-12).

2.3 Animal exposure and dosing regimen

The experiment was performed in harmony with the guidelines for avian toxicity testing studies as stipulated by the Organization for Economic Co-operation and Development (OECD guideline, 2010). DBP (the test compound) was dissolved in a vehicle corn oil base and used for the treatment groups. At the age of 4 weeks, the birds were randomly divided into five dosage groups. The control group received a corn oil vehicle only (at a dose of 1 ml/kg body weight), while the other four experimental groups received a daily dosage of 10, 50, 200, 400 mg/kg body weight of DBP (dissolved in corn oil) intra-gastrically, respectively, for a period of 30 days. Food intake and clinical signs or any signs of abnormal behaviour were monitored daily throughout the dosing period.

2.4 Necropsy and organ harvesting

After the 30day experimental period, the quails (n=5) each from the control and experimental groups were euthanized, using carbon-dioxide (CO₂) inhalation anaesthesia. Testes (left and right) from both control and DBP-exposed groups, were dissected carefully from the remainder of the adherent tissues and fixed immediately.

2.5 Transmission electron microscopy

Small tissue samples were fixed in 2.5% glutaraldehyde in 0.075M phosphate buffer (pH 7.4) for 24 h. Then the tissue samples were post-fixed in 0.5% osmium tetroxide for 2 h. The tissue samples were then washed in phosphate buffer (pH 7.4), dehydrated in an ascending series of ethanol concentrations and embedded in epoxy:resin at a ratio of 1:2 for 1 h, 1:1 for 2 h and 100% resin overnight. Semi-thin sections, 1 µm-thick, were cut, using a diamond knife and stained with toluidine blue according to the previously described method (Morikawa et al. 2018). Stained sections were examined and photographed with a DP72 camera attached to Olympus BX 63 microscope (Olympus Corporation, Tokyo, Japan). Ultra-thin sections were cut, using a diamond knife, mounted on onto copper grids, and double-stained with uranyl acetate and lead citrate. The samples were examined and photographed with a Philips CM10 transmission electron microscope (FEI, Hillsboro, The Netherlands), tethered to an Olympus Mega View III imaging system.

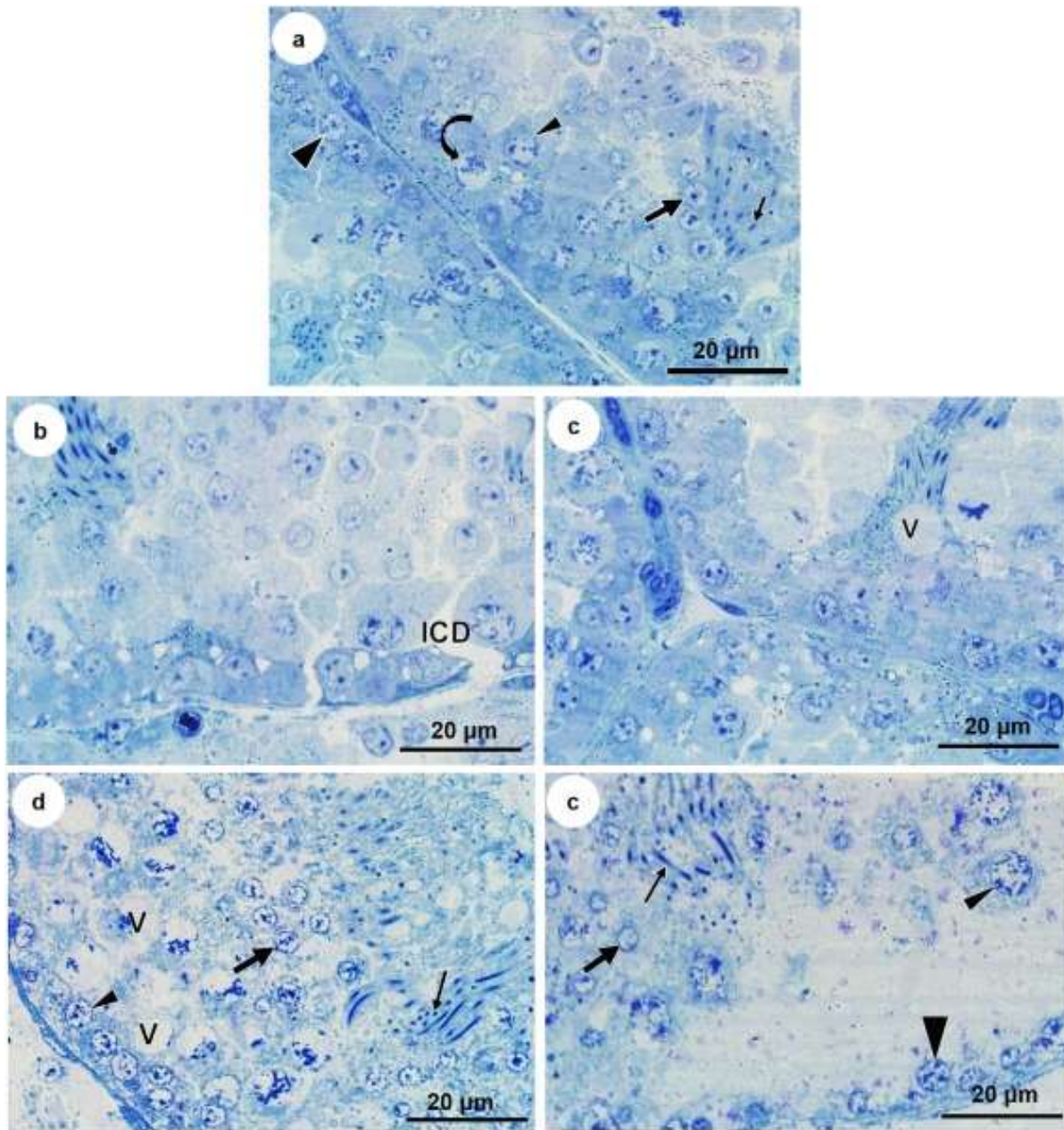


Figure 1. Semithin sections of seminiferous tubules of male Japanese quail from (a) the control and (b) the DBP 10 mg/kg body weight treatment group, (c) the DBP 50 mg/kg body weight treatment group, (d) the DBP 200mg/kg body weight treatment group, and (e) the DBP 400 mg/kg body weight treatment group. Note: normal germ cells in the control group. **Thick arrowhead** = Spermatogonia, **curved arrow** = primary spermatocyte, **thin arrowhead** = secondary spermatocyte, **thick arrow** = round spermatid, **thin arrow** = elongated spermatid. **ICD** = intercellular dilation, **V** = vacuole. Toluidine blue stain.

3. Results

3.1 Light microscopy

3.1.1 The control group

In the control birds, the spermatogenic cells in the seminiferous tubules were morphologically normal. The shape and size of the seminiferous tubules appeared to be uniform. The spermatogonia, spermatocytes, round and elongated spermatids all appeared to be normal and were arranged in an orderly fashion within the epithelium of the regularly shaped seminiferous tubules (Figure 1a).

3.1.2 Low and medium doses of DBP treatment groups (10 mg/kg and 50 mg/kg body weight).

There were no obvious morphological differences between the low and medium dose-exposed groups (10 mg/kg and 50 mg/kg body weight of DBP) respectively. Spermatogenic cells with normal morphology, however, displayed vacuole and intercellular dilation (Figure 1b, 1c).

3.1.3 High dose DBP treatment groups (200 mg/kg and 400 mg/kg body weight).

Birds treated with 200 mg/kg body weight showed a presence of spermatogenic cell series, but with frequent vacuolizations (Figure. 1d). In the 400 mg/kg body weight of DBP treated group, although evidence of germ cells was observed as in other treatment groups, they were sparsely distributed in the seminiferous epithelium (Figure. 1e).

3.2 Transmission electron microscopy

3.2.1 The control group

In the control birds, the seminiferous epithelium architecture appeared to be normal, as spermatogonia, spermatocytes, round, and elongated spermatids all had intact nuclear membranes (Figure 2).

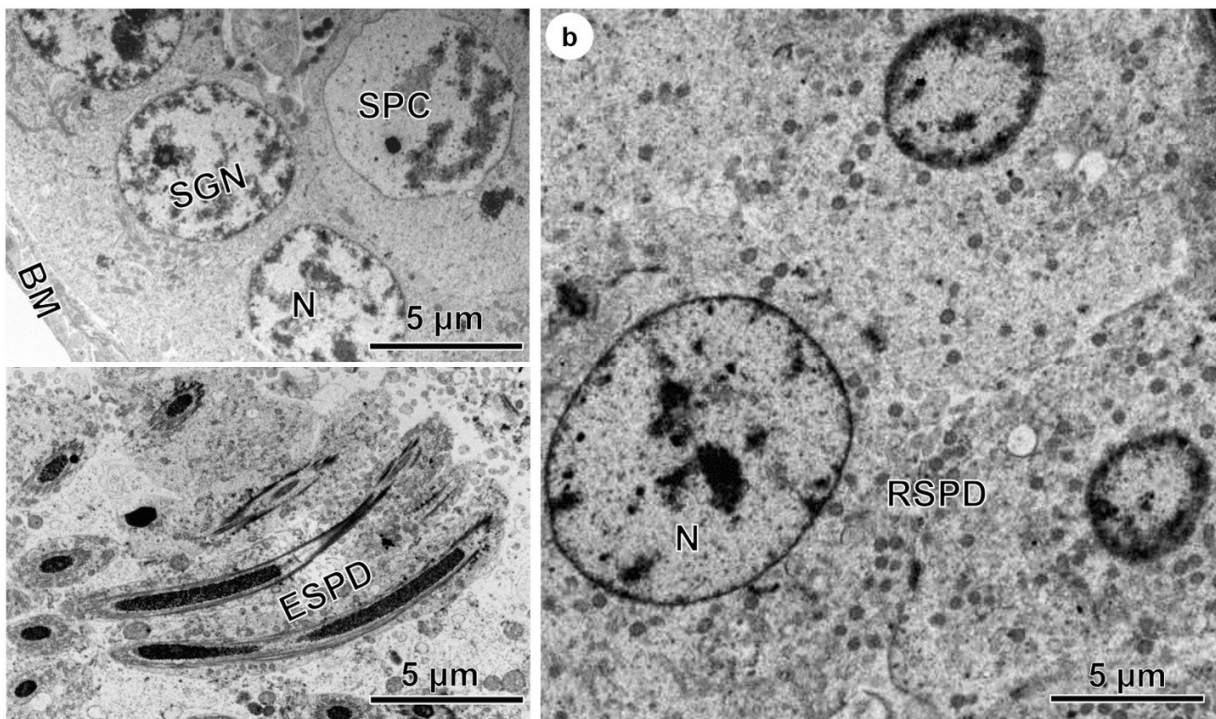


Figure 2. Electron micrographs of seminiferous tubules of control birds (a, c, b). **SGN** = spermatogonia, **SPC** = spermatocyte, **RSPD** = round spermatid, **ESPD** = elongated spermatid, **N** = nucleus, **BM** = basement membrane.

3.2.2 Low and medium DBP dose groups (10 mg/kg and 50 mg/kg body weight).

The low- and medium-dose treatment groups showed some normal germ cells in the seminiferous epithelium. Degenerative changes such as irregular nuclear membrane of spermatocyte, ruptured nuclear membrane of spermatogonia, and intercellular dilations were observed (Figure 3).

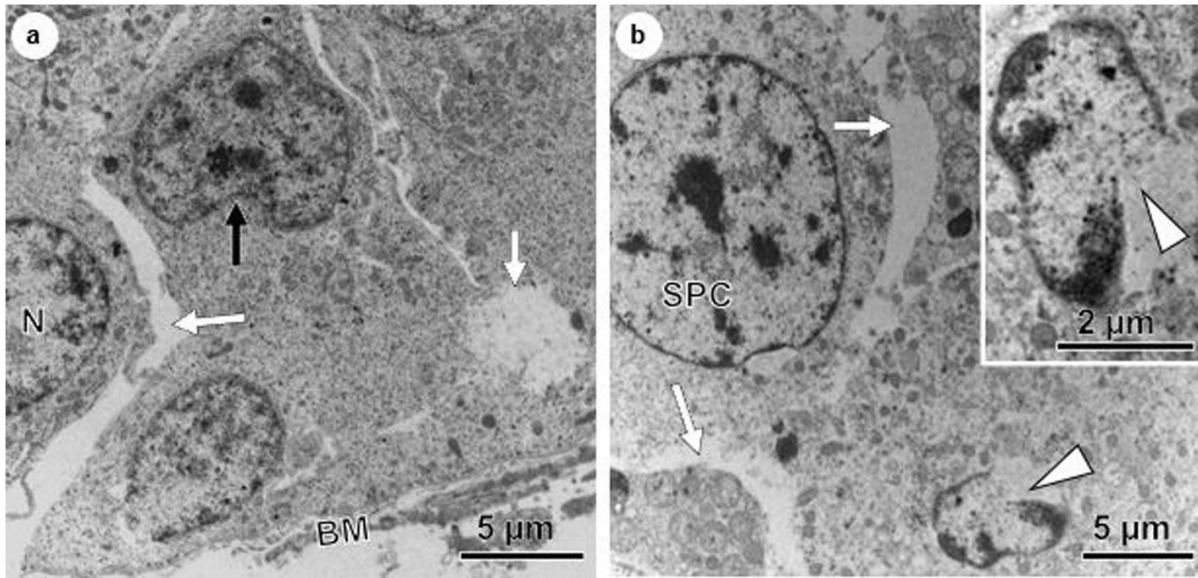


Figure 3. Electron micrographs of seminiferous tubules of birds exposed to DBP at (a), 10 mg/kg body weight treated group and (b), 50 mg/kg body weight treated group. **Black arrow** = irregular nuclear membrane, **white arrows** = intercellular dilations, **white arrowheads** = rupture of nuclear membrane, **SPC** = spermatocyte, **N** = nucleus, **BM** = basement membrane.

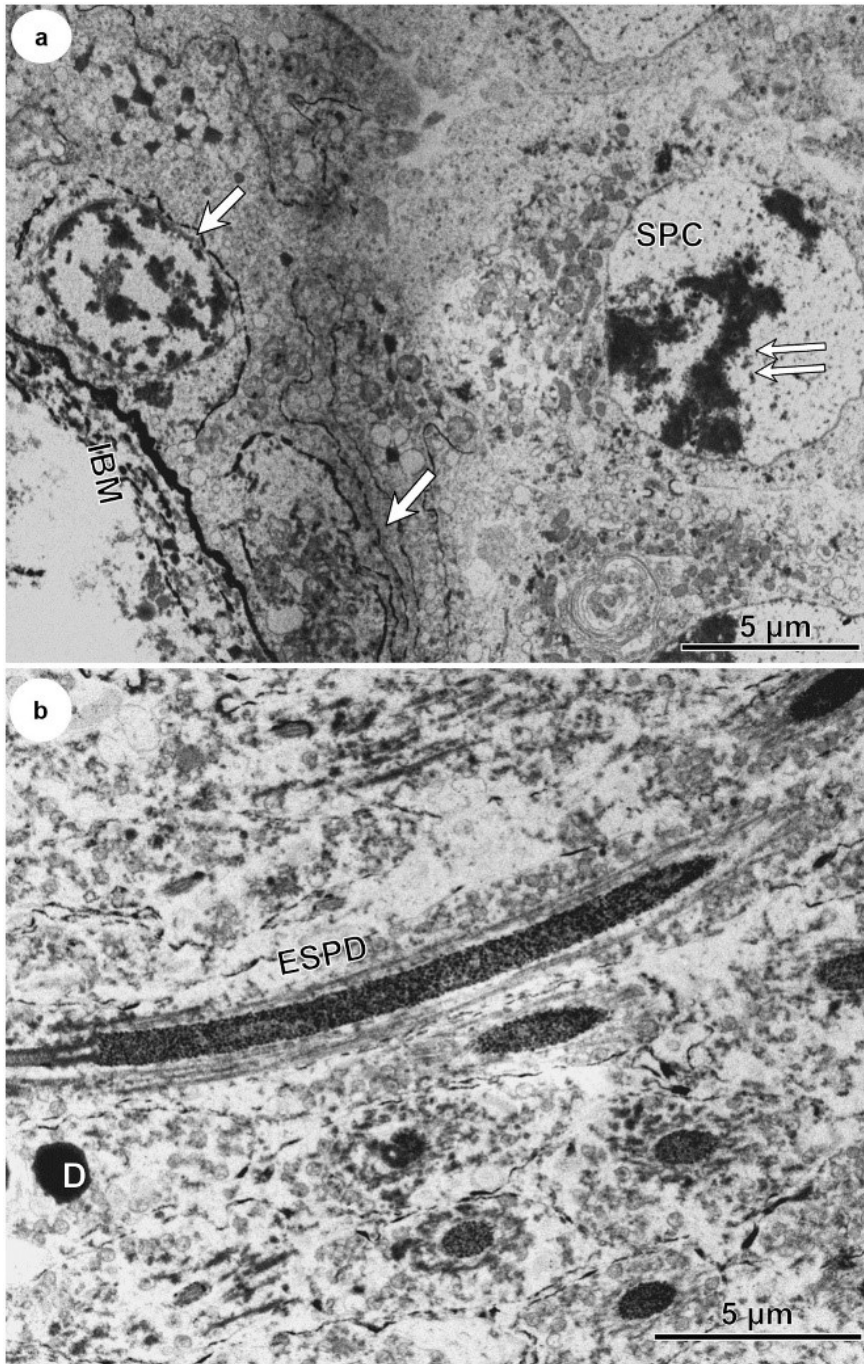


Figure 4. Electron micrographs of seminiferous tubules of birds exposed to DBP 200 mg/kg body weight treated group showing **D** = dense body, **SPC** = spermatocyte, **ESPD** = elongating spermatid, **IBM** = irregular basement membrane, **white arrows** = degenerated spermatogonia, **Double arrows** = chromatin clumps, **D** = dense body.

3.2.3 High dose DBP treatment groups (200 mg/kg and 400 mg/kg body weight).

In the 200 mg/kg body weight, obvious degenerative changes were observed, such as degenerated spermatogonia resting on an irregular basement membrane, and chromatin clumps in the nuclei of spermatocytes (Figure 4). In the 400 mg/kg body weight of DBP, cellular degenerations were more severe, and dense apoptotic bodies, as well as intracytoplasmic vacuoles in round spermatids, were observed (Figure 5).

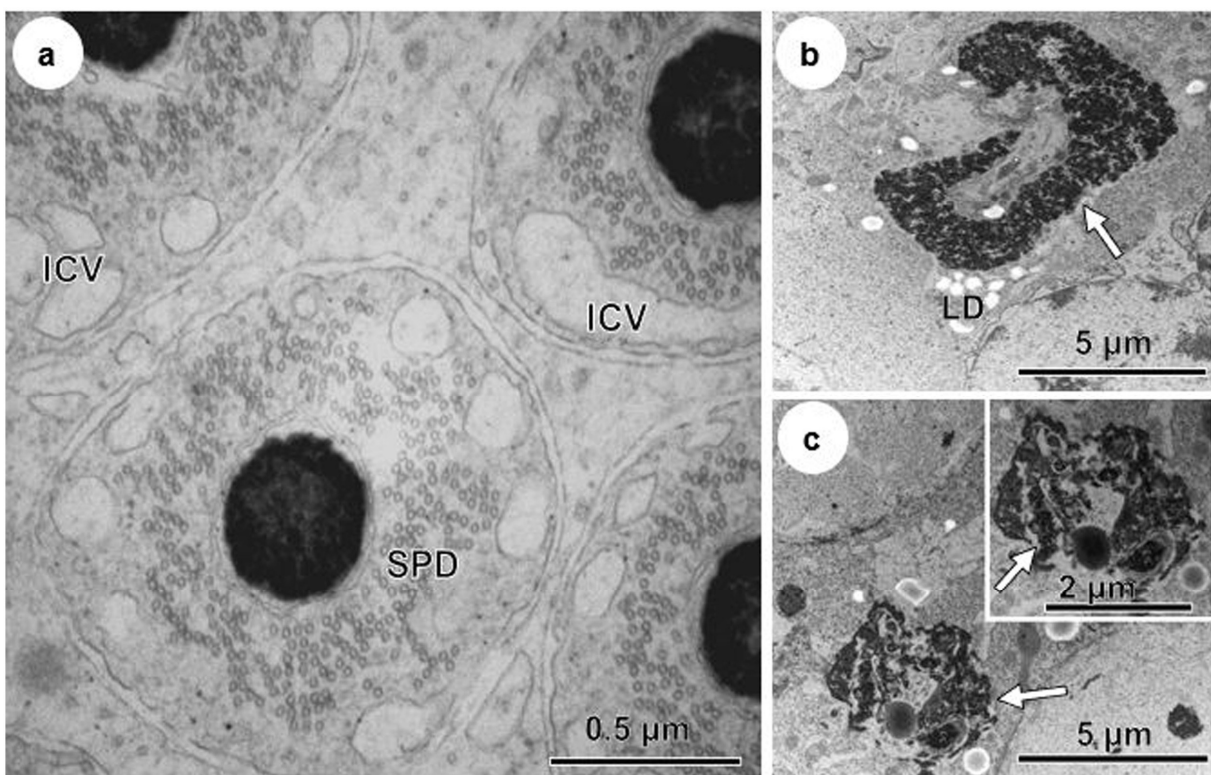


Figure 5. Electron micrographs of seminiferous tubules of birds exposed to DBP 400mg/kg body weight showed apoptotic bodies (**white arrows**), intra cytoplasmic vacuoles (**ICV**), lipid droplets (**LD**). **SPD** = spermatid.

4. Discussion

This study showed that germ cells of the male Japanese quails are highly susceptible to degenerative changes induced by DBP. These changes were dose-dependent. Studies in mammalian species have reported considerable evidence that phthalates induce different reproductive effects in males. Some of these effects include disruption of reproductive development and spermatogenesis, and alteration of steroid hormone balance, all of which can lead to testicular injury, oxidative stress and cell death (Arif and Khan, 2010, Lara et al. 2017).

In the present study, the dose-dependent histopathological changes in the seminiferous tubules of Japanese quail induced by DBP were associated with vacuole formations in the seminiferous epithelium, spermatogonial and spermatocyte degenerations, and loss of spermatogenic cells. This is in accordance with the reports of Higuchi et al. (2003) in rabbits, Lee and Veeramachaneni (2005) in frogs, Bao et al. (2011) in rats, and Bello et al. (2014) in Japanese quails.

Unlike the reports of Bello et al. (2014) that focused on the effects of DBP on some key enzymes that are involved in the pathways of testicular steroidogenesis, as some of these steroids play a significant role in regulating spermatogenesis. Even though, they reported that the steroidogenic effects of DBP were dose-dependent in a similar fashion with the observable features of germ cell degenerations in the reports of Lara et al. (2017) in rats and Japanese quails in the present study. Where the level of testicular degenerations increased with the increasing dosage levels of DBP. The earlier findings of Yin et al. (2016), that DBP esters cause a reduction in germ cell numbers, which

consequently creates large intervening spaces in the seminiferous epithelium in rats, were similar to those observed in the present study.

The birds exposed to low and medium doses (10 and 50) mg/kg body weight of DBP, respectively, displayed minor histopathological changes in the seminiferous tubules. The present findings are comparable to those of Bao et al. (2011) and Nelli and Pamanji (2017) who reported that male rats exposed to doses of (100 and 200) mg/kg did not show obvious histopathological changes. However, in the birds on high dosage levels (200 and 400 mg/kg), loss of germ cells, degenerative changes of spermatogonia and spermatocytes were observed. Rats appear to be less sensitive to DBP because those administered with 250 mg/kg body weight of DBP displayed no obvious histopathological changes (Zhou et al., 2010). However, they observed severe alterations in the seminiferous tubules of rats treated with a higher dose of 500 mg/kg body weight of DBP. The main histopathological changes they noted were atrophy of the seminiferous tubule, the disintegration of the seminiferous tubule epithelial cells, and a marked decrease in spermatogenic cells, which are similar to those observed in the quail administered 400 mg/kg body weight, in the present study.

There are species differences in the susceptibility of common laboratory species, such as rat, mouse, guinea pig, and hamster, to testicular injury induced by DPB (Gray et al., 1982). These differences could be due to species variability in DBP metabolism (Foster et al., 1983). This might explain the disparity in histopathological changes reported in the seminiferous tubule, due to similar dosage levels, in the mouse (Moody et al., 2013), rat (Zhou et al. 2010), and in the present study on the quail.

Aly et al. (2016) reported atrophy of seminiferous tubules and, thus, the absence of germ cells in the testis of rats at the dose of 600 mg/kg body weight of DBP, which is similar to the observations in the present study at the doses of 200 and 400 mg/kg body weight of DBP. This is evident, as most of the reported data on mammalian species, such as rats exposed to the same doses of DBP (200 and 400 mg/kg body weight) as in the present study showed no obvious histopathological changes (Aly et al. 2016, Lara et al. 2017, Nelli and Pamanji, 2017). It is, therefore, logical to propose that the seminiferous tubule of the Japanese quail is more sensitive than the mammalian tubule to DBP administration.

Ultrastructurally, alterations in germ cells observed in the present study were also dose-dependent. In the low and medium (10 and 50) dose levels of DBP-treated groups, abnormalities, such as condensed chromatin material, irregular nuclear membrane, rupture of the nuclear membrane, and intercellular dilations were observed. These are reminiscent of earlier findings by Yin et al. (2016) in rats administered a higher dose, 500mg/kg body weight, of DBP.

In the 200 mg DBP-treated group, degenerated spermatogonia resting on an irregular basement membrane were observed. Similar findings have been reported by Alam et al. (2010), Aly et al. (2016), and Yin et al. (2016) in rats, albeit at a higher dose (500 mg/kg body weight). A very distinct feature observed in the 400mg dosed birds, was the severe structural derangement of all germ cells except the round spermatids which, however, displayed intra-cytoplasmic vacuoles and debris of dense apoptotic bodies. This level of degeneration has not been described in mammals administered with a similar dose level of DBP. The lack of significant structural changes in round spermatids unlike

other germ cell series at the dosage of 400mg/kg of DBP could be due to the compact nature of their nuclei; nuclei are more compact in higher, elongating, and elongated spermatids (Aire, 2018). Aire (2018) reported that during normal spermiogenesis in birds, round spermatids drastically reduce in size and lose 96% of their nuclear volume. This could possibly render the spermatid nucleus less susceptible to injury than other germ cells that are relatively larger in size, as most germ cell deaths in the quail, under normal conditions, are usually spermatogonia and spermatocytes (Zakariah et al. 2020).

In conclusion, the present study showed that prepubertal exposure of male Japanese quails to DBP induced histological and ultrastructural alterations in the seminiferous epithelium in a dose-dependent manner. The present findings showed that the germ cells of the male Japanese quails were highly susceptible to degenerative changes induced by DBP. It is suggested that seminiferous tubules of the Japanese quail are more sensitive than the mammalian seminiferous tubule to DBP administration. Therefore, the Japanese quail appears to be a good research model to study the effects of low doses of DBP on the seminiferous epithelium. It also could be used to monitor environmental contamination with low doses of DBP.

Competing interests

The authors have no competing interests to declare.

Acknowledgment

The authors appreciate the technical support received from Lizette du Plessis and Antoinette Lensink of the Electron Microscopy Unit, Department of Anatomy and Physiology, Faculty of Veterinary Science, University of Pretoria, South Africa. The study was funded by National Research Foundation (NRF) of South Africa.

References

- Abdulwahid, A. I. & Ahmad, K. H. 2010. Environmental toxins and Parkinson's disease: putative roles of impaired electron transport chain and oxidative stress. *Toxicology and Industrial Health*, 26, 121-128.
- Aire, T. A. 2018. Spermatogenesis and Spermogenesis, Birds. In M. K. Skinner (Ed.), *Encyclopedia of Reproduction*, 6, 313-320. Academic Press:Elsevier <http://dx.doi.org/10.1016/B978-012-809633-8.20573-6>
- Alam, M. S., Andrina, B. B., Tay, T. W., Tsunekawa, N., Kanai, Y. & Kurohmaru, M. 2010. Single administration of di (n-butyl) phthalate delays spermatogenesis in prepubertal rats. *Tissue and Cell*, 42, 129-135.
- Aly, H. A., Hassan, M. H., El-Beshbishy, H. A., Alahdal, A. M. & Osman, A. M. 2016. Dibutyl phthalate induces oxidative stress and impairs spermatogenesis in adult rats. *Toxicology and Industrial Health*, 32, 1467-1477.
- Bao, A. M., Man, X. M., Guo, X. J., Dong, H. B., Wang, F. Q., Sun, H., Wang, Y. B., Zhou, Z. M. & Sha, J. H. 2011. Effects of di-n-butyl phthalate on male rat reproduction following pubertal exposure. *Asian Journal of Andrology*, 13, 702.
- Bello, U. M., Madekurozwa, M. C., Groenewald, H. B., Aire, T. A. & Arukwe, A. 2014. The effects on steroidogenesis and histopathology of adult male Japanese quails (*Coturnix coturnix japonica*) testis following pre-pubertal exposure to di (n-butyl) phthalate (DBP). *Comparative Biochemistry and Physiology Part C: Toxicology & Pharmacology*, 166, 24-33.
- Biro, F. M., Greenspan, L. C., Galvez, M. P., Pinney, S. M., Teitelbaum, S., Windham, G. C., Deardorff, J., Herrick, R. L., Succop, P. A., Hiatt, R. A., Kushi, L. H. &

- Wolff, M. S. 2013. Onset of breast development in a longitudinal cohort. *Pediatrics*, 132, 1019-27.
- Boekelheide, K., Kleymenova, E., Liu, K., Swanson, C., & Gaido, K. W. (2009). Dose-dependent effects on cell proliferation, seminiferous tubules, and male germ cells in the fetal rat testis following exposure to di (n-butyl) phthalate. *Microscopy research and technique*, 72, 629-638.
- Cai, H., Zheng, W., Zheng, P., Wang, S., Tan, H., He, G. & Qu, W. 2015. Human urinary/seminal phthalates or their metabolite levels and semen quality: A meta-analysis. *Environmental Research*, 142, 486-94.
- Crain, D. A., Janssen, S. J., Edwards, T. M., Heindel, J., Ho, S. M., Hunt, P., Iguchi, T., Juul, A., Mclachlan, J. A., Schwartz, J., Skakkebaek, N., Soto, A. M., Swan, S., Walker, C., Woodruff, T. K., Woodruff, T. J., Giudice, L. C. & Guillette, L. J., Jr. 2008. Female reproductive disorders: the roles of endocrine-disrupting compounds and developmental timing. *Fertility and Sterility*, 90, 911-40.
- Diamanti-Kandarakis, E., Bourguignon, J.-P., Giudice, L. C., Hauser, R., Prins, G. S., Soto, A. M., Zoeller, R. T. & Gore, A. C. 2009. Endocrine-disrupting chemicals: an Endocrine Society scientific statement. *Endocrine Reviews*, 30, 293-342.
- FDA 2001. US Food Drug Administration, Safety assessment of Di-(2-ethylhexyl) phthalate (DEHP) released from PVC medical devices. Center for Devices and Radiological Health, 119.
- Foster, P. M., Cook, M. W., Thomas, L. V., Walters, D. G., Gangolli, S. D. 1982. Differences in urinary metabolic profile from di-nbutyl phthalate-treated rats and

- hamsters: A possible explanation for species differences in susceptibility to testicular atrophy. *Drug Metab Dispos* 11(1):59-61
- Gao, D. W., & Wen, Z. D. 2016. Phthalate esters in the environment: A critical review of their occurrence, biodegradation, and removal during wastewater treatment processes. *Science of the total Environment*, 541, 986-1001.
- Gray, T. J., Rowland, I. R., Foster, P. M. & Gangolli, S. D. 1982. Species differences in the testicular toxicity of phthalate esters. *Toxicol. Lett.* 11, 141–147.
- Guerra, M. T., Scarano, W. R., De Toledo, F. C., Franci, J. A. & Kempinas, W. D. G. 2010. Reproductive development and function of female rats exposed to di-n-butyl-phthalate (DBP) in utero and during lactation. *Reproductive Toxicology*, 29, 99-105.
- Higuchi, T. T., Palmer, J. S., Gray Jr, L. E. & Veeramachaneni, D. R. 2003. Effects of dibutyl phthalate in male rabbits following in utero, adolescent, or postpubertal exposure. *Toxicological Sciences*, 72, 301-313.
- Karačonji, I. B., Jurica, S. A., Lasić, D. & Jurica, K. 2017. Facts about phthalate toxicity in humans and their occurrence in alcoholic beverages. *Archives of Industrial Hygiene and Toxicology*, 68, 81-92.
- Lara, N. L., van den Driesche, S., Macpherson, S., França, L. R., & Sharpe, R. M. (2017). Dibutyl phthalate induced testicular dysgenesis originates after seminiferous cord formation in rats. *Scientific reports*, 7, 1-13.
- Lee, S. K. & Veeramachaneni, D. R. 2005. Subchronic exposure to low concentrations of di-n-butyl phthalate disrupts spermatogenesis in *Xenopus laevis* frogs. *Toxicological Sciences*, 84, 394-407.

- Ma, T., Yin, X., Han, R., Ding, J., Zhang, H., Han, X., & Li, D. (2017). Effects of in utero exposure to di-n-butyl phthalate on testicular development in rat. *International journal of environmental research and public health*, *14*, 1284.
- Moody, S., Goh, H., Bielanowicz, A., Rippon, P., Loveland, K. L. & Itman, C. 2013. Prepubertal mouse testis growth and maturation and androgen production are acutely sensitive to di-n-butyl phthalate. *Endocrinology*, *154*, 3460-3475.
- Nelli, G. & Pamanji, S. R. 2017. Di-n-butyl phthalate prompts interruption of spermatogenesis, steroidogenesis, and fertility associated with increased testicular oxidative stress in adult male rats. *Environmental Science and Pollution Research*, *24*, 18563-18574.
- OECD 2010. OECD Guideline for the Testing of Chemicals, No. 429. Skin Sensitisation: Local Lymph Node Assay. Organisation for Economic Co-operation and Development Paris, France. <https://doi.org/10.1787/20745788>
- Park, J. D., Habeebu, S. S. & Klaassen, C. D. 2002. Testicular toxicity of di-(2-ethylhexyl) phthalate in young Sprague–Dawley rats. *Toxicology*, *171*, 105-115.
- Przybylińska, P. A. & Wyszowski, M. 2016. Environmental contamination with phthalates and its impact on living organisms. *Ecological Chemistry and Engineering*, *23*, 347-356.
- Salama, R. M., Mansour, F. K., El-Safti, F., & El-Sherif, N. M. (2013). The toxic effect of phthalate on testes of albino rats and the possible protective role of curcumin. *Menoufia Medical Journal*, *26*, 23.

- Spade, D. J., Hall, S. J., Wilson, S. & Boekelheide, K. 2015. Di-n-butyl phthalate induces multinucleated germ cells in the rat fetal testis through a nonproliferative mechanism. *Biology of Reproduction*, 93, 110, 1-10.
- Swan, S. H. 2008. Environmental phthalate exposure in relation to reproductive outcomes and other health endpoints in humans. *Environmental Research*, 108, 177-184.
- Swedenborg, E., Rüegg, J., Mäkelä, S. & Pongratz, I. 2009. Endocrine disruptive chemicals: mechanisms of action and involvement in metabolic disorders. *Journal of Molecular Endocrinology*, 43, 1-10.
- Ward, J. M., Peters, J. M., Perella, C. M. & Gonzalez, F. J. 1998. Receptor and nonreceptor-mediated organ-specific toxicity of di (2-ethylhexyl) phthalate (DEHP) in peroxisome proliferator-activated receptor α -null mice. *Toxicologic Pathology*, 26, 240-246.
- Wilson, V. S., Lambright, C., Furr, J., Ostby, J., Wood, C., Held, G. & Gray Jr, L. E. 2004. Phthalate ester-induced gubernacular lesions are associated with reduced insl3 gene expression in the fetal rat testis. *Toxicology Letters*, 146, 207-215.
- Wittassek, M., Koch, H. M., Angerer, J. & Brüning, T. 2011. Assessing exposure to phthalates—the human biomonitoring approach. *Molecular Nutrition & Food Research*, 55, 7-31.
- Yin, L., Yan, L., He, B., Fang, Y., Liu, X., Duan, C., Yu, H., Peng, K., Wang, Q. & Cheng, J. 2016. The toxic effects of a plasticizer, dibutyl phthalate, on rat testis. *International Journal of Clinical and Experimental Pathology*, 9, 11246-11253.

Zhou, D., Wang, H., Zhang, J., Gao, X., Zhao, W. & Zheng, Y. 2010. Di-n-butyl phthalate (DBP) exposure induces oxidative damage in testes of adult rats. *Systems Biology in Reproductive Medicine*, 56, 413-419.

Zakariah, M., Ibrahim, M. I., Molele, R. A. & McGaw, L. J. 2020. Apoptosis of germ cells in the normal testis of the Japanese quail (*Coturnix coturnix japonica*). *Tissue and Cell*, 67, 1-7. <https://doi.org/10.1016/j.tice.2020.101450>