

Research Article

A DESCRIPTION OF IRON AGE SKELETONS FROM THE PILANESBERG NATIONAL PARK, SOUTH AFRICA

ERICKA N. L'ABBÉ¹, FRANCOIS P. COETZEE² & MARIUS LOOTS¹

¹*Department of Anatomy, Faculty of Health Sciences, University of Pretoria, P.O. Box 2034, Pretoria, 0001, South Africa*
E-mail: l'abbe@med.up.ac.za; mloots@medic.up.ac.za

²*Department of Archaeology and Anthropology, UNISA, South Africa*
coetzfp@unisa.ac.za

(Received September 2006. Revised March 2007)

ABSTRACT

Thirteen skeletons were excavated in the Pilanesberg National Park and represent a relatively large collection of Iron Age remains from a single location. The aim of this paper is to describe these remains by examining age at death, disease and trauma. Standard anthropological techniques were used and bone infections, dental caries, antemortem tooth loss, periapical abscesses, periodontal disease and enamel hypoplasia were macroscopically assessed. Six skeletons were male, three female, and four of unknown sex. Estimated age ranged from three juveniles (<14 years), five young adults (18 to 30 years), and five middle to older aged adults (+30 years). A case of osteomyelitis, one healed fracture, a humeral deformation, two cases of dental mutilation, and two people with bipartite patellae were observed. Dental diseases included dental caries, antemortem tooth loss, and enamel hypoplasia. Periapical abscesses were noted on three people and periodontal disease on two. Dental ailments were minimal and age-related diseases, such as antemortem tooth loss and periapical abscesses, were noted only in older individuals.

Keywords: bioarchaeology, Pilanesberg, South Africa, Late Iron Age, health, bipartite patella.

INTRODUCTION

Since 1995, an ongoing archaeological survey has been conducted in the Pilanesberg National Park with the aim to locate and document archaeological sites within a temporal and spatial framework. While focused on Late Iron Age settlements and features, this work has also uncovered thirteen human burials of which seven were subjected to radiocarbon dating and fall clearly within the Late Iron Age period (Table 1). Few skeletons excavated in South Africa date to this time. From published research papers, at least 64 individuals from the Late Iron Age were excavated in the last century and range in period of death from AD 1300 and AD 1820/1830 (Morris 1992a; Steyn 2003). The purpose of this paper is to describe the thirteen Late Iron Age skeletons from the Pilanesberg National Park with regard to their pattern of burial, age and sex distribution as well as evidence for disease and trauma.

In this discussion it is first necessary briefly to contextualize the human remains within both a temporal and spatial framework. The Pilanesberg region is best defined as an inactive volcanic caldera, which dates to approximately 1250 mya. The Pilanesberg Complex is the largest circular alkaline complex in South Africa. These alkaline rocks are rich in sodium and potassium (i.e. foyaites and syenites) and form the dominant suite of minerals in the area. In contrast, the surrounding Bushveld Complex is predominantly acidic and contains a high percentage of silica (quartz and mica, i.e. granite, felsite and gabbros) (Lurie 1974; Viljoen & Reimold 1999). Today, the area is an eroded circular volcanic intrusion, which results in a mountainous

region standing in stark contrast to the surrounding open plains of the Bankenveld. Since the Early Stone Age, people have utilized this unique topography for habitation.

Unbeknownst to the early inhabitants of Pilanesberg, the area harbours various toxic and potentially lethal contaminants. The green foyaites, endemic to Pilanesberg, carries a rich seam of rare earths and radioactive compounds such as uranium and thorium, which in turn produce toxic radon gases. Furthermore, the occurrence of fluorspar deposits results in very high fluoride level in surface water. As 1.2 parts per million (ppm) is the acceptable limit for human consumption, samples from both boreholes and spring water on the periphery of the park yielded toxic readings as high as 100 ppm (Lurie 1974; McCaffrey 1993: 50). The latent effects of these contaminants on the quality of life of the people within the region have never been fully investigated.

In a regional analysis of skeletal remains, Steyn (2003: 280) lists various burials within the temporal framework of the Late Iron Age between AD 1300 and AD 1830s. To facilitate comparison between these remains and those from Pilanesberg this broad framework is retained. However, a more tiered approach to this temporal unit is suggested by Hall (1998: 238–244; see also Boeyens 2003), which might be more appropriate here.

The first phase of the Late Iron Age, referred to as the Early Moloko, is marked by a clear break from the earlier Eiland facies and dates between AD 1300/1400 and early AD 1600, south of the Limpopo River. Early Moloko settlements are not demarcated with stone walls and are characterized as small, with maximum dimensions of about 100 square metres, and comprise loose circles of huts arranged around a central cattle enclosure (Hall 1998: 238). Several sites including Olifantspoort (29/72), Rooiberg (Mason 1986), Icon (Hanisch 1979) and Rietfontein (Boeyens 2003) indicate that Early Moloko settlements are situated near raised areas at the base of mountains, close to water and arable land, and usually near, or on, fertile flood plains.

Eleven of the burials (UP 147–UP 155) from Pilanesberg are associated with this period. Nine were discovered at site 2527AA121 (Malatse Dam) which is situated in the northeastern section (on the farm Vaalboschlaagte 55JQ) of the Pilanesberg National Park. Severe sheet erosion led to the exposure of surface scatters of potsherds, several stone platforms, house floors and burials. Owing to erosive activities, many of the skeletons from this area are incomplete with parts of the skeletal remains recovered in secondary deposits in the erosion donga. Preliminary pottery analysis indicated clear affinities with Icon, Olifantspoort and Madikwe facies ceramics (Hanisch 1979; Mason 1986; Huffman 2000, 2002). Radiocarbon dates were obtained from two of the skeletons, namely UP 147

TABLE 1. Location and radiocarbon dates of skeletal remains in the Pilanesberg National Park.*

UP No.	Site	Age (BP)	Calibrated dates	Lab No.
UP 51	2527AC56	890 ± 50	AD1202 (Sigma 1: AD1162–AD1248)	Pta 7331
UP 95	2527AC4 Grave 1 (TT1)	160 ± 40	AD1692, AD1726, AD1814, AD1933, AD1954	Pta 8029
UP 139	2527AA93	460 ± 50	AD1451 (Sigma 1: AD1433–AD1487)	Pta 8659
UP 143	2527AC4 Grave 3 (TT3)	300 ± 35	AD 1649 (Sigma 1: AD1638–AD1660)	Pta 8944
UP 147	2527AA121	620 ± 40	AD 1400 (Sigma 1: AD1312–AD1358, AD1385–AD1412)	Pta 9304
UP 150	2527AA121	60 ± 40	AD1955	Pta 9458
UP 152	2527AA121	670 ± 50	AD1308, AD1367, AD1379 (Sigma 1: AD1293, AD1400)	Pta 9475

*Information obtained from unpublished field reports.

and UP 152, and yielded calibrated dates of AD 1400 (Pta 9304) and a midpoint of AD 1300 (Pta 9475) respectively, confirming an Early Moloko occupation.

The tenth skeleton is UP 51 and was recorded in the southern regions of Pilanesberg on the farm Houwater 54JQ. The burial had been of a pregnant female buried in an aardvark hole. It was discovered in the erosion profile of a dry riverbed. No artefacts, features, or structures were found in association with this person. The skeleton yielded a calibrated date of AD 1202 (Pta 7331).

The eleventh skeleton (UP 139), also radiocarbon dated to this period, was excavated as an isolated find near the Bakgatla Camp (see Nienaber and Steyn, unpublished field notes). The remains yielded a calibrated date of AD 1451 (Pta 8659). No Iron Age artefacts, features, or structures could be associated with this individual. Apart from coiled copper bangles found around the ankles, no grave goods were recorded.

The early to mid-17th century marks the second phase of the Late Iron Age. Although the sites are small in size, a distinct characteristic of this period is the appearance of low stone walls used to define social and functional spaces within the homestead (Maggs 1976; Taylor 1984; Hall 1998: 242). The stone-walled site 2527AC4 (Motlobo), which falls within this period, is located on an isolated spur and is approximately 200 metres by 60 metres in extent. The settlement layout is dominated by seven linearly arranged large cattle enclosures. Excavations revealed several storage pits of which only two were excavated. Both of these pits had been sealed off with flat stone cairns and both yielded human remains. No grave goods were recovered with the burials (see also Morris 1992a: 66–67).

UP 143 provided a calibrated AD 1649 date (Pta 8944), which is clearly within the second phase of the Late Iron Age, whereas the date for UP 95 fluctuates between AD 1692 and AD 1954 (sigma 1) (Pta 8029) and may indicate a more recent interment, possibly AD 1814.

MATERIALS AND METHODS

All thirteen skeletons were assigned a site number and are housed at the Department of Anatomy, University of Pretoria.

Standard anthropological techniques, both morphologic and metric, were used to determine sex, stature, and to estimate age from the remains (Krogman & İşcan 1986; Buikstra & Ubelaker 1994). With regard to osteometric analyses, South African standards were employed (e.g. Steyn & İşcan 1999). Stature was estimated using linear regression formulae developed using the long bones of modern South African Bantu-language speakers (Lundy & Feldesman 1987). Methods used to determine sex from adult skeletons included morphological indicators from the skull, mandible, and pelvis, as well as a metric indicator from the humerus, femur, and tibia (Ferembach *et al.* 1980; Loth & İşcan 2000). The combinations of these techniques have been shown to be more reliable than any

one of the traits, alone (e.g. Krogman & İşcan 1986). Sex was not determined for juvenile remains.

Owing to environmental, social, and cultural factors, the task of estimating age from the skeleton can be difficult (e.g. İşcan 1989; Loth & İşcan 1994). In order to improve accuracy, multiple techniques for estimating age were used and included the cranial sutures, dental wear, sternal end of the 4th rib, and the pubic symphysis (Krogman & İşcan 1986; Oettlé & Steyn 2000). Age estimation from juvenile remains was based on both primary and secondary ossification centres and dental eruption (Scheuer & Black 2000).

All bones were macroscopically examined for non-specific (sub-periosteal lesions and cribra orbitalia) and specific indicators of infectious disease and trauma (Ortner & Putschar 1981; Aufderheide & Rodriguez-Martin 1998). Dental diseases were assessed and included dental caries, antemortem tooth loss, periapical abscesses and enamel hypoplasia. To record dental caries, the methodology proposed by Lukacs (1989) was used. If a carious lesion was present, the following observations were recorded: the location in the mouth (maxilla or mandible); the specific tooth (incisor, canine, premolar or molar); the specific area on the tooth (mesial, distal, buccal, lingual, occlusal, or tooth root); and the approximate size of the lesion. With regard to antemortem tooth loss, the alveolar bone had to be partially or completely resorbed. A periapical abscess was scored as either present or absent in the alveolar bone. Linear enamel hypoplasia (LEH) was macroscopically identified as lines, pits, or grooves on the enamel surface of the tooth (Hillson 1996). In order to provide estimates for the developmental period in which enamel hypoplastic insults may have occurred, measurements were taken with a sliding caliper (0.1 mm) from the midpoint of the cemento-enamel junction (CEJ) to the most occlusal point of the defect; regression equations from Goodman and Rose (1990) were used to calculate the approximate age of occurrence. In order to compare results of dental ailments with other skeletal samples, all dental diseases were calculated for frequency and intensity.

RESULTS

An inventory of the skeletal elements recovered and a description of their preservation are provided in the following paragraphs. Skeletons not associated with site 2527AA121 (PIL 121) included UP 51, UP 95, UP 139, and UP 143. As a whole, the preservation of skeletal elements and the completeness of the remains was excellent for those individuals dating from the latter half of the Iron Age. Due to the fact that skeletal remains from site 2527AA121 (PIL 121) were discovered partially (or completely) eroded from various dongas, bone recovery was not as good and few of the skeletal elements were complete; however, preservation of the recovered material was satisfactory.

UP 51 was the first to be excavated in 1997 and bone preser-

vation was good to excellent. While the skull was fragmented, the jaw (maxilla and mandible) and teeth were present and complete. The clavicles and scapulae were fragmented, while the upper limbs and vertebral column were mostly complete, with *post-mortem* damage noted only on the left humerus, radius, and ulna as well as a missing lumbar vertebra. For the hands, two right carpals (capitate and hamate), one left carpal (hamate), four right metacarpals (1, 3, 4, and 5) and five left metacarpals (1 to 5) were recovered. The pelvis and lower limbs were broken and incomplete, with only a complete right femur, right patella, left calcaneus, right talus, right cuboid, and a right lateral cuneiform having been retrieved. Foetal remains were found associated with the remains, but these bones were sent to UCT for isotope testing in 1997.

Preservation and completeness of the skeletal material UP 95 was excellent. All the bones were represented, except for eight ribs (right: 10–12 and left: 3, 5, 6, 11 and 12), which were sent for radiocarbon dating. Likewise, UP 143 (which had been recovered adjacent to UP 95) had exceptional bone preservation and bone recovery. All the skeletal elements were present for UP 143, excluding the left ribs (8–12), which were sent for radiocarbon dating. Both skeletons were recovered from circular, grain storage pits.

For UP 139, twenty-six fragments of the skull along with portions of the maxilla, clavicles, scapulae, and vertebrae were recovered. The upper limb and hands were complete, with only the proximal ends of the humeri and right ulna missing; likewise, the lower limb and feet were intact, except for the proximal end of the right tibia.

UP 147 was represented by approximately 250 bone fragments, of which two teeth and several hand bones were of probable human origin. The bones of the hand comprised three right carpals (scaphoid, capitate, and trapezium), four phalanges, and three metacarpals (right: MC 1 and 3).

UP 148 was discovered eroding from the wall of a small donga, approximately 21 cm below the surface of the site. Bone recovery was poor, with most of the skeletal elements being fragmented. No skull or mandible was present; fragments of the left humerus, proximal end of the left ulna and radius, three carpals (both scaphoids and the left hamate), 22 pieces of the os coxae, midshafts of the tibiae and fibulae, 11 tarsals (6 right (missing the right calcaneus) and 7 left), and 9 foot phalanges were retrieved. In the same donga, UP 149 was recovered at a depth of 6 cm; similar to UP 148, bone recovery was poor. The cranium (skull and mandible) was not present. Portions of the long bones were retrieved and included the distal right humerus, proximal right ulna, and the proximal and midshaft of the femur. Both iliac blades, 5 vertebral bodies (including S1), the right talus and calcaneus, 10 metatarsals (right and left), and 9 phalanges were also found.

UP 150 was uncovered at least 6 cm below the surface, and bone recovery was extremely poor. Pieces of the cranium (skull and mandible) were found along with fragments of the ribs, vertebrae, proximal and distal portion of the right humerus, midshaft of the left humerus, midshaft of the radii and ulnae, 22 pieces of the os coxae, the right femur, and midshaft pieces of the left femur and both tibiae. Three fragmented phalanges from the hand, the right calcaneus, right talus, four metatarsals and 17 phalanges from the foot were also found. Carnivore activity was observed on the right humerus and indicates exposure of these remains.

Most of the skeletal elements of UP 151 were found on the surface of a donga; only 17 cranial pieces, portions of the maxilla and mandible (including the right ramus), fragments of both clavicles and scapulae, the head and midshaft of the right

humerus, four phalanges, fragments of the vertebral column, the head and distal portion of the left femur, the distal right femur, the right proximal tibia and the right talus were recovered.

The condition of the skeleton of UP 152 was poor; all the remains were fragmented and included 60 cranial pieces (including the maxilla and mandible), clavicles, scapulae, the midshaft and distal ends of both humeri, the midshaft and proximal ends of both radii and ulnae, three left carpals (capitate, scaphoid, lunate), ribs, vertebrae, patellae, the proximal and midshafts of the femora, fragmented pieces of the tibiae, and pieces of the tarsals, metatarsals, and phalanges (foot).

For UP 153, fragments of the cranium (including the right temporal bone as well as the right maxilla and mandible) were recovered along with the midshaft and distal ends of the humerus, pieces of the right ulna, an almost complete left ulna, radii, femora, tibiae, ribs and vertebra. Five carpals, 3 metacarpals and 13 phalanges (hand), 3 tarsals, 5 metatarsals and 7 phalanges (foot) were also present. A left upper first and second molar, in which the tooth roots were open, suggesting an individual younger than 12 years, represented UP 154. UP 155 was in a poor condition, while many of the recovered skeletal elements exhibited *post-mortem* damage. Fragments from the cranium included 5 pieces of the right and left orbit and approximately 80 pieces from the frontal, parietal, temporal, and occipital bones. The maxilla and mandible were also broken, but all the teeth were recovered. For the postcranial remains, four clavicle fragments, approximately 50 rib fragments, two pieces of C1, the vertebral body of C2, three cervical vertebrae (the position of these vertebrae could not be determined), 19 fragments from the vertebral column, pieces of scapulae (left: acromion process and glenoid fossa; right: 5 fragments), midshafts of the humeri, radii, ulnae, femora, tibiae and fibulae along with 20 fragments from the hands (metacarpals and phalanges). None of the foot bones were retrieved.

Burial position was determined for all the skeletons except UP 147 and UP 154. As shown in Table 2, eight people had been buried in a horizontal, tightly flexed position, whereas two had been positioned upright. From the early Moloko site, adults had been laid on their right side whereas juveniles had been placed on their left. Both horizontal and upright burial positions are typical of the late Iron Age.

Of the thirteen individuals, six were male, three female, and four of unknown sex. Of these, three were juveniles (UP 149, UP 155, UP 154), five were young adults (UP 51, UP 95, UP 139, UP 150, UP 151), and three were middle to older aged adults (UP 143, UP 152, UP 153). Owing to poor recovery of skeletal remains, the remaining two individuals (UP 147 and UP 148) could only be classified as adults. The majority of people (66%) had died before 40 years of age, which is reflected in the mean age at death of approximately 27.5 years. It can be tentatively suggested that males were slightly taller than females, but due to a small sample size, no definite conclusions can be made.

Pathological bone lesions were rare in this sample. Evidence of a healed fracture with an associated osteomyelitic infection was observed on the left tibia of an adult male (UP 148). Numerous cloacae were visible around the site of injury and are characteristic of a localized infection (Fig. 1); another trauma-related injury included one male with a possible Colles' fracture of the right radius (UP 143). Cultural alterations, associated more with purposeful mutilation than trauma, included two females whose upper incisors had been intentionally filed (UP 51 and UP 150). In both cases, the teeth had been modified into a V-shape (Fig. 2).

TABLE 2. Summary of burial position and demographic profile of skeletal remains from the Pilanesberg National Park.

UP No.	Pil Site	Burial style	Side	Head	Orientation	Sex	Age (years)	Estimated stature
UP 51	2527AC56					Female		150.1 cm ± 2.789
UP 95	2527AC4 Grave 1 (TT1)	Vertical; tightly flexed	–	–	–	Female	20–30	161.4 cm ± 2.497
UP 139	2527AA93	Horizontal; tightly flexed	Left	South	N–NE	Male	18–22	176.5 cm ± 2.371
UP 143	2527AC4 Grave 3 (TT3)	Vertical; tightly flexed	–	–	–	Male	30–40	166.5 cm ± 2.371
UP 147	2527AA121	Unknown	–	–	–	Unknown	Adult	*
UP 148	2527AA121	Horizontal; tightly flexed	Right	East	N–S	Male	Adult	*
UP 149	2527AA121	Horizontal; tightly flexed	Left	?East	?N–S	Unknown	8–12	*
UP 150	2527AA121	Horizontal; tightly flexed	Right	North	E–W	Female	20–30	*
UP 151	2527AA121	Horizontal; tightly flexed	Right	North	E–W	Male	18–25	*
UP 152	2527AA121	Horizontal; tightly flexed	Right	East	N–S	Male	+50	*
UP 153	2527AA121	Horizontal; tightly flexed	Right	East	N–S	Male	40–60	*
UP 154	2527AA121	Unknown	–	–	–	Unknown	10–14	*
UP 155	2527AA121	Horizontal; tightly flexed	Left	North	E–W	Unknown	5–9	*

*Could not be determined due to the poor preservation of the remains.




FIG. 1. Healed fracture with an osteomyelitic infection (cloacae: see arrows) (adult male: UP 148). Scale in centimetres.

A deformity, which could not be associated with a healed fracture, was observed on the distal end of the right humerus of UP 51. As can be seen in Fig. 3, approximately one-third from the distal end of the bone, it can be observed that the bone rises anteriorly and appears to twist medially, which caused a bony

protrusion on the anterior surface. The articular surface is also rotated medially. It is possible that this would have affected the carrying angle of the arm. Possible reasons for this deformity are not clear, but it may be due to premature closure of the distal epiphyseal growth plate. Another interesting find was

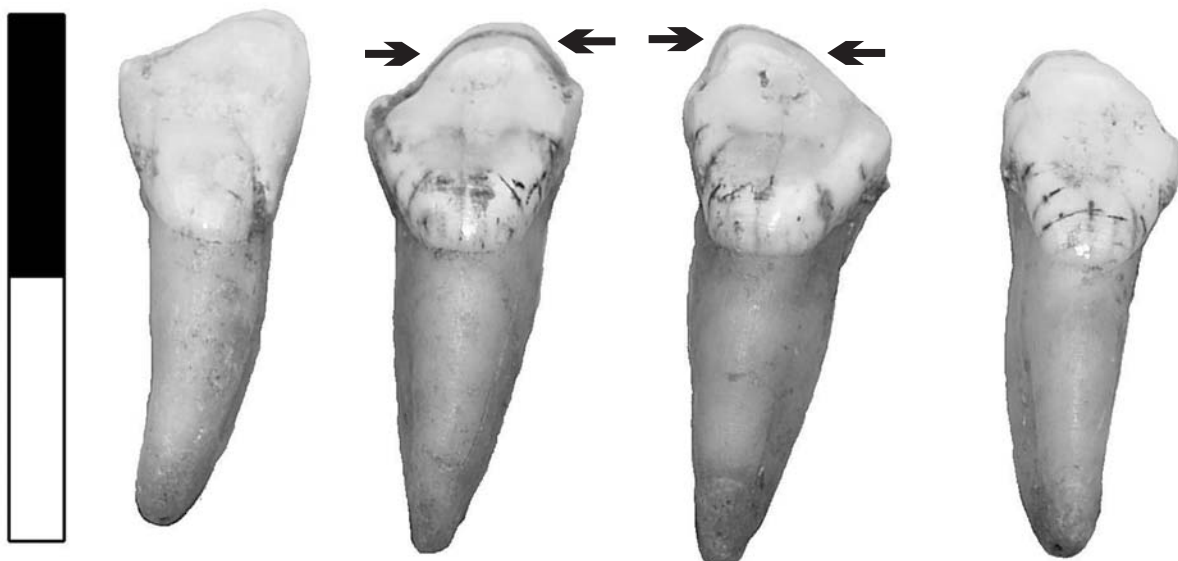


FIG. 2. Upper incisors of UP 51, central incisors have been modified into a V-shape (see arrows). Scale in centimetres.



FIG. 3. Deformation of the right distal humerus of UP 51 (see arrow). Scale in centimetres.



FIG. 4. Bilateral bipartition of the patellae of UP 95 (see arrows). Scale in centimetres.

bipartition of the patellae of both UP 95 and UP 143 (Figs 4 & 5). Because the condition is bilateral on both skeletons, it is more likely to have been a developmental anomaly than a traumatic condition, such as lateral avulsion of the patella.

Dental disease was uncommon among these individuals. The number of individuals affected by dental caries was 33% ($n = 3$ affected; $n = 9$), whereas caries intensity was 1.4%

(number of teeth affected: 3, number of teeth in the sample: 210). These results imply that few people had carious lesions in their mouths and of those who did only one or two teeth were affected. The number of persons affected by antemortem tooth loss (AMTL) was 22% ($n = 2$ affected, $n = 9$) and AMTL intensity of 1.4% (number of teeth lost antemortem: 3, number of tooth sockets present in the sample: 215). Heavy dental wear and



FIG. 5. Bilateral bipartition of the patellae of UP 143 (see arrows). Scale in centimetres.

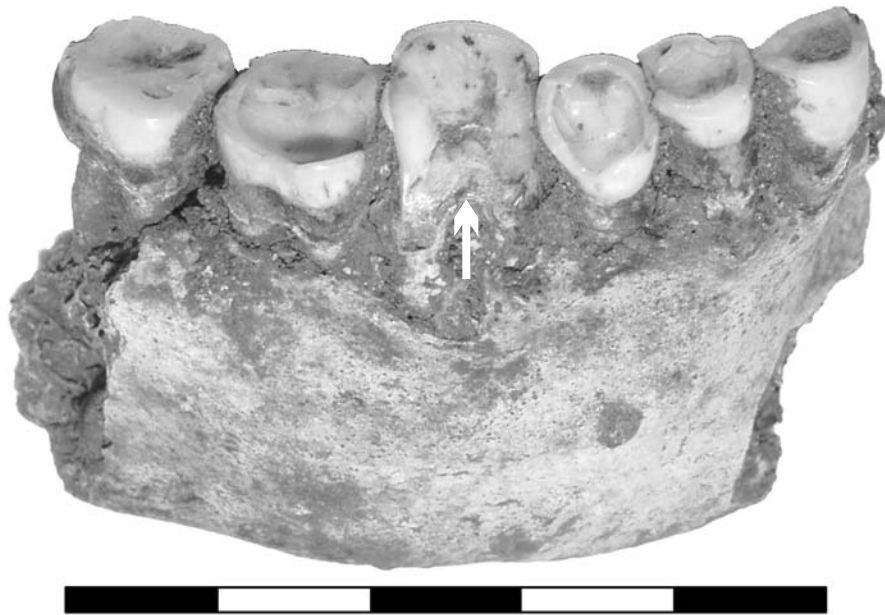

FIG. 6. Posterior part of the right mandible of UP 152: note the exposure of the root and helicoidal wear on the first molar (see arrows). Scale in centimetres.

antemortem tooth loss was recorded only in adults over 40 years of age (UP 152 and UP 153). The oldest individual (UP 152) had heavy dental wear, visible periodontal disease, and five periapical abscesses at the tooth roots of the upper first and third molar, the lower right second incisor and first molar, and the lower left first premolar. Healed abscesses were present at the root of the lower left second molar and first molar. The combination of these dental problems and possible malalignment of the upper and lower jaw was most likely responsible for both helicoidal wear and exposure of the root pulp on the lower right first molar (Fig. 6). Periapical abscesses were also noted on the lower right second premolar of UP 151 and the lower left first premolar of UP 153.

The frequency of linear and pitted enamel hypoplasia was 22% ($n = 2$ affected, $n = 9$) with an intensity of 5.2% (number of teeth with enamel hypoplasia: 11, number of teeth in the sample: 210). It is interesting to note that UP 51 and UP 151 had pitted enamel hypoplasia on identical teeth, the upper and lower premolars and second molars and can be seen in Figs 7 and 8. The pitting formed a circular band around each tooth such that they were visible from both the buccal and lingual surfaces. When measurements were taken, the hypoplastic lesions of UP 51 appear to have occurred between 5 and 6 years for the second molars (upper M2: 3.60 mm, lower M2: 3.90 mm) and 3 to 4 years for the second premolar (upper P2: 3.88);

whereas UP 151 had a slightly different pattern with an estimated age of occurrence between 4 to 5 years for M2 (lower left and right: 3.98 mm) and P2 (lower left: 3.86 mm, lower right: 4.01 mm).

DISCUSSION

Since the skeletal sample was small, it is difficult to provide a broad interpretation of longevity, disease and trauma for these people. Therefore, this discussion is focused primarily on describing what was collectively found in the Pilanesberg, with general comparisons to other Iron Age groups in South Africa.

From the distribution of ages (Table 2), it was observed that three juveniles died during young adolescence with most of the other people dying during young adulthood (or their third decade of life). Although interpretations from these results should be approached with caution, the relatively large number of dead adolescents and young adults might reflect a group that was perhaps dying from acute infectious diseases. This is not an unrealistic assumption considering that death from acute infections was a common problem for 20th century South Africans who live in rural areas with no access to modern amenities or medical care (Van Tonder & Van Eeden 1975). Evidence for bacterial and parasitic infections in early and late Iron Age inhabitants have been recorded from a single coprolite at Mapungubwe/K2 (1000 AD to 1300 AD) (*Trichuris*



FIG. 7. Pitted enamel hypoplasia on the upper second premolar and second molar of UP 51 (see arrows). Scale in centimetres.

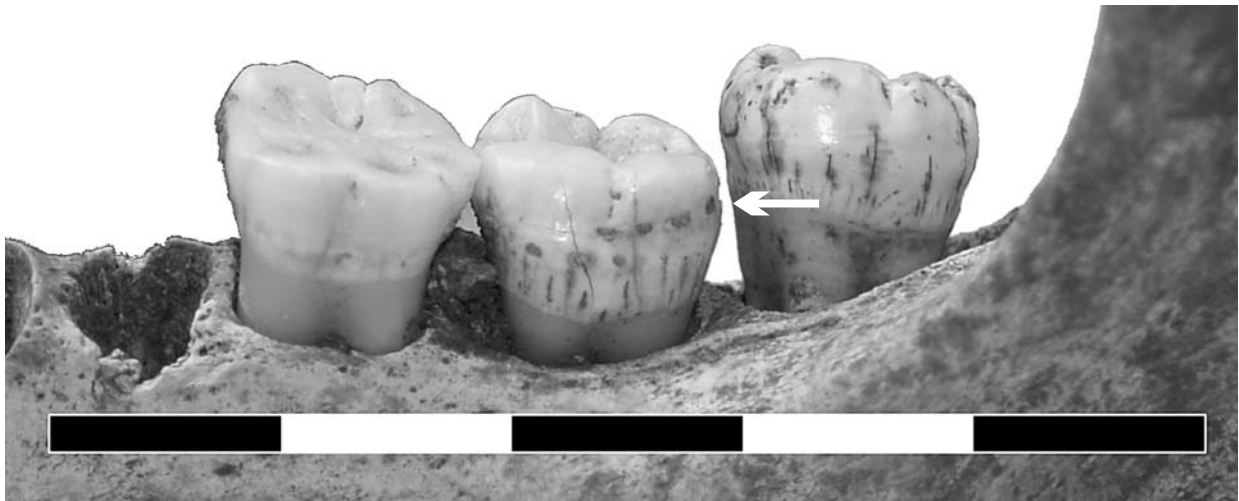

FIG. 8. Pitted enamel hypoplasia on the second molar of UP 151 (see arrow). Scale in centimetres.

trichiura or whipworm) and from the drinking water of the modern, rural Venda (1900 AD) (bilharzia) (Dittmar & Steyn 2004; L'Abbé 2005).

Chronic diseases were not common in this sample, nor has it been prolifically observed in surrounding villages during the Iron Age. A single case of secondary osteomyelitis was recorded in this study, which had most likely been associated with a compound fracture of the tibia. Evidence for osteomyelitic infections prior to AD 1900 is rare in southern Africa, with only two other cases known. These include an adult male from Schroda (AD 815–900) and a 17th century Dutch soldier in the Western Cape Province (Hanisch 1980; Abrahams-Willis & Fourshé 1995). Other types of diseases found at Sotho-Tswana sites in the geographic vicinity of Pilanesberg include tuberculosis and treponemal (nonvenereal) disease (Pistorius & Steyn 1995; Pistorius *et al.* 1998).

Among the Pilanesberg skeletal remains, enamel hypoplastic lesions were much lower (22%) than other South African archaeological samples such as K2/Mapungubwe (63.3%), the prehistoric site of Oakhurst (47%), and the historic mine labourers at Koffiefontein (61.1%) (Patrick 1989; Steyn 1994; L'Abbé *et al.* 2003). The estimated stature of two of the adults was comparable to both the Iron Age sample from K2 (males (6): 163.6, S.D. = 6.04; females (3): 153) and to a sample of 20th century Venda-speakers (males (23): 166.9, S.D. = 7.19; females (28): 157.8, S.D. = 5.9) (Steyn 1994; L'Abbé & Steyn 2007). The remaining two individuals (UP 139 and UP 51) were either slightly taller or shorter than these comparative groups. According to Steyn and Smith (2007), the average stature for modern Bantu-speaking South Africans is 171 cm for males and 159 cm for females. Unfortunately, due to the small sample size, few conclusions can be drawn from the Pilanesberg evidence and far more skeletons are needed.

Heavy dental wear, periodontal disease and periapical abscesses were only observed in two adult males both of whom were over 40 years of age. Similar dental problems have been noted in three older adults from the late Iron Age sites of Makgope and Malle (Pistorius *et al.* 1998; Pistorius *et al.* 2002). Possible reasons for heavy dental wear and periapical abscesses in these communities include abrasive substances in the diet, consumption of a large quantity of tough or raw foods, and/or the use of teeth as tools (Hillson 1996).

Faunal remains have shown that early farmer inhabitants of the Pilanesberg area are considered to have consumed both wild and domesticated foodstuffs and thus fall within a mixed economy (Beukes 1999; see also Turner 1979). In such a food

economy, the number of teeth affected by caries can range from 0.4 to 10.3%, with an average of 4.8% (Lukacs 1989). The Pilanesberg group is clearly at the lower end of this range with a caries intensity of 1.4%; in fact, they compare best with hunter and gatherer groups such as Riet River (4.3%) and Kakamas (1.3%), rather than traditional agricultural groups such as Venda-speakers (7.8%) and Maroelabult (4.5%) (Morris 1992b; Steyn 1994; Steyn *et al.* 2002; L'Abbé 2005). The differences between the Pilanesberg group and traditional agricultural groups may be associated with differences in diet (or a more coarse diet) and/or high fluoride concentrations in their drinking water.

Fluoride readings in the park have been recorded at 2–7 ppm near the interior and 47 ppm to 80 ppm at the periphery (McCaffrey 1993), and were found in both borehole and spring water. The presence of fluoride has been shown to reduce cariogenic activity in both children and adults by strengthening the dental enamel and thus enhancing its resistance to decay e.g. (Sealy *et al.* 1992; Van Loveren & Duggal 2001). In adults, additional fluoride may provide resistance to dental caries, since the dental enamel can absorb fluorine from both saliva and food (Hillson 1996). Yet, the optimal concentration of fluoride in drinking water should be between 0.07 ppm and 1.2 ppm (Silverstone *et al.* 1981). If juveniles ingest a higher concentration of fluoride than necessary, it may lead to dark brown staining of the teeth, destruction of tooth enamel, and an increase in the incidence of dental caries (e.g. Carstens *et al.* 1995; Hillson 1996; Grobler *et al.* 2001). From the skeletal remains, there is no visible evidence in either adults or juveniles that greater than normal quantities of fluoride were ingested through normal drinking water. Considering the rather toxic levels of fluoride found within the Pilanesberg area, these results are unusual and may be attributed to a small sample size or possibly that the adults were recent migrants into the Pilanesberg area and thus had not been affected by high fluoride concentrations as children. Since very few juvenile teeth were recovered, it is not possible to discuss the effects that the high fluoride concentrations may have had on them.

Trauma-related injuries were minimal in the sample and included only a probable accidental injury (Colle's fracture) on one person. While traumatic, but not always associated with trauma, is the intentional filing of the upper incisor teeth of the two female individuals. In southern Africa, dental mutilation has been shown to occur in both sexes and is often performed as a means of cultural identification (Morris 1989). For the people from Pilanesberg, there is currently no evidence to

suggest that the practice of dental mutilation was done for any reason other than cultural or group identification. Similar styles of mutilated teeth have been observed at various contemporary sites around Pilanesberg, and include a female from Ben Alberts Nature Reserve, a male from Modimolle, two females from Farm Laaste and one male from Phalaborwa (Steyn 2003).

Bipartite patellae are considered to be a rare find in archaeological skeletal samples (Anderson 2002). Two examples of bipartition of the patella were noted in this study, and thus the aetiology of this congenital condition are worthy of mention. Bipartition of the patella is a normal anatomical variation in which one or many accessory bone ossicles make up the supero-lateral border of the bone (Williams 1980; Mann & Murphy 1990; Anderson 2002). These accessory centres may or may not fuse with the primary bone. If fusion does not occur, then a notch is observed on the lateral side of the patella (Mann & Murphy 1990). Since this is a congenital phenomenon, it may tentatively suggest a familial relationship between these two people (UP 95, UP 143) who had been excavated from the same cattle corral.

CONCLUSION

In summary, this group of skeletons contribute to the overall collection of material evidence that we have on the Iron Age period in southern Africa. However, further research is needed to explore the effect toxic levels of fluoride and uranium may have had on these people. As always, more skeletons are necessary to establish more concrete conclusions and to create additional questions.

ACKNOWLEDGEMENTS

E.N.L. would like to thank the Department of Anatomy, University of Pretoria and the NRF for financial assistance. Many thanks and appreciation to colleagues and students who have worked on these excavations over the years. E.P.C. thanks Jan Boeyens for comments on the paper, and colleagues and students of UNISA as well as the UNISA general domestic research fund and the Friends of Pilanesberg for financial contributions.

REFERENCES

- Abrahams-Willis, G. & Fourshé, K. 1995. Burial from the seventeenth century Dutch Fort de Goede Hoop at the Cape. *Southern African Field Archaeology* 4: 95–102.
- Anderson, T. 2002. A bipartite patella in a juvenile from a Medieval context. *International Journal of Osteoarchaeology* 12: 297–302.
- Asala, S.A. 2001. Sex determination from the head of the femur of South African whites and blacks. *Forensic Science International* 117: 15–22.
- Aufderheide, A.C. & Rodriguez-Martin, C. 1998. *The Cambridge Encyclopedia of Human Paleopathology*. Cambridge: Cambridge University Press.
- Beukes, D. 1999. *Report on the Faunal Analysis of Site 2527AC33, Pilanesberg National Park*. Unpublished Report. Pretoria: Transvaal Museum
- Boeyens, J.C.A. 2003. The Late Iron Age sequence in the Marico and early Tswana history. *South African Archaeological Bulletin* 58: 63–78.
- Buikstra, J.E. & Ubelaker, D.H. 1994. *Standards: For data collection from human skeletal remains*. Fayetteville: Arkansas Archaeological Survey Research Series No. 44.
- Carstens, I.L., Louw, A.J. & Kruger, E. 1995. Dental status of rural school children in sub-optimal fluoride area. *Journal of the Dental Association of South Africa* 50: 405–411.
- Dittmar, K. & Steyn, M. 2004. Paleoparasitological analysis of coprolites from K2, an Iron Age archaeological site in South Africa: the first finding of *Dicrocoelium* sp. eggs. *Journal of Parasitology* 90: 171–173.
- Ferembach, D., Schwidetzky, I. & Stloukal, M. 1980. Recommendations for age and sex diagnoses of skeletons. *Journal of Human Evolution* 9: 517–549.
- Goodman, A. & Rose, J. 1990. Assessment of systemic physiological perturbations from dental enamel hypoplasias and associated histological structures. *Yearbook of Physical Anthropology* 33: 59–110.
- Grobler, S.R., Louw, A.J. & Van Kotze, T.J. 2001. Dental fluorosis and caries experience in relation to three different drinking water fluoride levels in South Africa. *International Journal of Paediatric Dentistry* 11: 372–379.
- Hall, S. 1998. A consideration of gender relations in the Late Iron Age 'Sotho' sequence of the western Highveld, South Africa. In: Kent, S (ed.) *Gender in African Prehistory*: 238–244. London: Altamira Press.
- Hanisch, E.O.M. 1979. Excavations at Icon, Northern Transvaal. *South African Archaeological Bulletin: Goodwin Series* 3: 72–79.
- Hanisch, E.O.M. 1980. An archaeological interpretation of certain Iron Age sites in the Limpopo/Shashi Valley. Unpublished MA thesis. Pretoria: University of Pretoria.
- Huffman, T.N. 2000. Madikwe Reserve, Archaeological Survey of the North West Province. Unpublished report. Johannesburg: Archaeological Resources Management, University of the Witwatersrand.
- Huffman, T.N. 2002. Regionality in the Iron Age: the case of the Sotho-Tswana. *Southern African Humanities* 14: 1–22.
- Hillson, S. 1996. *Dental Anthropology*. Cambridge: Cambridge University Press.
- İşcan, M.Y. 1989. Research strategies in age estimation: the multi-regional approach. In: İşcan, M.Y. (ed.) *Age markers in the Human Skeleton*: 325–329. Springfield: Charles C. Thomas.
- Krogman, W.M. & İşcan, M.Y. 1986. *The Human Skeleton in Forensic Medicine*. Springfield: Charles C. Thomas.
- L'Abbé, E.N. 2005. A palaeodemographic, palaeopathologic and morphologic study of the 20th century Venda. Unpublished PhD thesis. Pretoria: University of Pretoria.
- L'Abbé, E.N., Henderson, Z.L. & Loots, M. 2003. Uncovering a nineteenth-century typhoid epidemic at the Koffiefontein Mine, South Africa. *World Archaeology* 35: 306–318.
- L'Abbe, E.N. & Steyn, M. 2007. Health status of the Venda, a post-antibiotic community in rural South Africa. *International Journal of Osteoarchaeology* 17: 492–503.
- Loth, S.R. & İşcan, M.Y. 1994. Morphological indicators of skeletal aging: Implications for paleodemography and paleogerontology. In: Crews, D. & Garruto, R. (eds) *Biological Anthropology and Aging: Perspectives on Human Variation over the Life Span*: 394–425. New York: Oxford University Press.
- Loth, S.R. & İşcan, M.Y. 2000. Sex Determination. In: Siegal, J., Saukko, P. & Knupfer, G. (eds) *Encyclopedia of Forensic Sciences*: 252–260. London: Academic.
- Lukacs, J.R. 1989. Dental paleopathology: methods for reconstructing dietary patterns. In: İşcan, M.Y., Kennedy, K.A.R. (eds) *Reconstruction of Life from the Skeleton*: 261–286. New York: Wiley-Liss.
- Lundy, J. & Feldesman, M. 1987. Revised equations for estimating living stature from the long bones of the South African Negro. *South African Journal of Science* 83: 54–55.
- Lurie, J. 1974. The Pilanesberg: Geology, rare element geochemistry and economic potential. Unpublished PhD thesis. Grahamstown: Rhodes University.
- Mader, J.T. & Calhoun, J.H. 1989. Long bone osteomyelitis. An overview. *Journal of American Podiatry Medical Association* 79: 476–481.
- Maggs, T.M.O'C. 1976. *Iron Age Communities of the Southern Highveld*. Pietermaritzburg: Natal Museum.
- Mann, R.W. & Murphy, S.P. 1990. *Regional Atlas of Bone Disease: A Guide to Pathologic and Normal Variation in the Human Skeleton*. Springfield: Charles C. Thomas.
- Mason, R.J. 1986. *Origins of Black People of Johannesburg and the Southern Western Central Transvaal AD 350–1880*. Occasional Paper No. 16 of the Archaeological Research Unit. Johannesburg: University of the Witwatersrand.
- McCaffrey, L.P. 1993. The Geohydrology of Pilanesberg. Unpublished MA thesis. Johannesburg: University of the Witwatersrand.
- Morris, A.G. 1989. Dental mutilation in historic and prehistoric South Africa. *Quarterly Bulletin of the South African Library* 43: 132–134.
- Morris, A.G. 1992a. *A Master Catalogue: Holocene Human Skeletons from South Africa*. Witwatersrand University Press: Johannesburg.
- Morris, A.G. 1992b. *The Skeletons of Contact: a Study of Protohistoric Burials from the Lower Orange River Valley, South Africa*. Witwatersrand University Press: Johannesburg.

- Oetlé, A. & Steyn, M. 2000. Age estimation from sternal ends of ribs by phase analysis in South African blacks. *Journal of Forensic Science* 45: 1071–1079.
- Ortner, D.J. & Putschar, W.G.J. 1981. *Identification of Pathologic Conditions in Human Skeletal Remains*. Washington: Smithsonian Institution Press.
- Patrick, M.K. 1989. An archaeological, anthropological study of the human skeletal remains from the Oakhurst Rockshelter, George, Cape Province, southern Africa. Unpublished MA thesis. Cape Town: University of Cape Town.
- Pistorius, J.C.C., Steyn, M. & Nienaber, W.C. 1998. Two burials from Makgope – a Batswana settlement in the Bankenveld. *South African Journal of Ethnology* 21: 115–124.
- Pistorius, J.C.C. & Steyn, M. 1995. Iron working and burial practices amongst the Kgatla-Kwena of the Mabyananatshwaana complex. *Southern African Field Archaeology* 4: 68–77.
- Pistorius, J.C.C., Steyn, M. & Nienaber, W.C. 2002. Two burials at Malle, a late Iron Age settlement in the Bankenveld in the North-West province. *South African Archaeological Bulletin* 57: 55–63.
- Scheuer, L. & Black, S. 2000. *Developmental Juvenile Osteology*. London: Academic Press.
- Sealy, J.C., Patrick, M.K., Morris, A.G. & Alder, D. 1992. Diet and dental caries among later Stone Age Inhabitants of the Cape Province, South Africa. *American Journal of Physical Anthropology* 88: 123–134.
- Shandling, B. 1960. Acute haematogenous osteomyelitis: a review of 300 cases treated during 1952–1959. *South African Medical Journal* 34: 520–524.
- Silverstone, L.M., Johnson, N.W., Hardie, J.M. & Williams, R.A.D. 1981. *Dental Caries, Aetiology, Pathology and Prevention*. Hong Kong: Macmillan Press.
- Steyn, M. 1994. An assessment of the health status and physical characteristics of the prehistoric population from Mapungubwe. Unpublished PhD thesis. Johannesburg: University of the Witwatersrand.
- Steyn, M. 2003. A comparison between pre- and post-colonial health in the northern parts of South Africa, a preliminary study. *World Archaeology* 35: 276–288.
- Steyn, M. & İşcan, M.Y. 1999. Osteometric variation in the humerus: sexual dimorphism in South Africans. *Forensic Science International* 106: 77–85.
- Steyn, M., Nienaber, W.C., Meiring, J. H. 2002. An assessment of the health status and physical characteristics of an early 20th century community at Maroelabult in the North West Province, South Africa. *HOMO* 53(2): 131–145.
- Steyn, M. & Smith, J.R. 2007. Interpretation of antemortem stature estimates in South Africans. *Forensic Science International* 17(2-3): 97–102.
- Taylor, M.O.V. 1984. Southern Transvaal stone walled sites – a spatial consideration. In: Hall, M., Avery, G., Avery, D.M., Wilson, M.L. & Humphreys, A.J.B. (eds) *Frontiers: southern African Archaeology Today*. Oxford: *BAR International Series* 207: 248–251.
- Turner, C.G. 1979. Dental anthropological indications of agriculture among the Jomon People of Central Japan. *American Journal of Physical Anthropology* 51: 619–636.
- Van Loveren, C. & Duggal, M.S. 2001. The role of diet in caries prevention. *International Dental Journal* 51: 399–406.
- Van Tonder, J.L. & Van Eeden, I.J. 1975. *Abridged Life Tables for all the Population Groups in the Republic of South Africa (1921–70)*. Pretoria: Human Sciences Research Council, South Africa, S-34.
- Viljoen, M.J. & Reimold, W.U. 1999. *An Introduction to South Africa's Geological and Mining Heritage*. Pretoria: Geological Society & Mintek.
- Williams, J.G.P. 1980. *A Colour Atlas of Injury in Sport*. London: Wolfe Medical Publications.
- Wood, J., Milner, G., Harpending, H. & Weiss, K. 1992. The osteological paradox: Problems of inferring prehistoric health from skeletal samples. *Current Anthropology*, 33: 343–368.