

# Alveolar bone resorption following tooth extraction characteristically illustrated

SADJ October 2021, Vol. 76 No. 9 p545- 549

LM Sykes<sup>1</sup>, C Bradfield<sup>2</sup>, K Naidu<sup>3</sup>

## ABSTRACT

Under normal physiological conditions, bone undergoes a constant, balanced and well-regulated process of renewal and remodelling. This is needed for growth, remodelling and maintenance of skeletal form, as well as for homeostasis of skeletal and plasma calcium levels. The alveolar bone grows along with tooth eruption, and thereafter its shape and volume are influenced by local mechanical as well as systemic factors. It is maintained by forces exerted on it via the periodontal ligaments, thus teeth are mandatory for its preservation and renewal. Following tooth loss, the socket becomes filled with a blood coagulum, which is later replaced by fibrous tissue. This healing process is associated with sizeable reduction in ridge height within the first two months that continues at a slower and variable rate throughout life. There are countless examples of patients who have lost teeth at an early age, presenting with severe alveolar bone loss in that area / jaw. The extent is even more dramatic if the edentulous space has been opposed by natural teeth. The cases illustrated in this paper serve to remind clinicians of the need to help patients maintain as many of their natural teeth as possible, while still being cognisant of their aesthetic and functional demands, and the possible health implications.

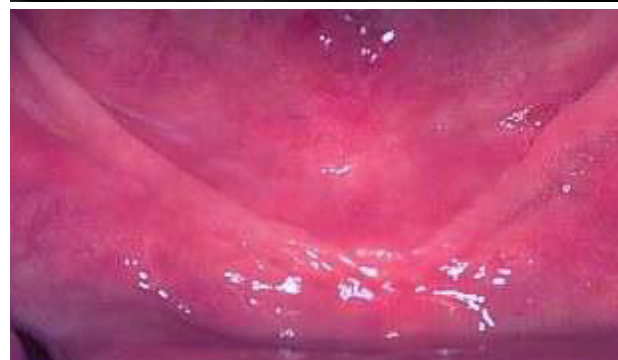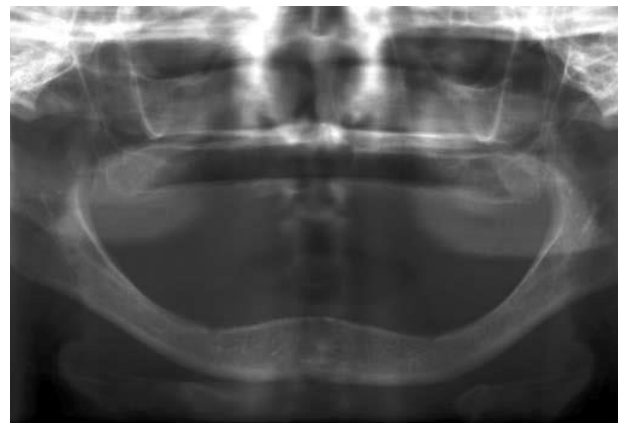
## INTRODUCTION

Bone is a dynamic tissue that undergoes constant renewal and remodelling in response to local mechanical, nutritional, functional and hormonal influences.<sup>1,2</sup> Under normal physiological conditions there is a constant and well-regulated balance between bone formation by osteoblast and osteocytes, and bone resorption by osteoclasts.<sup>1</sup> This process is needed for both the growth, remodelling and maintenance of skeletal

form and structure as well as for homeostasis of skeletal and plasma calcium levels<sup>3</sup>. Disturbances in any of the influencing factors will have a concurrent effect on bone quality and / or quantity.

## Literature review

As early as 1881 Roux postulated that loss of alveolar bone following tooth loss was an example of disuse atrophy. He believed that if “the forces on the bone were reduced, the body would need less bone and so would automatically get rid of that which was not being used”<sup>2</sup>. Glickman (1948) took a more holistic approach and did not consider the bone in isolation but rather as part of a functioning unit. He proposed that “the status of bone equilibrium is variable, dependant on the physiologic and pathologic process of the entire body for its regulation”<sup>4</sup>. This led others to also consider that bone loss may be multifactorial. Sobolik (1960) suggested, “The status of bone equilibrium was under the influence of the physiological and pathological processes of the entire body”. As such, the



**Figure 1.** A panoramic radiograph and B. Intraoral view of a patient with severe ridge resorption following tooth loss

## Author affiliations:

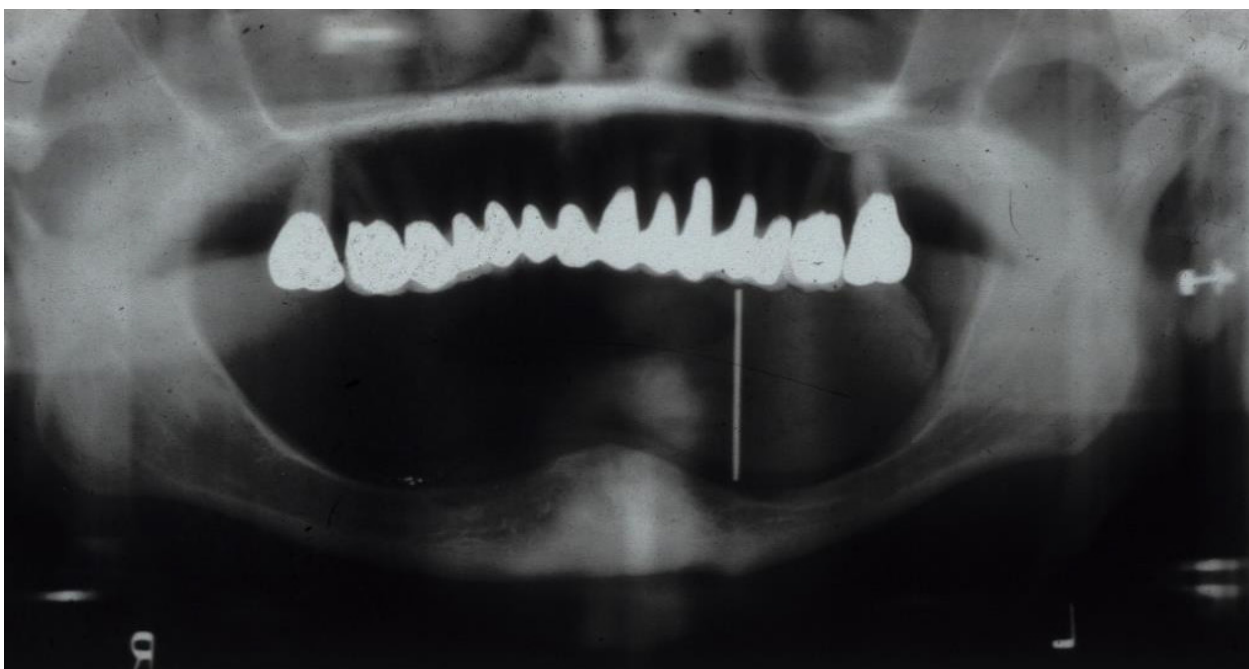
1. **Leanne M Sykes:** BSc, BDS, MDent, IRENSA, Dip Forensic Path, Dip ESMEA; Head of Department of Prosthodontics, University of Pretoria
2. **Charles Bradfield:** B Tech, BChD, Dip Aesthetics; Registrar Department of Prosthodontics, University of Pretoria
3. **Karmisha Naidu:** BcHD, Dip Clin. Management HIV/AIDS, Dip Interceptive Ortho MSC Dent(Pros), Registrar Department of Prosthodontics, University of Pretoria

## Corresponding author: Leanne Sykes

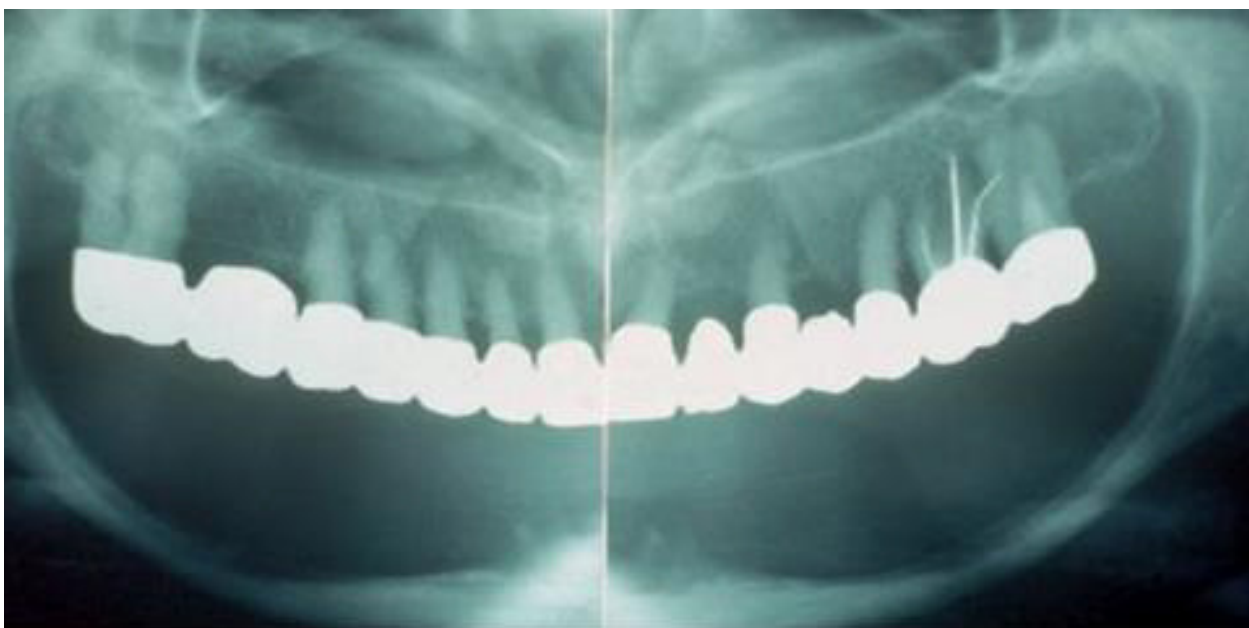Leanne.sykes@up.ac.za  
<https://orcid.org/0000-0002-2002-6238>

## The role played and the respective contribution:

1. **Leanne M Sykes:** Primary author 60%
2. **C Bradfield:** 20%
3. **K Naidu:** 20%



**Figure 2.** Mandibular ridge resorption in an edentulous mandible opposed by a long span maxillary fixed prosthesis (of questionable structure)

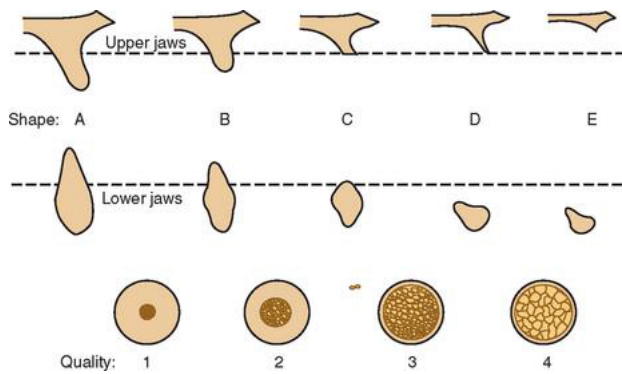


**Figure 3.** Severe mandibular ridge resorption in an edentulous mandible opposed by a long span maxillary fixed prosthesis

amount of resorption after tooth loss would depend on both local factors such as the extent of infection and type of surgical techniques used, as well as systemic factors such as disease, metabolic disturbances and dietary deficiencies<sup>5</sup>. Others used engineering principles to argue how bone adapted in mass and structure according to mechanical demands and that any loading of the bone would result in stress and strain forces being exerted on it. Depending on the direction of the load these forces could be tensile or compressive resulting in either positive or negative strains, and associated bone deposition or resorption respectively<sup>2</sup>. This argument was explained by Qin et al (1998) who postulated that when a tooth was loaded there would be pressures exerted on it causing mechanical stimulation and strains on it as well as in the bone

immediately adjacent to it and in more distant teeth. This along with masticatory muscle actions and reactionary forces in the temporomandibular joints would cause bending of the mandible and result in a steady-state condition of stress and strain that was needed to maintain bone mass<sup>6</sup>. It would then follow that bone resorption was a natural consequence of tooth loss that would result in reduction of the horizontal and vertical dimensions of alveolar bone, and that this process may continue for an unknown and indeterminable time<sup>2</sup>. (Figure 1)

These simplistic philosophies of "use it or lose it" seemed logical and could be justified with many examples of severe bone loss that are seen clinically in patients who have lost teeth at a young age. The bone devastation is even more dramatic



**Figure 4.** Lekholm and Zarb proposed classification of residual jaw shape and rates of bone resorption following tooth extraction, and bone quality.<sup>14</sup>

where the tooth loss is in one arch and the edentulous ridge has been subject to masticatory forces from natural teeth in the opposing arch (Figures 2 and 3)

The understanding behind the various processes involved in bone turnover and alveolar bone resorption have long since been replaced by a deeper insight into bone cell biology, the physiological, biochemical and cellular mechanisms involved in bone turnover and remodelling, and the pathophysiological factors at play during bone destruction.

#### Bone cell biology

This paper will present a brief review of bone homeostasis and the cellular mechanism behind remodelling in order to augment the case illustrations. It will not delve into the complex immunopathogenesis of pathological bone loss, particularly during periodontal disease or because of systemic disturbances. There are many excellent and detailed articles dealing with the host and microbial factors responsible for the disease process should colleagues be interested in reading further.

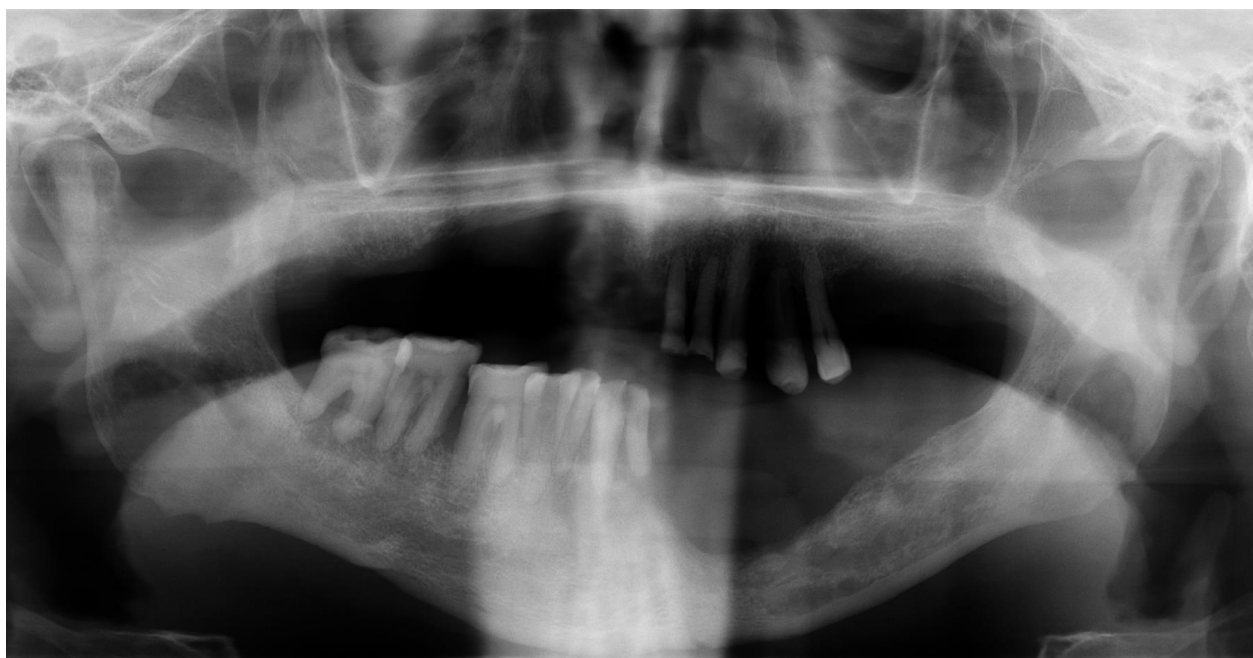
The alveolar process is that part of the mandible and maxilla that surrounds and supports the teeth. It consists of an outer layer of compact cortical bone surrounding an inner layer of

trabecular bone. This architecture provides it with both rigidity and low weight<sup>7</sup>. The alveolar bone forms part of the periodontium, along with the gingiva, periodontal ligament, and root cement. The “ligaments join the cementum to the bone and are responsible for the mobility of the teeth, and for distributing and resorbing masticatory forces”<sup>7</sup>. Bone is a cellular and richly vascularized, “dynamic, active tissue undergoing constant renewal in response to mechanical, nutritional, hormonal, and concentration of circulating calcium influences.”<sup>1,7</sup>. Under normal physiological conditions, formation and resorption are ongoing processes. The bone quality and quantity are determined by the interactions between the osteocytic and bone lining cells regulation, together with osteoblastic formation and osteoclastic resorption. In health, there is a constant and fine balance between these processes which ensures skeletal growth and maintenance, as well as homeostasis and regulation of bone and serum calcium levels<sup>1</sup>. The remodelling cycle is an “ongoing process which occurs throughout the skeleton in focal units called bone remodelling units (BMUs)”<sup>1</sup>. It is estimated that there are over 1 million of these units actively engaged in bone turnover at any given time<sup>7</sup>. During bone modelling, “the bones are shaped or reshaped by osteoclasts and osteoblasts working independently, while during remodelling, they are coupled”. The two processes occur simultaneously throughout life to ensure that the strength of the skeleton is maintained, to repair small stress fractures, and to allow the body to adapt to functional loading<sup>8</sup>.

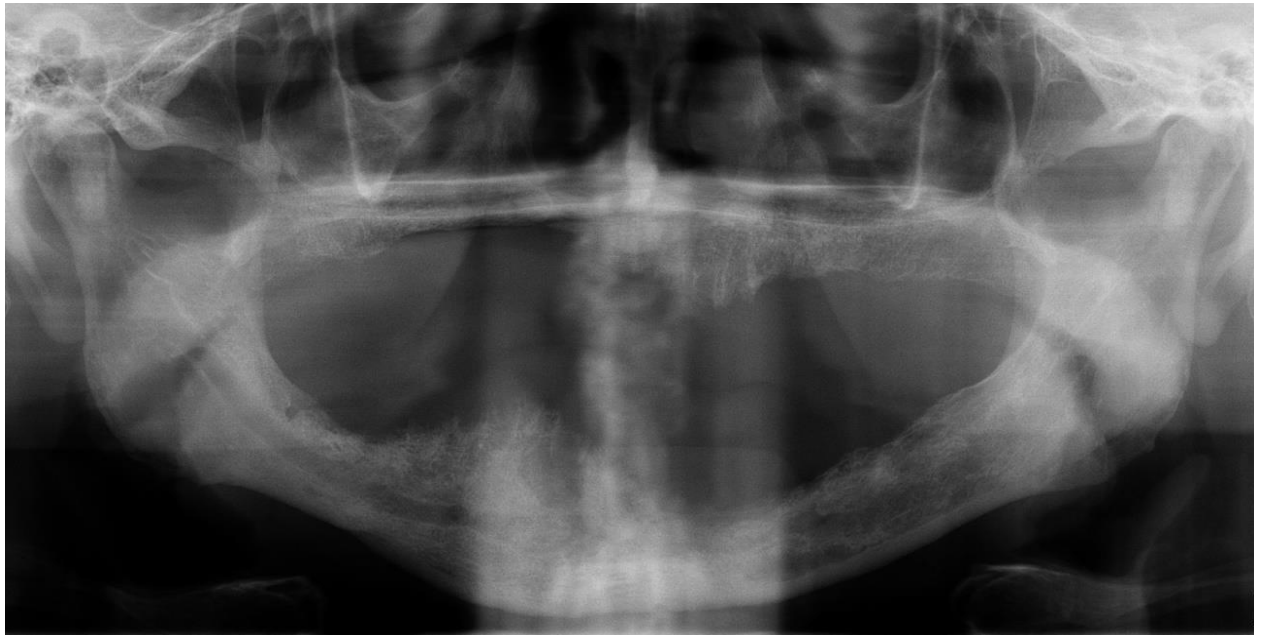
#### Bone cells

“Preosteoblasts, osteoblasts, osteocytes and bone lining cells all arise from primitive mesenchymal cells in bone marrow stroma, while the pericytes arise from connective tissue blood vessels”<sup>1</sup>.

Osteoblasts primary role is bone formation, but they also express factors that influence the environmental response to osteoclasts resulting in “localisation, induction, stimulation, inhibition and resorption”. Osteoblasts are also responsible for producing proteases that dissolve the nonmineralised osteoid that covers the mineralised bone matrix. This must occur



**Figure 5.** Bone preservation in dentate areas and severe resorption in edentulous areas



**Figure 6.** Unevenly resorbed ridges

before the osteoclasts can attach and initiate resorption<sup>9</sup>. Osteocytes are “mature bone cells within the bone matrix and are responsible for mobilisation of calcium from the matrix” if there is a systemic demand for this.<sup>1</sup>

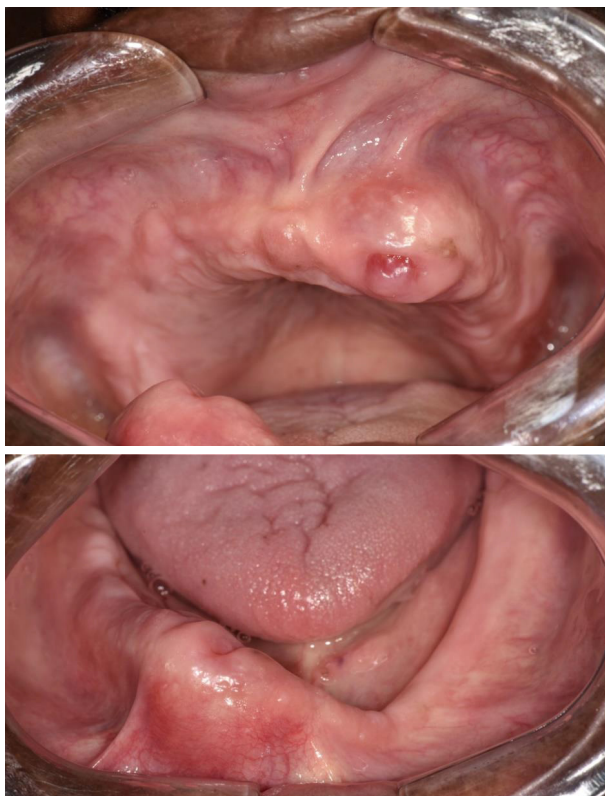
Bone lining cells are multifunctional and play a role in “regulating the ionic composition of bone fluid, protecting surface bone from osteoclastic activity and regulation of new bone formation or resorption”<sup>11</sup>. Osteoclasts are derived from haematopoietic stem cells, and are “specialised into motile, migratory bone resorbing cells”. Their function is degradation of mineralised bone and thus play a lifelong role in “normal

skeletal growth, development and maintenance, as well as calcium metabolism”.

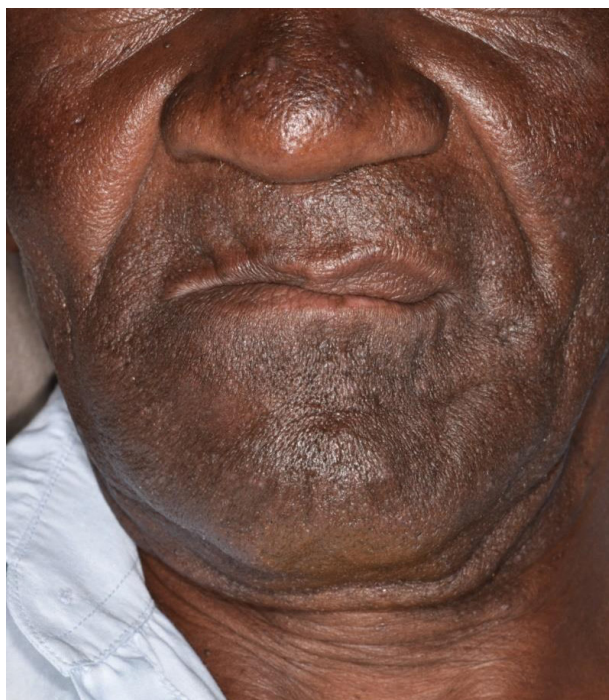
Once attached to the mineralised matrix their cytoskeleton becomes reorganised and they form a sealing zone which isolates the resorption site. They also develop a ruffled border which secretes protease enzymes allowing them to remove both the mineral and organic components of the bone matrix<sup>9</sup>. The “rate of bone resorption can be regulated at the level of differentiation of osteoclasts from their precursor cells, or through the regulation of key functional proteins which control their attachment, migration and resorptive activities”<sup>9,10</sup>. Bone resorption is “also regulated locally by ionized calcium which is generated during osteoclastic resorption”<sup>11</sup>. The process of bone resorption is followed by a short reversal phase, which marks the transition from destruction to repair. During this time, there is simultaneous resorption and formation. Thereafter bone formation commences and takes place in two stages. There is an initial deposition of osteoid (primarily type I collagen), followed by calcification and mineralisation (primarily hydroxyapatite)<sup>12</sup>. This process is largely mediated by non collagenous bone matrix proteins, which also play a role in cellular adhesion and the regulation of formation and resorption.

#### Alveolar bone mechanics and tooth loss

The alveolar bone grows “at a speed concomitant with that of tooth eruption” during the post-eruption phase, due to the forces exerted on it via the periodontal ligaments<sup>13</sup>. “It’s volume is determined by tooth shape, inclination and tooth axis during eruption”<sup>13</sup>. Thereafter turnover is influenced by local mechanical as well as systemic factors. In the mandible, the rate is almost twice that of the maxilla. This has been explained by the fact that the mandible is only attached distally to the rest of the skull. This permits it to function as a “cantilever”, but also allows for “deformation in the midline in three directions during jaw movements”, as well as “at the side regions due to muscular contractions during jaw opening and protrusion”<sup>8</sup>. Teeth are mandatory for the maintenance of alveolar bone. Following tooth loss the socket becomes filled with a blood coagulum which is later replaced by fibrous connective tissue<sup>8</sup>. The healing process then commences and is associated



**Figure 7 and 8.** Difficult anatomical foundation for denture construction



**Figure 9.** Difficult anatomical foundation for denture construction

with about a 50% reduction in ridge height within the first two months (however there is great individual variation)<sup>8</sup>. In the first 7-year period the rate of bone loss is almost four times greater in the mandible than the maxilla due to the far smaller load bearing area and distortion of the former as mentioned above<sup>8</sup>. This has been well illustrated by Lekholm and Zarb in their proposed classifications of residual ridge shape and bone quality (Figure 4)<sup>14</sup>.

In figures A) most of the ridge is still present; B) moderate resorption has occurred; C) advanced resorption and only basal bone remaining; D) some basal bone resorption; E) extreme basal bone resorption. The bone quality depicted in 1) is mostly compact bone; 2) thick compact bone surrounding a core of dense trabecular bone; 3) thin layer of cortical bone surrounding a core of dense trabecular bone; 4) thin layer of cortical bone surrounding a core of low density trabecular bone.

#### Patient case illustration

A 74-year-old male patient presented with teeth 21 to 25 in the maxilla and 41 to 48 in the mandible. He reported that the rest of his teeth had been extracted intermittently over the past 20 years or more. The remaining teeth all exhibited class III mobility and were clinically over erupted and splayed. The panoramic radiograph showed severe bone loss around all of the teeth (Figure 4). It also illustrated the classical picture described in this paper of alveolar bone preservation in the quadrants where his teeth had been retained, and the severe resorption in the edentulous areas. This is particularly extensive in the posterior first quadrant and the anterior third quadrant where the edentulous areas had been subject to the masticatory forces of the opposing teeth.

All teeth were deemed unsalvageable and subsequently extracted. Note how this has resulted in the most unfavourable ridge conformation (Figure 5). This will be a challenge

for denture construction (Figures 6 and 7) and result in poor aesthetics due to the underlying alveolar ridge anatomy (Figure 8). It is however a classical illustration of Alveolar bone resorption following tooth extraction

## CONCLUSION

With the advent of implant therapy, it has become all too easy and tempting for practitioners to extract questionable teeth and promise the patients replacement with implants. However, this treatment modality is not economically accessible to the majority of South African patients. In addition, it may not be possible due to confounding local or systemic factors. Dentists should still strive to adhere to the long held ethical standard of “first do no harm”. They need to develop a holistic approach to treatment planning and help patients maintain as many of their natural teeth as possible, while still being cognisant of their aesthetic and functional demands and possible health implications.

## References

1. Hienz S, Paliwal S, Ivanovski S. Mechanisms of bone resorption in periodontitis. *J Immunol Res* 2015; <http://dx.doi.org/10.1155/2015/615486>.
2. Hansson S, Halldin A. Alveolar ridge resorption after tooth extraction: A consequence of a fundamental principle of bone physiology. *J Dent Biomech* 2012; 3([doi:10.1177/1758736012456543](https://doi.org/10.1177/1758736012456543)).
3. Teitelbaum S. Osteoclasts: what they do and how do they do it? *Am J of Pathology*. 2007; 170(2):427-35.
4. Glickman I. The periodontal structures and removable partial denture prostheses. *JADA* 1948; 37:311-6.
5. Sobolik C. Alveolar bone resorption *JPD*. 1960; 10(4):612-9.
6. Qin Y-X, Rubin, CT, McLeod, KJ. Nonlinear dependence of loading intensity and cycle number in maintenance of bone mass and morphology. *J Orthop Res* 1998; 16:482-9.
7. Linde J, Karring T, Lang NP. *Clinical periodontology and implant dentistry*. Munksgaard, editor. Copenhagen 1998.
8. Jonasson G, Skoglund I, Rythen M. The rise and fall of the alveolar process: dependency of teeth and metabolic aspects. *Arch Oral Biol* 2018; 96:195-200.
9. Wiebe S, Hafezi M, Sandhu HS, et al. Osteoclast activation in inflammatory periodontal disease *Oral Dis* 1996; 2(2):167-80.
10. R B. Molecular mechanisms of bone resorption by the osteoclast *Anatomical Record*. 1989; 224(2):317-24.
11. Zaida M, Alam AS, Shankar VS, et al. Cellular biology of bone resorption *Biol Rev Cambridge Phil Soc* 1993; 68(2):197-264.
12. Baron R. Molecular mechanisms of bone resorption. An update. *Acta Orthopaedica Scandinavica* 1995; 66(266):66-79.
13. Puspitadewi SR, Kusdhany LS, Masulili SLC, et al. The role of parathyroid hormone in alveolar bone resorption on postmenopausal women. *The Open Dentistry Journal*. 2020; 14:82-7.
14. Branemark P-I, Zarb GA, Albrektsson T. *Tissue-integrated prostheses. Osseointegration in clinical dentistry*. Co. QP, editor. Chicago: Quintessence Publishing Co.; 1985.