



UNIVERSITEIT VAN PRETORIA
UNIVERSITY OF PRETORIA
YUNIBESITHI YA PRETORIA

**DEVELOPMENT OF AN ADULT CHEST IMAGING PROTOCOL FOR LODOX X-RAY SYSTEMS AT TRAUMA UNITS IN
SOUTH AFRICA**

MUCHUI JULIUS THAMBURA

Student No: 10508202

Submitted in fulfilment of the requirements for the degree

Philosophy Doctor

in Radiography (Diagnostics)

In the

Faculty of Health Sciences

at the

University of Pretoria.

2022

Supervisor: Dr Jeanette du Plessis

Co-supervisor: Prof Cheryl M E McCrindle

DECLARATION

I, Muchui Julius Thambura, declare that the thesis, which I hereby submit for the degree of PhD at the University of Pretoria, is my own work and has not previously been submitted by me for a degree at this or any other tertiary institution.



21 April 2022

Signature

Date

DEDICATION

I would like to dedicate this research to my family for their endless love, support and encouragement throughout.

ACKNOWLEDGEMENTS

Firstly, I would like to thank Almighty God for enabling me to consistently focus on this research. A lot has happened in the process but his steadfast love for me has been abundant.

I would also like to extend my appreciation to the following people for their respective contributions to this study:

- My supervisor, Dr Jeanetta du Plessis, for keeping me on my toes. Your encouragement and valuable critique have shaped me from the beginning of my journey. You indeed have invested a lot of knowledge and time in me. Thank you!
- My co-supervisor, Prof CME McCrindle. Prof, you not only banked knowledge in me, but your wise words have made me better than I was at the beginning of my journey. Thank you!
- Radiologists at Steve Biko Academic Hospital and Dr Scholtz and Partners for participating in reporting the images used in this research.
- Special acknowledgement to Prof Kenneth David Boffard, immediate president of the International Association for the Surgery of Trauma and Surgical Intensive Care (IATSIC) for the time invested in this research.
- I acknowledge Prof Andreas Engelbrecht and Dr Vidya Laloo, at the Department of Emergency Medicine at the University of Pretoria for their support during data collection.
- Trauma specialists both nurses and doctors working at trauma centres that used Lodox x-ray systems across South Africa. They spent their valuable time participating in this research.
- Physicists for assisting in taking the measurements of the variables on the two imaging modalities.
- I would like to express my sincere gratitude to the Lodox Company for sponsoring the pilot study
- I acknowledge the funding from the National Research Foundation (NRF) of South Africa.
- I also acknowledge the funding by the University of Pretoria under the Research Development Programme (RDP).

SUMMARY

TITLE: Development of an adult chest imaging protocol for Lodox x-ray systems at trauma units in South Africa

CANDIDATE: Muchui Julius Thambura

Degree: PhD

SUPERVISOR: Dr Jeanetta du Plessis

CO-SUPERVISOR: Prof Cheryl ME McCrindle

Background, problem statement, aim and objectives

The Lodox (Lodox® Systems (Pty) Ltd, South Africa) digital x-ray system was initially developed to assist in the detection of diamonds smuggled by employees in mines but later adopted as a screening tool at hospital trauma units. Although one-third of patients are sent for additional chest x-ray imaging using a conventional x-ray machine, previous research has shown that the Lodox x-ray system can produce chest images of superior quality. The Lodox x-ray system also produces ten times less harmful radiation, although requesting additional images after a Lodox imaging has been performed increases the radiation dose to the patient. This study aimed at developing an adult chest referral pathway (imaging protocol) guidelines for the Lodox x-ray system used at trauma units in South Africa. The objectives were to assess the diagnostic similarities and quality of images acquired with a Lodox x-ray system compared to those acquired with a conventional x-ray system; then to formulate and verify the referral pathway (imaging protocol) guidelines for adult chest imaging using a Lodox x-ray system in trauma units.

Method

This research used a descriptive, correlation design, including content analysis, a structured observation, and an e-Delphi technique.

Results

When comparing the two sets of images obtained from the Lodox and conventional x-ray systems respectively, the Lodox images were superior to those from the conventional x-ray images for showing thoracic structures such as lung parenchyma, thoracic cage, soft tissue outline and the mediastinal structures. In contrast, conventional x-ray images were better than the Lodox x-ray images for pulmonary effusion, extra-luminal air and pneumothorax. Both imaging systems were similar for the visualisation of other thoracic structures. No significant differences were found for

the factors affecting image quality for the two systems. Hence it was recommended that clinical indications should inform the referral of patients for Lodox imaging.

Discussion of the findings

The results confirmed that although both x-ray systems produced chest images of high quality, the Lodox x-ray system produced images of superior quality to conventional images for the viewing of some of thoracic structures such as fractures of the clavicle, nodules, effusions, retro-cardiac structures, mediastinum structures, pneumothorax, interstitial diseases, and fractures of ribs, fractures of clavicle and lung parenchyma. Additionally, following the e-Delphi process, a referral pathway (imaging protocol) for patients undergoing Lodox imaging was developed. The referral pathway (imaging protocol) suggested that after chest imaging with the Lodox x-ray system, computed tomography (CT) imaging of the chest and Ultrasound imaging should be requested. However, for certain cases, the patient could be referred directly for CT- and Ultrasound imaging of the chest, particularly in critically injured patients, where the rapid initiation of treatment could be lifesaving.

Conclusions and Recommendations

The study confirmed that adult chest images obtained using the Lodox x-ray system in trauma units was of diagnostic quality. Hence, it was recommended that not all patients should automatically be referred for additional imaging with a conventional x-ray system. Instead, the Lodox images together with the clinical condition of the patient should inform the referral of the patient for additional imaging. Following these results, a referral pathway (imaging protocol) was developed for Lodox imaging at trauma units at hospitals in South Africa.

Keywords: Lodox x-ray system, full-body Statscan, conventional x-ray system, chest trauma radiography, imaging protocol, referral pathway

TABLE OF CONTENTS

| | |
|--|-----------|
| DECLARATION..... | i |
| DEDICATION | ii |
| ACKNOWLEDGEMENTS | iii |
| LIST OF FIGURES | x |
| LIST OF TABLES | xi |
| DEFINITION OF TERMS | xiii |
| LIST OF ABBREVIATIONS AND ACRONYMS..... | xv |
| CHAPTER 1: INTRODUCTION, BACKGROUND AND ORIENTATION TO THE RESEARCH..... | 1 |
| 1.1 Introduction..... | 1 |
| 1.2 Background..... | 1 |
| 1.3 Justification, rationale, and significance | 2 |
| 1.4 Problem statement | 3 |
| 1.5 Research question aim and objectives..... | 4 |
| 1.5.1 Aim and objectives | 5 |
| 1.5.2 Aim of the research..... | 5 |
| 1.5.3 Objectives of the research | 5 |
| 1.6 Demarcation and scope of the study | 6 |
| 1.7 Overview of the research methodology and design | 6 |
| 1.7.1 Objective 1 and 2 of Phase 1..... | 6 |
| 1.7.2 Objective 1 and 2 of Phase 2..... | 8 |
| 1.8 Overview of the chapters..... | 8 |
| 1.9 Ethical considerations | 9 |
| CHAPTER 2: LITERATURE REVIEW | 11 |
| 2.1 Introduction..... | 11 |
| 2.2 Theoretical framework..... | 11 |
| 2.3 Diagnostic efficacy of the Lodox and conventional x-ray systems..... | 12 |
| 2.4 Radiological features on an adult chest image | 13 |
| 2.4.1 Visualisation of the normal anatomy of the trachea, bronchi, vascular pattern, and some variances..... | 13 |
| 2.4.2 Visualisation of lung parenchyma and some pathological variances | 15 |
| 2.4.3 Visualisation of the pleura and some pathological variances..... | 17 |
| 2.4.4 Visualisation of the mediastinal structures and some pathological variances | 20 |
| 2.4.5 Visualisation of the thoracic cage and associated pathologies..... | 21 |
| 2.5 Factors impacting image quality | 23 |
| 2.5.1 Size distortion..... | 23 |
| 2.5.2 Spatial resolution | 24 |
| 2.5.3 Contrast resolution | 26 |
| 2.5.4 Dark noise..... | 26 |
| 2.6 Development of clinical protocols | 28 |
| 2.6.1. Implications of using clinical guidelines in practice | 29 |
| 2.6.2 Process of development of referral pathway (imaging protocol) guidelines | 29 |
| CHAPTER 3: RESEARCH DESIGN AND METHODOLOGY | 32 |
| 3.1. Introduction | 32 |
| 3.2 Theoretical background | 32 |
| 3.2.1 Research paradigm..... | 32 |
| 3.2.2 Research approach..... | 32 |

| | |
|--|-----------|
| 3.2.3 Mode of Inquiry..... | 33 |
| 3.2.4 Research design..... | 33 |
| 3.3 Conceptual framework..... | 35 |
| 3.4 Research Methods..... | 36 |
| 3.5 Research Setting..... | 36 |
| 3.5.1 Data Accumulation for Phase 1..... | 36 |
| 3.5.2 Unit of analysis for images used in Objectives 1 and 2 (Phase 1)..... | 37 |
| 3.5.3 Objective 1 of Phase 1..... | 38 |
| 3.5.4 Objective 2 of Phase 1..... | 39 |
| 3.5.5 Measurement of factors affecting image quality..... | 41 |
| 3.6 Formulation of referral pathway (imaging protocol) guidelines..... | 45 |
| 3.6.1 Introduction..... | 45 |
| 3.6.2 Research method used for the formulation of guidelines..... | 45 |
| 3.6.3 Sample selection and sample size used for the formulation of referral pathway (imaging protocol) guidelines..... | 46 |
| 3.6.4 Data collection process and analysis for the formulation of referral pathway (imaging protocol) guidelines..... | 47 |
| 3.6.5 Validation of the process used in the formulation of referral pathway (imaging protocol) guidelines..... | 48 |
| 3.7 Verification of referral pathway (imaging protocol) guidelines..... | 48 |
| 3.7.1 Validation of data collection and process of guideline developed..... | 49 |
| 3.7.2 Description of the framework used in the validation of the protocol guidelines..... | 50 |
| 3.7.3 Determination of consensus in e-Delphi technique..... | 51 |
| 3.8 Summary..... | 52 |
| CHAPTER 4: RESULTS PHASE ONE: DIAGNOSTIC SIMILARITY AND QUALITY OF IMAGES..... | 54 |
| 4.1 Introduction..... | 54 |
| 4.2 Diagnostic similarities of chest images obtained from Lodox- and conventional x-ray systems..... | 54 |
| 4.3 Analysis of diagnostic similarities of the images..... | 54 |
| 4.4 Results for diagnostic similarity of the images..... | 55 |
| 4.4.1 Artefacts and beam penetration..... | 55 |
| 4.4.2 The trachea, bronchial and vascular patterns..... | 55 |
| 4.4.3 The lung parenchyma..... | 56 |
| 4.4.4 The pleura..... | 59 |
| 4.4.5 Mediastinal structures..... | 60 |
| 4.4.7 Discussion of the results for the comparison of diagnostic similarities for chest images (conventional x-ray systems and Lodox full-body programme)..... | 64 |
| 4.5 Diagnostic quality (Conventional and Lodox Chest Dedicated Programme Images)..... | 64 |
| 4.5.1 Data analysis on diagnostic quality of images..... | 65 |
| 4.5.2 Artefacts and Beam penetration..... | 65 |
| 4.5.3 The trachea, bronchial- and vascular patterns..... | 66 |
| 4.5.4 The lung parenchyma..... | 66 |
| 4.5.5 The disorders of the pleura..... | 68 |
| 4.5.6 Mediastinal structures and associated pathologies..... | 69 |
| 4.5.7. The thoracic cage..... | 70 |
| 4.5.8 Discussion of the results for the comparison of diagnostic similarities for chest images (conventional x-ray systems and Lodox chest-dedicated programme)..... | 73 |
| 4.6 Results of measurement of factors impacting on image quality..... | 73 |
| 4.6.1 Measurement of variables on the images..... | 74 |
| 4.7 Discussion of the data analysis for diagnostic similarity and diagnostic quality of chest images..... | 79 |

| | |
|---|------------|
| 4.7.1 Inter-rater agreement | 79 |
| 4.7.2 Percentage agreement between radiologists at a public hospital and those from a private hospital | 80 |
| 4.7.3 Intra-rater reliability..... | 81 |
| 4.7.4 Summary | 81 |
| 4.8 Summary | 82 |
| CHAPTER 5: FORMULATION AND VERIFICATION OF REFERRAL PATHWAY (IMAGING PROTOCOL) GUIDELINES..... | 83 |
| 5.1 Introduction..... | 83 |
| 5.2 Participants' demographics..... | 83 |
| 5.3 Results on the formulation of the referral pathway (imaging protocol) guidelines (e-Delphi Round 1)..... | 85 |
| 5.3.1 Training for referral of patients for Lodox imaging..... | 85 |
| 5.3.2 Triage and clinical indication for patients undergoing Lodox imaging(n=18)..... | 88 |
| 5.3.3 Referral of patient for additional imaging after Lodox imaging..... | 100 |
| 5.4 Results for verification of the referral pathway (imaging protocol) guidelines in Delphi Round 2 | 111 |
| 5.4.1 e-Delphi Round 2..... | 111 |
| 5.4.2 Results the verification of referral pathway (imaging protocol) guidelines | 111 |
| 5.5 Adjustment of the guidelines by the researcher..... | 129 |
| 5.6 Review of data analysis by the researcher..... | 130 |
| 5.7 Validation of the process used in the development of the referral pathway (imaging protocol) guidelines | 130 |
| 5.7.1 Calculating the domain score..... | 135 |
| 5.8 Summary | 135 |
| CHAPTER 6: DISCUSSION OF THE RESULTS | 137 |
| 6.1 Introduction..... | 137 |
| 6.2 Diagnostic similarities of adult chest images | 137 |
| 6.2.1 Artefacts and beam penetration..... | 137 |
| 6.3 Visualisation of lung parenchyma tracheobronchial and vascular patterns..... | 139 |
| 6.3.1 Anatomy of lung parenchyma..... | 139 |
| 6.3.2 Anatomy of tracheobronchial structures..... | 140 |
| 6.3.3 Anatomy of the pulmonary vasculature | 140 |
| 6.3.4 Disorders of the lung parenchyma and their pathological patterns..... | 141 |
| 6.3.5 Disorders of the pleura and their pattern presentations..... | 145 |
| 6.3.6 Mediastinal structures and associated pathologies..... | 148 |
| 6.3.7 Structures of the thoracic cage and associated pathologies | 150 |
| 6.4 Discussion of the diagnostic quality of chest images..... | 154 |
| 6.4.1 Diagnostic quality of a chest images and size distortion | 154 |
| 6.4.2 Diagnostic quality of chest images and level of spatial resolution | 156 |
| 6.4.3 Diagnostic quality of chest images and level of contrast resolution | 157 |
| 6.4.4 Diagnostic quality of chest images and level of dark noise on the image | 158 |
| 6.5 Discussion of Phase 2: Development and formulation of referral pathway (imaging protocol) guidelines | 161 |
| 6.5.1 Introduction | 161 |
| 6.5.2 Name of the guidelines | 161 |
| 6.5.3 Overall aim of the guidelines | 162 |
| 6.5.4 Scope of guidelines | 162 |
| 6.5.5 Purposed process of guidelines development..... | 162 |
| 6.5.6 Referral pathway (imaging protocol) guidelines..... | 162 |

| | |
|--|------------|
| 6.6 Referral pathway (imaging protocol) guidelines for trauma patients undergoing Lodox chest imaging..... | 174 |
| CHAPTER 7: SUMMARY OF THE FINDINGS, ESTABLISHMENT OF THE PROTOCOL, RECOMMENDATIONS AND CONCLUSION | 176 |
| 7.1 Introduction..... | 176 |
| 7.2 Summary of the findings | 176 |
| 7.3 Establishment of referral pathway (imaging protocol) guidelines Lodox imaging | 177 |
| 7.4 Referral pathway (imaging protocol) for adult chest imaging with the Lodox x-ray system | 181 |
| 7.5 Recommendations | 182 |
| 7.6 Implications of this research | 184 |
| 7.7 Limitations of this research..... | 184 |
| 7.8 Contribution to the body of knowledge..... | 185 |
| 7.9 Conclusion | 187 |
| REFERENCES | 190 |
| ANNEXURES | 198 |
| ANNEXURE A: RESULTS FOR A PILOT STUDY..... | 198 |
| ANNEXURE B: RADIOLOGISTS' CHECKLISTS..... | 202 |
| ANNEXURE C: QUALITY ASSURANCE CHECKLISTS..... | 204 |
| ANNEXURE D: MOTIVATION LETTER FROM PHYSICISTS | 205 |
| ANNEXURE E: SAMPLE OF HOSPITALS ETHICS APPROVAL (DR GEORGE MUKHARI ACADEMIC HOSPITAL)..... | 206 |
| ANNEXURE F: LETTER OF CONSULTATION TO THE STATISTICIAN..... | 207 |
| ANNEXURE G: CRITERIA FOR EVALUATING THE DEVELOPED PROTOCOL..... | 208 |
| ANNEXURE H: PARTICIPANT CONSENT- PATIENT ICD1A | 210 |
| ANNEXURE I: LETTER OF INVITATION AND PARTICIPANT CONSENT FOR DELPHI - PATIENT ICD1A | 212 |
| ANNEXURE J: DELPHI QUESTIONS ROUND 1 (OBJECTIVE 1) | 214 |
| ANNEXURE K: ETHICS. APPROVAL FROM THE UNIVERSITY OF PRETORIA | 218 |
| ANNEXURE L: DELPHI QUESTIONS ROUND 2. | 219 |
| ANNEXURE M : DECLARATION OF PROFESSIONAL EDITING | 226 |

LIST OF FIGURES

Figure 3.1: Flow diagram on the conceptual framework..... 35

Figure 3.2: A schematic representing o the NORMI 13 Phantom¹¹⁰ 43

Figure 4.1: Comparison of geometric distortion for the two imaging systems 74

Figure 4.2: Comparison of spatial resolution for the two imaging systems 75

Figure 4.3: Comparison of contrast resolution for the two imaging systems..... 76

Figure 4.4: Comparison of image noise (dark noise) for the two imaging systems 77

Figure 7.1: Referral pathway (imaging protocol) for adult patients undergoing full-body Lodox imaging..... 178

Figure 7.2: Referral pathway (imaging protocol) for an adult patient undergoing chest imaging using Lodox imaging..... 180

•

LIST OF TABLES

| | |
|--|-----|
| Table 4.1: Diagnostic similarities for artefacts and beam penetration..... | 55 |
| Table 4.2: Diagnostic similarities for the trachea, bronchial and vascular patterns..... | 56 |
| Table 4.3: Diagnostic similarities for the lung parenchyma (infiltrative) disease..... | 57 |
| Table 4.4: Diagnostic similarities for the lung parenchyma (alveolar disease)..... | 58 |
| Table 4.5: Similarity of disorders of the pleura for the two imaging systems..... | 59 |
| Table 4.6: Diagnostic similarities for the mediastinal structures..... | 60 |
| Table 4.7: Diagnostic similarities for the structures of the thoracic cage..... | 62 |
| Table 4.8: Diagnostic quality for imaging artefacts and beam penetration..... | 65 |
| Table 4.9: Diagnostic quality for the trachea, bronchial and vascular patterns..... | 66 |
| Table 4.10: Diagnostic quality for the lung parenchyma (infiltrative disease)..... | 67 |
| Table 4.11: Diagnostic quality of the lung parenchyma (alveolar disease)..... | 68 |
| Table 4.12: Diagnostic quality for the pleura..... | 69 |
| Table 4.13: Diagnostic quality of the mediastinal structures..... | 70 |
| | |
| Table 5.1: Participants' demographic details (n=18) for Rounds 1 and 2 of the e-Delphi process.. | 83 |
| Table 5.2: Referral of patients for Lodox imaging(n=18)..... | 86 |
| Table 5.3: Training on Lodox imaging(n=18)..... | 87 |
| Table 5.4: Activities that are performed at a prehospital setting before Lodox imaging..... | 88 |
| Table 5.5: Vital signs indicative of referral for Lodox imaging(n=18)..... | 89 |
| Table 5.6: Clinical indications for Lodox imaging..... | 91 |
| Table 5.7: Regional images in order of priority in trauma patient management..... | 93 |
| Table 5.8: Clinical indication for skull Lodox imaging..... | 94 |
| Table 5.9: Clinical indications for chest Lodox imaging..... | 95 |
| Table 5.10: Clinical indications for abdominal-pelvic Lodox imaging..... | 97 |
| Table 5.11: Clinical indications for limb/extremities Lodox imaging..... | 98 |
| Table 5.12: Clinical indications for Lodox imaging the spine..... | 99 |
| Clinical indications for Lodox imaging the spine (cervical, thoracic, lumbar, and sacral)..... | 99 |
| Clinical indications for Lodox imaging the spine were:..... | 100 |
| Table 5.13: Referral of patients for conventional imaging and other imaging modalities..... | 101 |
| Table 5.14: Referral of a patient for Ultrasound imaging without requesting full-body Lodox imaging..... | 102 |

| | |
|---|-----|
| Table 5.15: Referral of a patient for CT imaging without undergoing Lodox imaging..... | 104 |
| Table 5.16: Features on CT images of patients who had undergone a Lodox imaging | 105 |
| Table 5.17: Reasons for requesting contrast-enhanced full-body CT imaging after Lodox full-body imaging..... | 108 |
| Table 5.18: Clinical indications for requesting chest Ultrasound imaging when CT imaging is unavailable | 109 |
| Table 5.19: Activities that are performed at prehospital setting before Lodox imaging..... | 112 |
| Table 5.20: Clinical indications for Lodox imaging | 114 |
| Table 5.21: Referral of a patient for Lodox imaging..... | 118 |
| Table 5.22: Clinical indications for abdominal-pelvic Lodox imaging | 119 |
| Table 5.23: Clinical indications for limb/extremities Lodox imaging (n=10)..... | 121 |
| Table 5.24: Clinical indications for a chest Lodox imaging..... | 123 |
| Table 5.25: Patient referral for CT imaging without undergoing Lodox imaging..... | 125 |
| Table 5.26: Referral of patient for full-body contrast-enhanced CT imaging after Lodox imaging..... | 126 |
| Table 5.27: Clinical indications for CT imaging of the chest after Lodox imaging of the chest | 127 |
| Table 5.28: Rating by appraiser 1..... | 132 |
| Table 5.29: Rating by appraiser 2..... | 133 |
| Table 5.30: Rating by appraiser 3..... | 134 |
| Table 5.31: Calculation of the domains..... | 135 |
| | |
| Table 7.1: Clinical indications and suggested imaging modalities for trauma patients..... | 179 |

DEFINITION OF TERMS

| Term | Description of meaning with references |
|----------------------------|---|
| Chest-dedicated programme | This is a coded instruction for obtaining chest images. ¹ |
| Contrast resolution | This is the ability to distinguish many shades of grey from black to white. Anatomical structures of similar subject contrasts are identified or distinguished by the use of shades of greys. ² |
| Conventional x-ray systems | The machine is currently used for taking images for diagnostic purposes by use of x-rays. ³⁻⁴ |
| Diagnostic similarity | This refers to degree of resemblance of the discernible features as demonstrated on images under comparison. |
| Diagnostic quality | This is the ability of an imaging system to demonstrate a radiological feature. |
| Distortion | This is the unequal magnification of different portions of the same object. ^{2,5} |
| Efficacy | The ability of a system to produce the intended results. In this study, the Lodox x-ray system can produce images of diagnostic quality and accuracy in comparison to those of conventional x-ray systems. ⁶ |
| Interstitial lung disease | Interstitial lung disease refers to a chronic lung disorders characterized by inflammation and scarring of the tissue between bronchi, alveoli, and blood vessels of the lung, that make it hard for the lungs to get enough oxygen. |
| Imaging protocol | <p>Protocol means predefined rules, procedures or a written set of step-by-step instructions compiled to guide people in carrying out complex routine operations like management of the patient condition.⁷ It is also a set of guidelines that are used to manage a certain clinical or administrative problem by streamlining day-to-day activities from chaos into a well-defined chain of activities for the welfare of a patient.⁷ In clinical practice, it is guidelines or systematically developed statements that assist healthcare workers in decision-making about appropriate care for specific clinical circumstances upon presentation of a patient in a hospital.⁸</p> <p>In this research, an imaging protocol is a set of rules or specific guidelines which are expected to be followed in detail with little scope of variation towards management of adult patients (above 18 years) that has been referred for Lodox imaging at trauma units in South Africa.⁹ This research has</p> |

| | |
|--------------------|---|
| | reviewed the significance of additional conventional chest x-ray images that are usually requested after Lodox imaging has been performed and guided on a referral pathway for adult chest imaging after full-body Lodox imaging has been performed. ^{7,9} |
| Lodox [®] | This is a Low-Dose X-rays (Lodox) system used for screening multiple trauma patients in the trauma unit (Lodox x-ray systems (Pty) Ltd, Sandton, Johannesburg, South Africa). ^{1,10} |
| Lung parenchyma | The lung parenchyma is continuous tissue within the lung which comprises a large number of thin-walled alveoli, forming an enormous surface area, which serves to maintain proper gas exchange. |
| Dark Noise | This is a hazy appearance on an image that makes it difficult to see the details. Radiographic noise is inherent in imaging systems; some of the factors affecting radiographic noise fall under the control of radiology technologists. ² |
| Referral pathway | This is a transfer of clinical responsibility to an appropriate professional for management or to establish a clinical diagnosis. ^{6,11} Referral is made when necessary and it is anticipated that patients will be referred to the most appropriate place, without delay. Therefore, in this context referral pathway is an integrated “care map” followed in the process of diagnosing a patient. ¹¹ |
| Resolution | This is the ability to image two separate objects and visually distinguish one from the other. ² |
| Spatial resolution | This is the ability of the imaging system to record small objects of high-subject contrast. ² |

LIST OF ABBREVIATIONS AND ACRONYMS

| Abbreviations/ acronym | Meaning |
|------------------------|--|
| AEC | Automatic Exposure Control |
| AGREE | Appraisal of Guidelines, Research and Evaluation |
| AP | Anterior Posterior |
| ATLS | Advanced Trauma Life Support |
| CAP | Chest Abdomen and pelvis |
| CEO | Chief Executive Officer |
| COPD | Chronic Obstructive Pulmonary Disease |
| CR | Computed Radiography |
| CT | Computed Tomography |
| CTA | Computed Tomography Angiography |
| CXR | Chest x-ray |
| DBP | Diastolic Blood Pressure |
| FAST | Focused Assessment with Sonography for Trauma |
| FDA | Food and Drug Administration |
| GCS | Glasgow Coma Scale |
| GIT | Gastrointestinal Tract |
| kVp | Kilovoltage Peak |
| Lodox | Low Dose x-ray |
| LSSR | Linear Slot Scanning Radiography |
| LUQ | Left Upper Quadrant |
| mAs | Milli-ampere Second |
| MCA | Motorcycle Accident |
| MRI | Magnetic Resonance Imaging |
| msec | Millisecond |
| MVA | Motor Vehicle Accident |
| NGT | Nominal Group Technique |
| OID | Object Image Distance |
| PA | Posterior Anterior |
| PACS | Picture Archiving and Communication System |
| PTB | Pulmonary Tuberculosis |

| | |
|-----|-----------------------------|
| PVA | Pedestrian Vehicle Accident |
| ROI | Region of Interest |
| RUQ | Right Upper Quadrant |
| SA | South Africa |
| SBP | Systolic blood pressure |
| SID | Source Image Distance |
| TDI | Time Domain Integration |
| TDI | Time Domain Integration |
| UP | University of Pretoria |
| WHO | World Health Organization |

CHAPTER 1: INTRODUCTION, BACKGROUND AND ORIENTATION TO THE RESEARCH

1.1 Introduction

Lodox® is an acronym for the words Low-Dose x-rays.¹ The Lodox x-ray system was developed in South Africa (SA) by the De Beers Diamond Company.¹⁰ The Lodox machine is a low-dose digital x-ray imaging system that was initially developed to assist in the detection of diamond smuggling from the mines by employees.¹⁰ Workers were scanned with a low radiation dose using this imaging system daily without side-effects associated with ionising radiation.¹²

Although previous studies have shown that the Lodox x-ray system can produce chest images of superior quality, 30.00% of patients undergoing Lodox imaging are still referred for additional chest x-ray imaging using a conventional x-ray system (see Annexure A).^{10,13}

1.2 Background

The first Lodox x-ray system for medical use was installed at Groote Schuur Hospital in 1999, almost 10 years after its discovery.¹³ The Lodox x-ray system was later approved by the U.S. Food and Drug Administration and the European Union in 2002 and 2004 respectively for use as a screening device for trauma units.¹³ The ability of the Lodox x-ray system to image the total skeleton in the supine position in 13 seconds is making this technology highly suitable for trauma screening compared to a conventional x-ray system.¹⁰ This is especially true where there is a need for multiple images such as in cases of multiple skeletal trauma. Nationally and internationally, the Lodox x-ray system has been suggested as an x-ray modality to replace conventional x-ray systems in trauma imaging when screening for gross pathology is needed.^{1,13-14} Empirical studies undertaken to evaluate the diagnostic quality of the Lodox x-ray system have established the image quality of chest, pelvis, cervical spine, cervicothoracic junction and long bone imaging to effectively detect injuries in patients with multiple trauma.^{10,15-16}

In South Africa, there are twenty eight hospitals that have Lodox x-ray systems installed at the trauma units. During the pilot study, twenty(71.40%) out of twenty eight hospitals responded. A pilot study found that 90.00% of hospitals that responded were referring patients for additional imaging, using conventional x-ray systems, after patients had undergone similar imaging with the Lodox x-ray system (see Annexure A). Among the anatomical regions referred for additional images, 36.11% were requests for chest x-ray imaging and 63.89% were requests for other regions of the body. (see Annexure A).

This research aimed at developing an adult chest referral pathway (imaging protocol) for trauma patients undergoing Lodox imaging at trauma units in South Africa. The diagnostic quality of the

Lodox x-ray system was evaluated by comparing adult chest x-ray images acquired using a Lodox imaging system with those acquired using the chest-dedicated programme of the Lodox x-ray system; with adult chest x-ray images acquired using a conventional x-ray system. Aspects such as the level of size distortion, spatial resolution, contrast resolution and noise (dark noise) of images of both imaging systems were compared. The images of the same patient, 1) aged 18-years and above, 2) acquired within 24 hours using both imaging units (the Lodox x-ray system and the conventional x-ray system) were compared. These images were retrieved from the Picture Archiving and Communication System (PACS) at the radiology departments that participated. In addition, anterior-posterior (AP) images of 'walk-in' patients were acquired using both the chest-dedicated programme of the Lodox x-ray system and a conventional x-ray system for comparison.

1.3 Justification, rationale, and significance

A study conducted on the first installation of Lodox x-ray system in Europe, indicated that additional chest imaging done using a conventional x-ray system was requested after a patient has undergone a full-body Lodox® Statscan (Lodox x-ray systems Pty (Ltd), Sandton, South Africa).¹⁶ This observation suggests a need to investigate the quality of the images acquired using the Lodox x-ray system compared to those acquired using a conventional x-ray system. The Lodox x-ray system has a dedicated chest imaging programme.¹² However, no published research could be found that evaluated the diagnostic potential of images obtained using the adult chest-dedicated Lodox imaging programme. Additionally, through personal communication, the researcher confirmed with the chair of the Trauma Society of South Africa that no referral pathway (imaging protocol) exists for the use of the Lodox x-ray system at trauma units at South African hospitals. Also, no solid evidence confirms that the Lodox x-ray system could produce higher quality images than a conventional x-ray system.¹⁶ If so, it then implies that the Lodox x-ray system could replace imaging using a conventional x-ray system for patients with multiple trauma without compromising diagnosis. Some sources do, however, confirm that Lodox images of the mediastinum, lung and soft tissue were superior to those obtained using a conventional x-ray system.^{13,16}

Conversely, in a study undertaken on paediatric patients where chest images were acquired using the Lodox x-ray system, images showed exposure artefacts, motion artefacts and a lack of broncho-vascular clarity.¹⁷ However, as stated by the authors, this research was undertaken on paediatric patients who are known to be restless during imaging examinations and whose organs have not yet fully developed, which might explain the degraded imaged quality.¹³

Aside from image quality, a further advantage of the Lodox x-ray system is that it emits a 10 times less harmful radiation dose to the patient than a conventional x-ray system.¹ Additionally, the reduction in the radiation dose acquired by staff is approximately 3.00%.¹⁸ Chest imaging was chosen as the focus of this research because globally, 40.00% of general x-ray examinations are chest imaging.¹⁹ Furthermore, chest images represent many densities due to the long grey-scale contrast and long latitude obtained by high-exposure factors.²⁰ Therefore, structures in the chest are representative of all densities in the body varying from bone to tissue and air.²¹ Additionally, the involuntary motion of diaphragms and cardiac structures are comparable to those of the abdomen and other involuntary muscles in the body.²² Consequently, results of this research may be applied to other regional imaging of the body.

The cost of infrastructure for a conventional x-ray room is very high in comparison to that of a Lodox x-ray room.¹³ A Lodox x-ray room does not require unique features whereas a conventional x-ray room has to meet set specifications like the half-value thickness of the wall and have a lead-lined control-panel barrier to be approved by the radiation control directorate.^{19,23}

The use of a Lodox x-ray system could reduce the amount of radiation during routine chest x-ray imaging for the physical evaluation of pre-employment miners. It could also be used during screening for early detection of lung and chronic diseases that require a routine follow-up, such as tuberculosis.²⁴ The radiation dose acquired by staff would also be minimised. The World Health Organization (WHO) and International Atomic Energy Agency (IAEA) calls for radiation dose optimisation in medical imaging to avoid irradiating patients needlessly since radiation is known to be carcinogenic.¹⁹

The significance of this study lies in the development of a pathway (protocol) for imaging of the chest of adult patients at trauma units where a Lodox x-ray system is used. Such a protocol will guide the imaging of trauma patients, minimize the radiation dose to the patients, reduce the scatter radiation for the staff and reduce the radiological cost for the patients. Additionally, there will be a reduced workload due to less use of unnecessary radiological examinations. The protocol will also enhance multidisciplinary collaboration in handling patients, will synchronize and integrate skills towards patient care which will culminate in improved quality service and management of the trauma patients.²⁵⁻²⁷

1.4 Problem statement

The problem that has been addressed in this study is the absence of a referral pathway (imaging protocol) for adult chest imaging at trauma units in SA using a Lodox x-ray system. In this research, imaging protocol refers to step-by-step rules, a set of guidelines or workflow guidelines

that are followed in the management of the patient by streamlining existing patient management challenges to a well-defined chain of activities.⁷ The research gap is that there is no published information about the current situation on the use of the Lodox x-ray system for chest imaging of adult trauma patients since it was originally intended as a screening tool for patients with multiple injuries at trauma units. Furthermore, no research could be found, on the image quality of the adult full-body imaging programme of the Lodox x-ray system and a comparison thereof with related images of structures done with a conventional x-ray system. Also, no comparative research could be found on the diagnostic quality of the dedicated adult chest imaging programme of the Lodox x-ray system when compared to the diagnostic quality of adult chest images acquired using a conventional x-ray system.

So far, studies undertaken on the Lodox x-ray system have focused on its safety and effectiveness in the trauma unit.¹⁸ However, Lodox x-ray systems are increasingly used in emergency units due to their speedy scanning abilities and radiation levels that are lower than those of conventional x-ray systems.¹⁰ Although the Lodox x-ray system has been retained as an ideal modality for the screening of multiple trauma by acquiring full-body imaging in 13 seconds,¹ additional imaging using a conventional x-ray unit continues to be requested on a patient that has undergone Lodox imaging on the same regions.^{1,18} This is what has raised a concern and a need for this research. Noteworthy, retaking of images and requests for additional images may increase stochastic and deterministic effects of radiation on patients.¹⁸

1.5 Research question aim and objectives

A research question is an interrogative statement meant to answer the research problem.²⁸ The research question for this study is:

“How can an adult chest referral pathway (imaging protocol) be developed for trauma patients undergoing Lodox imaging at trauma units?”

The sub-questions that were answered in this research are:

- i. What is the diagnostic similarity between chest images of adult trauma patients acquired using the full-body imaging programme of the Lodox x-ray system compared to those acquired using a conventional x-ray system?
- ii. What is the diagnostic quality of adult chest images acquired using the chest-dedicated imaging programme of the Lodox x-ray system when compared to adult chest images acquired using a conventional x-ray system concerning the level of size distortion, spatial resolution, contrast resolution and image noise (dark noise)?

- iii. What are the referral pathway (imaging protocol) guidelines for patients undergoing imaging using the Lodox x-ray system?

1.5.1 Aim and objectives

The aim of a research study is an expression of how the research problem is solved.²⁹ Differently stated research objectives are clear, concise, concrete, measurable statements written in a declarative form that addresses the aim of the study.²⁸

1.5.2 Aim of the research

This research is aimed at developing an adult chest referral pathway (imaging protocol) for trauma patients undergoing imaging using the Lodox x-ray system. In this context imaging protocol means a set of rules, guidelines or official procedures that guide decision-making on quality and evidence-based care of the patient.^{7,30} According to Lethaby et al. (2001), protocol guidelines are also referred to as clinical pathways.

1.5.3 Objectives of the research

The following objectives have been formulated for phase one and phase two of this research:

In Phase 1, the diagnostic similarity and diagnostic quality of chest images acquired using a Lodox x-ray system and those acquired using a conventional x-ray system were assessed.

The objectives formulated for Phase 1 of the research included:

- i. To assess the diagnostic similarity of chest images of adult trauma patients acquired using a Lodox x-ray system compared to those acquired using a conventional x-ray system.
- ii. To assess the diagnostic quality of adult chest images acquired using a Lodox x-ray system compared to those acquired using a conventional x-ray system in terms of the level of size distortion, spatial resolution, contrast resolution, and image noise.

In Phase 2 of this research, the focus of the research was to gather data for the formulation and verification of referral pathway (imaging protocol) guidelines that could be used for adult patients undergoing chest imaging with a Lodox x-ray system.

The objectives formulated for Phase 2 of the research included:

- i. To formulate referral pathway (imaging protocol) guidelines for an adult patient undergoing chest imaging with a Lodox x-ray system.

- ii. To verify the referral pathway (imaging protocol) guidelines for an adult patient undergoing chest imaging with the Lodox x-ray system.

1.6 Demarcation and scope of the study

The scope of the study was limited to diagnostic imaging of the chest. The focus on chest imaging only was because this is the most common region of the body referred for additional imaging using a conventional x-ray system (see Annexure A). Additionally, the chest is known to have a long range of densities varying from air and soft tissue to bone.^{20,31} Therefore, as mentioned previously, the outcome from this research could be generalized to other regions of the body due to the presence of similar tissue on these body parts. This research was conducted in South Africa only because South Africa has the most Lodox x-ray systems installed in trauma units globally (28 of 121 Lodox x-ray systems).³² Globally chest x-ray imaging is the most performed x-ray examination that often represents the first imaging request in trauma units. The screening of patients for disease using a chest x-ray image is not only to determine the disease of the cardiovascular and respiratory systems but also for systemic illnesses.³³ The chest is also a prerequisite examination commonly requested for occupational health to rule out asymptomatic diseases.²⁴

1.7 Overview of the research methodology and design

Research methodology is a systematic way of solving a problem.³⁴ It is also a study of how research is scientifically implemented by applying various steps in solving a research problem.^{28,34} In this research, the research design provided a roadmap on how the methodology was implemented.³⁵ A descriptive, correlational design was used to examine the relationship between the variables of conventional x-ray systems and Lodox x-ray systems.³⁶ The hospitals from which data were collected were Dr George Mukhari Hospital, Charlotte Maxeke Academic Hospital, Steve Biko Academic Hospital, Pelonomi Academic Hospital, Ngwelezana Hospital, and Groote Schuur Hospital.

1.7.1 Objective 1 and 2 of Phase 1

In Phase 1 (Objective 1), the researcher wanted to establish the similarity between images that were acquired using a Lodox x-ray system and those acquired using a conventional x-ray system. To achieve this objective, the researcher purposively selected 139 images from the Lodox x-ray system and a similar number of images from the conventional x-ray system. For every image obtained from the Lodox x-ray system, an additional image of the same patient, aged 18 years and older was performed within 24 hours using a conventional x-ray system. Consultant

radiologists completed a checklist (see Annexure B) by rating the appearances of images acquired with the Lodox x-ray system and those acquired using a conventional x-ray system. The radiologists had to rate the images by comparing the normal anatomical appearance as well as pathological appearances on the two sets of images. The checklist had three codes that were used in rating the image as well as a section for a comment. These codes were '2' indicating visible or good, '1' indicating partially visible or satisfactory, and '0' indicating poor/invisible. For this objective, the chest images from the Lodox x-ray system were obtained by clipping the chest region from full-body Lodox images while chest images that were obtained from the conventional x-ray system were downloaded from the PACS and used without any adjustment. The ratings of the images by the radiologists were analyzed and compared by a statistician to determine the similarity between the images acquired from the two imaging systems.

In Phase 1 (Objective 2), the researcher wanted to assess the diagnostic quality of the two sets of chest images. For this objective, the Lodox x-ray system images were from the chest-dedicated imaging programme and those acquired using a conventional x-ray system to compare 1) the level of size distortion, 2) spatial resolution, 3) contrast resolution, and 4) image noise. The purpose of this was to link the factors affecting the image quality to the quality of the image produced by the two imaging systems.

To achieve this objective, purposive sampling was used to select 39 images of the Lodox x-ray system and 38 conventional x-ray system images (one image would not open). The images were obtained from walk-in patients that had been referred for chest x-ray imaging. A patient that had been referred for chest x-ray imaging that is usually performed using a conventional x-ray system underwent an additional chest x-ray using a Lodox x-ray system. Radiologists rated these images using a checklist (see Annexure B). To measure the factors affecting the image quality, the researcher developed a quality assurance checklist (see Annexure C). Additionally, these checklists had a space for recording the size distortion, contrast resolution, spatial resolution, and image noise. The measurement of these variables was performed by a researcher assisted by the physicists and radiographers who do quality control tests in the respective hospitals. The ratings of the images by the radiologists were analyzed and compared by a statistician to determine the quality of images obtained from the conventional x-ray system when compared to the images obtained from the Lodox x-ray system. The data obtained on the image quality was represented on a bar graph that compared the conventional x-ray system with the Lodox x-ray system. The data on factors affecting image quality (size distortion, contrast resolution, spatial resolution, and image noise) was also represented on bar graphs and the outcomes were linked to the visibility of various anatomy and pathologies of the images.

1.7.2 Objective 1 and 2 of Phase 2

In Phase 2 (Objectives 1 and 2), the researcher used an e-Delphi method to collect the data in two rounds, 1) the formulation and 2) the verification rounds.³⁷⁻³⁸ This phase entailed the formulation and verification of the referral pathway (imaging protocol) guidelines for adult chest imaging at trauma units. The e-Delphi method is a technique used to survey and collect data electronically on expert opinions in a given participant's specialization.³⁹ It is a multistage approach of data collection in which a subsequent stage is built based on the outcome of the previous stage.⁴⁰

The members of the e-Delphi panel were purposively selected. Trauma specialists (doctors and nurses) who had worked with the Lodox x-ray system, were invited to participate in this research. Altogether 96 participants, who had supplied their contact details during a conference, were invited. The e-Delphi questionnaire (see Annexure J) was sent to participants who were practising as trauma specialists and had worked at a hospital that used a Lodox x-ray system. This questionnaire had a custom validation question that allowed only the participants who had worked with the Lodox x-ray system to participate. The participants were given one month to respond to the questionnaire. After summarising the outcomes on round one of the e-Delphi discussion, a questionnaire was developed and e-mailed to the participants in the second Delphi round (see Annexure L). Once again, the e-Delphi panel was given one month to respond to the questions by ranking the responses or arranging the events in an appropriate order. A reminder email message bearing a link to the questionnaire was sent to all the participants every Monday, Wednesday, and Friday at 12h00. The data analysis consisted of descriptive statistics including mean, mode, median, and standard deviation, which summation of the results. Consensus derived from the mode was expressed in the form of a percentage. The results from the e-Delphi were used to develop referral pathway guidelines from which imaging protocol was derived.

1.8 Overview of the chapters

This thesis has six chapters, outlined as follows.

Chapter 1: The introduction, background, and orientation to the research provide a brief overview of the research by highlighting the research problem, the aim, and objectives, the significance of the research as well as the scope of the research.

Chapter 2: The literature review provides a theoretical grounding for this research by presenting a review of the available literature on the development of an adult chest imaging protocol for Lodox x-ray systems at trauma units.

Chapter 3: The **methodology and design** used for this research are explained and rationalized: including sampling procedures, data collection instruments, and data collection procedures.

Chapter 4: This chapter **presents the results** for Phase 1 of the research for two objectives, Firstly) to assess the diagnostic similarity between chest images of adult trauma patients acquired using the full-body imaging programme of the Lodox x-ray system compared to those acquired using a conventional x-ray system. Secondly to assess the diagnostic quality of adult chest images acquired using the chest-dedicated imaging programme of the Lodox x-ray system compared to those using a conventional x-ray system, about the level of size distortion, spatial resolution, contrast resolution, and image noise. The results are presented using graphs.

Chapter 5: This chapter **presents the results** for Phase 2 for two objectives. Firstly, to formulate referral pathway guidelines for an adult patient undergoing chest imaging using a Lodox x-ray system. Secondly, to verify the referral pathway guidelines for an adult patient undergoing chest imaging using a Lodox x-ray system. The results are presented using graphs.

Chapter 6: In this chapter, the **results for Phase 1 and Phase 2 of this research are discussed** concerning relevant literature. Discussions are linked to the objectives, aim, and topic of the research.

Chapter 7; This chapter includes the proposed **referral pathway (imaging protocol) for adult chest imaging done with Lodox x-ray systems at trauma units, the conclusions and recommendations.**

1.9 Ethical considerations

Principle of Beneficence. A physicist was consulted regarding the radiation dose of the additional image that was obtained from the walk-in patients referred to the radiology department. The radiation dose was minimal and could not cause any side effects (see Annexure D). The researcher confirmed that there was no retake of the images on the same participant to minimize the radiation dose. Ethics approval was sought from the University of Pretoria, Research Ethics Committee (35/2018) (see Annexure K) after the protocol was approved by the School of Healthcare Sciences. The respective hospital manager and each Chief Executive Officer were also contacted to approve this research (See Annexure E). Before issuing the ethics approval, the ethics committees of various hospitals considered the protocol to confirm the benefits of the research. After the research was approved, data collection commenced. The above steps were taken to ensure that there was no harm to the patients.

Principle of respect for persons: Participants were informed verbally and in writing about the amount of ionizing radiation involved in this research (see Annexure D). Upon agreeing to participate in this research, participants completed an informed consent form (see Annexure H). Participation was voluntary and participants could withdraw at any time without giving a reason or being penalized.

Principle of justice: The researcher selected participants meeting the inclusion criteria fairly and did not select participants from a particular tribe, gender, religion, or citizenship.

Privacy: Details of the hospital were represented using a code and names of the participants were coded to preserve anonymity. No publication will reveal any details of participants or hospital information.²⁸

CHAPTER 2: LITERATURE REVIEW

2.1 Introduction

This literature review gives a theoretical overview of 1) the structural features of the Lodox and conventional x-ray systems; and 2) the diagnostic efficacy of the Lodox and conventional x-ray systems. The factors impacting image quality inherent to the Lodox and conventional x-ray systems are also discussed. Literature searches were conducted from various sources, but mostly from the University of Pretoria Library and the Lodox Company databases. Some of these sources included Google Scholar, World Catalogue Discovery, University of Pretoria institutional repository, e-books, and printed books.⁴¹

2.2 Theoretical framework

Currently, the use of the Lodox x-ray system has been limited to emergency units as a screening tool for trauma patients. This use is motivated by the low radiation dose of Lodox imaging and the time saved when doing whole body Lodox scanning.¹ Noteworthy is that the literature confirms that the Lodox x-ray system can produce high-quality images comparable to those produced using conventional x-ray systems.⁴² According to a pilot study conducted in 2009,⁴² Lodox x-ray systems gave good diagnostic accuracy for paediatric chest images. The Lodox Company confirmed that, when scanning, the Lodox x-ray system uses Time Domain Integration (TDI) and Linear Slot Scanning Radiography (LSSR) technology which has resulted in images comparable to those produced using a conventional x-ray system in the detection of thoracic-, pulmonary-, mediastinal- and pelvic injuries.¹ On the other hand, conventional x-ray systems do not image a patient to obtain images but use a once-off exposure with a limited time as accurate as 0.001 seconds with a 1-msec delay.⁴³

In a comparative study, the performance of the Lodox x-ray system was equated to that of conventional x-ray systems by 42.9% (67/156 images) for specific pathologies and 12.8% (20/156 images) for additional diagnostic information.¹⁸ The Lodox x-ray system emits 10 times less harmful radiation dose to the patient compared to conventional x-ray systems and has a 0.12mGy of entrance radiation dose.¹ According to the Lodox Company (2018), the scatter is minimized by the Lodox beam and detector configuration. During Lodox scanning a fan beam of one millimetre is used to control the divergence of the beam along the length of the patient.^{1,43} In contrast, conventional x-ray systems emit cone-beam radiation which can be collimated to include the whole part on which the beam is centred. In short, this means that while conventional x-ray

systems use the inverse square law to determine the number (quantity) of x-ray photons that strike the object², the Lodox beam and detector technology assists in producing a full-body image with a minimum radiation dose while still obtaining high diagnostic quality images that are comparable to those using conventional x-ray systems.⁴⁴ The Lodox x-ray system thus produces a full-body image using a third of the x-radiation needed for an equivalent image obtained using a conventional x-ray system.¹³

2.3 Diagnostic efficacy of the Lodox and conventional x-ray systems

Research on the Lodox x-ray system has focused on radiation safety and the effectiveness of this imaging system to produce a quality image.^{3,10,16} In this research, efficacy refers to the ability of the imaging system to yield the intended results^{6,16} and suggested that imaging using the Lodox x-ray system at the emergency unit can replace imaging using conventional x-ray systems to obtain anteroposterior (AP) projections of the chest and pelvic regions with no post-trauma diagnosis missed. This study used randomized convenience sampling to include 245 adult (≥ 16 years) participants.

Diagnostic accuracy refers to the correctness of the organs as represented on a radiographic image⁴⁵. The Lodox showed an overall sensitivity of 62.00% and specificity of 99.00% diagnostic accuracy.¹⁸ A prospective randomized research model was used to validate preliminary findings.¹⁶ Although the accuracy of the conventional x-ray system was defined, this research also used literature to determine the sensitivity of the conventional x-ray systems and Lodox x-ray system chest images.¹⁶

A prospective study conducted to compare the quality of chest images acquired using full-body Lodox images compared to erect chest images of paediatric patients acquired using conventional x-ray systems did not conclude that the Lodox x-ray system has superior or inferior image quality when the images were compared.⁴² Thirty-three (33) erect chest images were obtained for children aged between 0.9 months and 10.4 years.⁴² The results showed exposure artefacts, motion artefacts, and a lack of clarity of broncho-vascular markings.⁴² These could be associated with exposure fluctuations or motion artefacts, changes in Source-Image-Distance (SID), Object-Image-Distance (OID), and a possibility of respiratory command not having been used resulting in magnification.⁴⁶⁻⁴⁸ This would imply a low spatial resolution for the Lodox x-ray system compared to the conventional x-ray systems.²³ For the images acquired using the Lodox x-ray system, 27.00% showed exposure artefacts manifesting as longitudinally oriented light and dark bands. These were referred to as Chevron Exposure Artefacts (CEA).⁴² Additionally, in a comparison

between the images of Lodox x-ray systems and conventional x-rays systems, the three major airways (the left and right bronchi and the trachea) were clearly visible on the Lodox images.⁴²

Lodox imaging has also been suggested for use in the diagnosis of pediatric pulmonary tuberculosis in which airway narrowing is easily noticeable and evident.⁴² However, the diagnostic quality of pediatric pathology and anatomical structures appeared poor except those of the mediastinal structures and the three airways.⁴² Movement or exposure artefacts were not seen during a pilot study on pediatric AP chest images for polytrauma patients.²¹ Noteworthy is that none of these studies that compared images of the Lodox x-ray system compared to conventional x-ray systems includes detail on the techniques for patient positioning, part positioning and the technical factors used to obtain the images.^{10,13,42}

The outcome of the research studies mentioned previously intrigued the researcher to embark on an investigation to determine how factors such as size distortion, spatial resolution, contrast resolution, and dark noise might affect the image quality for both systems as those were not previously investigated. Hence, the researcher adopted the radiographic technique for the radiography of the chest as recommended.^{47,49} with the patient positioned in an erect position with the chin raised, the hands-on lower hips, palms out, elbows flexed, midsagittal plane aligned with the middle of the image receptor, coronal plane parallel to image receptor and chest part in contact with image receptor. Also, the scapulae were cleared from the lung fields by pushing the shoulders to the front while the palms of the hands are inverted from their true anatomical position.⁴⁷ The patients were asked to take a deep breath and not to move until the exposure was completed. The radiation exposure was made on second maximum inspiration.⁴⁹ The researcher used a recommended SID for chest radiography for both imaging systems.⁴⁷ The images were then presented to selected radiologists for reporting with the request to rate the anatomical and pathological appearance of various structures on the images.

2.4 Radiological features on an adult chest image

The section below presents information about the anatomical structures and pathological variances for inclusion in the checklist used by the radiologists during reporting.

2.4.1 Visualisation of the normal anatomy of the trachea, bronchi, vascular pattern, and some variances

The trachea is a midline structure of which the anterior and lateral walls are composed of cartilaginous rings with a membranous posterior wall.⁵⁰ The trachea divides into the left and right main bronchi at the carina, which is approximately at the level of the fifth thoracic vertebra. The

main bronchi enter the hila of the lungs and branches within the lungs to form the bronchial tree.⁵¹ The right main bronchus assumes a more vertical position only in adolescents with a length of approximately 2.5 cm.⁵⁰ This bronchus is also wider, shorter, and more vertical than the left bronchus and is, therefore, more likely to become obstructed by an inhaled foreign body.⁵² After entering the right lung at the hilum, it divides into three branches, one to each lobe.⁵⁰ Each branch is then subdivided into numerous smaller branches.⁵¹ The left bronchus measure about 5 cm long and is narrower than the right.⁵³ After entering the lung at the hilum, it divides into two branches, one to each lobe.⁵¹ Each branch then subdivides into progressively smaller airways within the lung substance.⁵³ The lobar bronchi branch into segmental bronchi in both the right and left lobes.⁵² Segmental bronchi are visible on chest radiographs only when they are seen end-on as ring shadows or when they are abnormally thickened.⁵⁰ The most commonly seen segmental bronchi on a chest image are the anterior segmental bronchi of the upper lobes which are seen as ring shadows adjacent to the segmental pulmonary artery.⁵⁰

The pulmonary trunk or main pulmonary artery originates in the mediastinum at the pulmonary valve and extends cranially and slightly to the left for 4-5 cm before bifurcating within the pericardium into the left and right pulmonary arteries.⁵⁰ The left pulmonary artery continues until it reaches the hilum, where it arches over the left main bronchus and gives off the left upper lobe and interlobar arteries from which segmental and subsegmental branches arise. The left interlobar artery lies posterolateral to the upper lobe bronchus. The right pulmonary artery courses behind the ascending aorta before dividing in front of the right main bronchus into the ascending (truncus anterior) and descending (interlobar) branches. Dilation of the interlobar pulmonary artery may result from increased pressure, for example, pulmonary arterial hypertension. Increased pressure may be caused by increased flow, for example, left-to-right shunts or aneurysm formation.⁵⁰ The anatomic structures rendering the hila visible on images are mainly the pulmonary arteries and veins, with lesser contributions from the bronchial walls, surrounding connective tissue, and lymph nodes.^{50,51}

On radiographic images, the trachea is visible centrally branching into further subdivisions of bronchi supplying each of the lobes.⁵⁴ Changes of the normal position of the trachea on an x-ray image may indicate a push or pull from either of the two sides of the chest.⁵⁴ Causes of tracheal deviation from the midline may be a pleural effusion or a tension pneumothorax (pushover from the side where volume is gained) and lobar collapse (pull over towards the side where volume is lost).⁵⁵ Noteworthy is that incorrectly positioned patients during imaging (slight rotation to the left or right) may mimic a deviation of the trachea from the midline.⁵⁵ A bronchocele/pneumatocele may also be identified after blunt trauma (also known as blunt-force

trauma) as a consequence of compression/decompression of the chest causing rupture of the small airways.⁵⁶ This is identified on an image as a round radiolucent area.⁵⁶

On radiographic images, the pulmonary artery and pulmonary veins appear white and characteristically branch medially and gradually reduce their size from the hila centrally to the peripheral margins of the lungs.⁵⁷⁻⁵⁸ The main pulmonary artery segment is usually concave or flat.⁵⁹ The ascending aorta should not project further to the right than the right heart border.⁵⁹ The aortic knob is normally <35 mm (measured from the edge of the air-filled trachea) and will normally push the trachea slightly to the right.⁵⁹ Due to gravitation pull, the blood vessels at the base of the lung are larger than those at the upper part of the lung.⁵⁷

2.4.2 Visualisation of lung parenchyma and some pathological variances

The lung parenchyma constitutes the functional part of the lung which can either be an interstitial matter or the airspace matter in the lung.⁵⁷ The lung's interstitial matter consists of connective tissue, lymphatics, blood vessels, and bronchi.^{53,57} These are the structures that surround and support the airspaces.⁵⁷ Diseases that affect the lung parenchyma are airspace diseases and interstitial diseases which are visible on an x-ray image.⁵⁷

2.4.2.1. Interstitial lung disease

Interstitial lung disease is seen on an x-ray image as discrete 'particles' that develop in the interstitial network of the lung.⁵⁷ Airspace diseases are characterized by opacities in the lung, which can be described as fluffy, cloudlike, or hazy in appearance. The fluffy opacities are confluent with indistinct margins visible through the entire lung.^{57,58} A brief discussion on the radiographic appearance of interstitial opacities, pulmonary contusion, bullae, and nodules on a conventional chest image, follows below.

Interstitial changes (also called interstitial opacities) develop in the abundant interstitial network of the lung.⁵⁷ Interstitial diseases are known to have an infiltrative disease pattern on conventional chest x-ray images, as they are produced by processes that thicken and inflame the interstitial compartments of the lung.⁵⁷ The accumulation of water, blood, tumour, cells, fibrous tissue, or any combination of these may lead to the interstitial spaces being visible on an x-ray image.⁵⁹ The margins caused by interstitial lung disease are sharper than those caused by airspace disease.⁵⁷ Hence, the radiographic patterns of interstitial disease are divided into reticular/ground-glass, reticulonodular, nodular, and linear patterns on an x-ray image.^{57,59} The extent of the interstitial pattern depends on the nature of the underlying disease and the interstitial tissue that is affected.⁵⁹

Pulmonary contusion or 'lung bruise' is the most common parenchymal lung injury seen in blunt thoracic trauma with a prevalence of 30–75% of cases and is the most common cause of pulmonary opacity on a chest x-ray (CXR).^{56,60} Lung contusion commonly results as a complication of traumatic injury and presents as hemorrhagic deposits at the site of trauma; hence, pulmonary contusions are often visible on an image at the periphery of the lung and the site of highest impact.⁵⁷ Pulmonary contusion is suggestive of damage to the capillaries, alveolar membrane, and interstitial space. Overall, the mortality rate for lung contusion varies from 14% to 40% of patients depending on the severity of the injury.⁵⁶ Radiographically, pulmonary contusion presents as focal or multifocal areas of confluent 'ground-glass' opacities indicative of interstitial injury.⁵⁶ Pulmonary contusions are radiographically visible after 6 hours and resolve within 72 hours. Noteworthy is that pulmonary contusion may present with a similar appearance as airspace diseases like pneumonia or aspiration.⁵⁶⁻⁵⁷ Air bronchograms are mostly absent in trauma cases with pulmonary contusion as blood is filling the air spaces.⁵⁷

Bullae (alias blebs) are air-filled spaces greater than 1 cm in size which is usually located in the subpleural or intraparenchymal areas.⁶⁰ They have a thin wall (<1 mm) that is frequently and partially visible on conventional images but is well-shown on CT images.⁶¹ Bullae result from progressive destruction of the alveoli wall causing large air-filled spaces called bullae.⁶² They appear as round black areas in the lung surrounded by fine curvilinear shadows and often distort the surrounding pulmonary vasculature.⁶¹ The presence of bullae on conventional images is often confirmed by the absence of lung markings in these air spaces.⁵⁷ These large air-filled spaces then compress the lung on the affected side to the extent that the lung seems to have 'disappeared' (vanishing lung syndrome).^{57,60} These large, radiolucent, air-filled sacs are found predominantly at the apices or the bases and may become so large that they cause respiratory insufficiency by compressing the remaining part of the normal lung.⁶² Bullae may be infected presenting as cystic masses with air-fluid levels.⁶⁰ The presence of bullae often confirms emphysema or Chronic Obstructive Pulmonary Disease (COPD).⁶²

Nodules are solitary spherical/round opacities of varying sizes that present interstitially.^{58,59} On an x-ray image, nodules present as areas of whiteness within the lung field.^{59,61} Nodules are sometimes also called coin lesions to describe a well-defined nodular type of lesion.⁶¹ In contrast to airspace nodules, interstitial nodules are homogeneous and sharply defined as their margins are surrounded by aerated sections of the lung.⁵⁹ These interstitial nodular opacities can be subdivided based on sizes of from 2 to 7 mm (micro-nodules) up to as big as 30 mm.^{59,61}

2.4.2.2 Airspace (alveolar) disease

The appearance of airspace disease on conventional x-ray images is briefly discussed below. Airspace diseases are mainly confirmed by ground-glass appearances and/or air bronchograms.

Ground-glass opacities are seen as a fine reticular pattern. This appearance is caused by the thickening of the interstitial parenchyma of the lung to produce a fine network of lines with intervening lucent spaces of 1 to 2 mm in diameter. Ground-glass opacities can also confirm airspace disease when the alveolar material incompletely fills the airspaces.⁵⁹ ground-glass opacities occur when the ratio of air to that of tissue changes due to either a reduction in the amount of alveolar air or an increase in the thickness of the alveolar walls.⁶¹ The appearance of ground-glass opacities is a sign of interstitial pulmonary oedema, inflammation, or interstitial pneumonitis.⁵⁶⁻⁵⁷ Hence, these opacities can appear in a wide range of diseases such as airway diseases, interstitial lung disease, or vascular disease.⁶¹

Bronchi inside the lungs are normally not visible because their walls are thin and are surrounded by air.⁵⁷ Air bronchograms represent the branching (linear/tubular lucency) of a bronchus or bronchiole passing through an airless space in the lung parenchyma.⁶⁰ When fluid or soft tissue replaces the air that surrounds the bronchus the air inside of the bronchus becomes visible as a series of black, branching tubular structures which represent an air bronchogram.⁵⁷ The air space may also be filled by exudate or blood causing the air-filled bronchi and bronchioles to be even more visible.⁵⁷ The air-space-filled opacities in the lung can be described as fluffy, cloudlike, and hazy.⁵⁷ The opacities tend to be confluent, merging into one another.⁵⁹ The margins of airspace disease are fuzzy and indistinct and air bronchograms or the silhouette sign may be present.⁵⁷ An air bronchogram indicates that the underlying opacity must be parenchymal rather than pleural or mediastinal in location although neoplastic diseases like cancer may present with this feature.^{57,60}

2.4.3 Visualisation of the pleura and some pathological variances

In this section, the visualization of the pleura and the abnormal pathologic variances (pneumothorax, pleural effusion, and surgical emphysema) are discussed.

Pneumothorax is the presence of air in the pleural cavity that may result in a partial or complete collapse of the lung.⁵⁸ Pneumothorax may be due to the rupture of a subpleural bulla, either as a complication of emphysema or after a traumatic event like stabbing, gunshots, or fractured ribs.⁵⁹⁻⁶⁰ Iatrogenic causes may include puncture of the lung after biopsy or the introduction of a chest tube for thoracentesis.^{52,60} Despite the cause of a pneumothorax, the increased air in the

pleural cavity results in compression of the lung causing it to collapse.⁵⁷ The collapse may cause sudden, severe chest pain and dyspnoea.⁶² The increase in pressure in the thoracic cavity on the side of the pneumothorax (volume gain) then causes the cardiac and mediastinal structures to shift from the midline away from the side of the pneumothorax.⁵⁷ This shift of the midline structures then leads to compromised cardiac output due to the changed pressure in the thoracic cavity and the consequent decreases venous return to the heart.⁶²

Conventional CXR images are performed in a preferred erect position to show pneumothorax.⁵⁶ In addition to routine full-inspiration images, a posterior-anterior (PA) image or an AP image should be obtained with the lung in full expiration to allow identification of small pneumothoraxes.^{47,59} This manoeuvre causes the lung to decrease in volume and become relatively denser whereas the volume of air in the pleural space remains constant and is easier to detect.⁵⁷

A pneumothorax appears radiographically as a hyperlucent area in which all pulmonary markings are absent and often with a mediastinal shift of the heart and trachea to the affected side.⁵⁷ The radiographic hallmark to confirm a pneumothorax is showing the visceral pleural line which is outlined centrally by air within the lung and peripherally by air within the pleural space. Very small pneumothoraxes may be identifiable on lateral decubitus images of the chest which are captured with the affected side up.⁵⁷ In this position, air rising to the highest point in the hemithorax is more clearly visible over the lateral chest wall than on erect views in which a small amount of air in the apical region may be obscured by overlying bony densities.⁴⁷ Whenever an expiration image is performed, a complete collapse of the ipsilateral lung and depression of the hemidiaphragm is seen better.⁵⁹ Although this is not recommended in cases where the patient is unable to stand (e.g. during trauma imaging), an image is performed in a supine position where a pneumothorax may present on the image with the deep sulcus sign (a deep, lucent costophrenic sulcus).⁶⁰

Pleural effusion is the accumulation of fluid within the pleural cavity.⁵² The accumulation of fluid in the pleural space is a nonspecific finding that may be caused by a wide variety of pathological processes.⁶² The most common causes of pleural effusion are congestive heart failure, pulmonary embolism, infection (especially tuberculosis), pleurisy, neoplastic disease, and connective tissue disorders.⁶² Pleural effusion can also be a result of abdominal diseases, such as recent surgery, ascites, subphrenic abscess, and pancreatitis.^{58,62}

The costophrenic angles should be visible on a chest image forming a well-defined acute angle.⁴⁷ Loss of this acute angle may suggest the presence of fluid or consolidation in the area.⁶² In other words, the costophrenic angles should be visible on a chest image forming a well-defined acute

angle.⁴⁷ Loss of this acute angle may suggest the presence of fluid or consolidation in the area.⁶² The earliest radiographic finding for pleural effusion is the blunting of the costophrenic angle along with an upward concave border of the fluid level (or meniscus) on a PA erect chest image.⁵⁸ Lung hyperinflation, due to diaphragmatic flattening, fluid (hydrothorax), or blood (haemothorax) can accumulate in the pleural space, causing an area of increased opacity or a combination of both pneumothorax and fluid (hydropneumothorax).⁶³ This leads to blunting of the costophrenic angle.⁵⁴ Noteworthy is that as much as 400 ml of pleural fluid may accumulate and still not show blunting of the costophrenic angles on an erect PA/AP image of the chest.

Small pleural effusions may be difficult to distinguish from pleural thickening and fibrosis, which results from previous pleural inflammation and appears radiographically as a soft tissue density along the lateral chest wall.⁶² Because the costophrenic angles are deeper posteriorly than laterally, small pleural effusions are best seen on the routine lateral projection posteriorly.⁵⁹ The diagnosis of a small pleural effusion is best made on images performed with a horizontal x-ray beam and the patient in a lateral decubitus position with the affected side down.⁴⁷ With the placement of the patient in a slight lateral Trendelenburg position, as little as 5 ml of pleural fluid can be seen as a layer of linear opacification along the dependent chest walls.⁶²

Larger amounts of pleural fluid produce a homogeneous opaque density that may obscure the diaphragm and adjacent borders of the heart.⁶² Massive effusions may compress the adjacent lung and even displace the heart and mediastinum to the opposite side.⁶²

A pleural fluid collection that has become fixed by inflammatory or fibrosis may mimic a solid mass.⁶² In patients with congestive heart failure, an effusion may develop in an interlobar fissure to produce a round or oval density resembling a solitary pulmonary nodule.^{58,62} CT imaging can show small pericardial effusions, although pericardial ultrasonography is the first diagnostic imaging modality of choice.⁵⁷

Surgical/subcutaneous emphysema is caused by the extension of air into the soft tissues of the neck, chest, and abdominal walls causing a comb-like striated appearance.⁵⁷ This may be caused by penetrating or blunt injuries that disrupt the lung and parietal pleura and force air into the tissues of the chest wall.⁵⁸ Radiographically, this may be shown as streaks and bubbles of subcutaneous air in soft tissues along lateral borders of the thorax with broad lucency outlining muscle bundles that overly the anterior chest wall.⁶²

2.4.4 Visualisation of the mediastinal structures and some pathological variances

The appearance of mediastinal injuries, pneumomediastinum, and the cardiac- and aorta outlines are discussed below.

On a supine or erect CXR image, mediastinal injuries such as the outline of the mediastinum and the heart should be seen.⁵⁸ The right superior mediastinal border is usually straight or slightly curved as it passes downwards to merge with the right heart border.⁵⁸ Changes in the mediastinal to the chest width ratio >0.25 , an irregular aortic knob, a blurred aortic contour, and a trachea shift to the patient's right are all indicative signs of mediastinal injury.⁵⁶

Pneumomediastinum is also known as mediastinal emphysema.⁶² High-energy deceleration during a car accident may result in a hematoma of the lower neck and central chest areas.⁵⁶ The presence of such a hematoma can be shown on the CTX as a 'seatbelt sign'.⁵⁶ This sign is suggestive of cervical blood vessel injuries (carotid artery injuries).⁵⁶ Air within the mediastinal space may appear spontaneously or it may result from chest trauma, perforation of the oesophagus or tracheobronchial tree, or the spread of air along fascial planes in the neck, peritoneal cavity, or retroperitoneal space.⁵⁶ Spontaneous pneumo-mediastinum usually results from a sudden rise in interalveolar pressure (for example, during severe coughing, vomiting, or any form of straining) that causes alveolar rupture and the dissection of air along blood vessels in the interstitial space to the hilum and mediastinum.⁵⁶ Air may also extend peripherally and rupture into the pleural space causing an associated pneumothorax.⁵⁶ Chest radiographs may also show air outlining the pulmonary arterial trunk and aorta and dissecting into the soft tissue of the neck.⁵⁶

On PA chest images, air causes lateral displacement of the mediastinal pleura which appears as a long linear opacity that runs parallel to the heart border but is separated from it by the air (broncho-vascular sheath).⁵⁶ On lateral projections of the chest, the air is typically seen to have collected behind the sternum extending in streaks downward and anterior to the heart.⁵⁶

On an ideal chest image, the position of the heart is variable and thus also cardiac and aorta outlines. On average, one-third of the heart lies to the right of the midline creating a silhouette of the heart (also called the silhouette sign).⁵⁸ Pneumopericardium is a sign of pericardial injury.⁵⁶ The tear in the pericardium can be detected by irregular margins of the pericardium, discontinuity, and interposition of fat or lung parenchyma.⁵⁶ The tear in the pericardium can be complicated by diaphragmatic rupture and cardiac herniation resulting in severe cardiac failure.⁵⁶

Conventional chest imaging may show air in the pericardium (pneumopericardium)⁵⁶ but can also show foreign bodies, an enlarged heart, mediastinal widening due to mediastinal as well as concomitant lung injuries.⁵⁶ An indistinct aortic contour on a chest image is always suggestive of aortic injury.⁵⁶

2.4.5 Visualisation of the thoracic cage and associated pathologies

In this section, the researcher focuses on the radiographic presentation of the soft tissues and bony structures of the thoracic cage (mammary gland, ribs, clavicle, thoracic spine, and diaphragm). The assessment of the soft tissue is important as swelling or a change in the appearance of the soft tissue may indicate an underlying injury in the thorax.⁶¹

Soft tissues of the thoracic wall and the mammary gland consist mainly of the skin, subcutaneous fat, and muscles.⁵⁰ Soft tissues that are lateral to the bony thorax should be smooth, symmetric, and homogeneous in density on a conventional chest image⁵⁹. The breast shadows should be visible and homogenous bilaterally.⁵⁹ One should be careful not to mistake the pectoral muscles, breasts, or plaits of hair for pulmonary opacities on a conventional chest image^{56,58}. Also, skin lumps or nipples may mimic pulmonary nodules;^{58,62} hence, it is important to check for the presence of both nipples if a unilateral mastectomy was not done. Other skin lesions that should not be mistaken for pulmonary nodules on conventional chest images are moles, nevi, warts, neurofibromas, and accessory nipples.⁵⁹

When assessing a conventional chest image for fractures of ribs and/or clavicle, the twelve pairs of symmetrical ribs should be seen with the upper ribs having smooth superior and inferior cortical margins while the middle and lower ribs have flanged inferior cortices where the intercostal neurovascular bundles run through.⁵² Cervical ribs are identified in approximately 2% of patients and may be associated with symptoms of thoracic outlet syndrome.⁵⁶ Costal cartilage calcification is seen in most adults and increases in prevalence with advancing age. These can add multiple shadows overlying other anatomy on the PA/AP chest image.⁵⁷

Rib fractures are the most common skeletal injury in blunt chest trauma patients.⁵⁶ These fractures present on a conventional chest image as a disrupted cortical outline of the bone.⁵⁸ Additionally, the density of the ribs must be the same otherwise there might be a pathological process present.^{58,61} Fractures of the first two ribs are associated with injury of the brachial plexus or the subclavian blood vessels as they are situated close to the upper two ribs. Noteworthy is that the rate of complications, such as pneumothorax, haemothorax, pulmonary contusion, flail chest, pneumonia, and atelectasis, rises with the number of fractured ribs.⁵⁶ On the other hand,

fractures of the lower three ribs are associated with the trauma of the liver, spleen, kidneys, and lungs.⁵⁶ Therefore, rib fractures might be indicators of coexisting thoracic or abdominal trauma.⁵⁶

Conventional chest imaging is the standard initial imaging test for disclosing rib fractures in patients after minor trauma.⁵⁶ However, only 50% of rib fractures can be detected with conventional chest imaging.⁵⁶ Clavicle fractures account for 2.6–5% of all fractures of the thoracic cavity.⁵⁶ A clavicle fracture is indicative that a large amount of energy has been transmitted to the chest wall during a traumatic incident and thus deeper structures in the thorax might be injured.⁵⁶

Fractures of the thoracolumbar spine occur in up to 18% of blunt trauma patients.⁵⁶ Between 16% to 30% of all spine fractures are thoracic spine fractures and about 50% of patients present with associated focal neurologic deficit.⁵⁶ Spinal cord injury with the neurologic deficit has been reported to present in every 13th patient with polytrauma of which over 50% suffered a spinal cord lesion.⁵⁶ Possible symptoms of injury to the spinal cord are the loss of motor or sensory function and more severe failure in the regulation of bowel, bladder, blood pressure, heart rate, or breathing.⁵⁶

Radiographically, vertebral injuries may be identified by assessing the alignment of the vertebra, spinous process, vertebral body height, and disc space height on conventional chest images.⁶⁴ The spinous processes should lie in a straight line and be equidistant from the lateral aspect of the vertebral column.⁶⁴ The loss of intervertebral and vertebral body height is indicative of compression fracture.^{57,64} The thoracic vertebral bodies should be vertically aligned, with visualization of the endplates, pedicles, and spinous processes.^{59,61} Bilateral anterior and posterior cortical margins of the thoracic vertebral bodies should be aligned with no disruption.⁵⁹

The diaphragm is a dome-shaped muscle that separates the thorax and abdomen and assists in breathing.⁵³ Radiologically, the upper surfaces of the diaphragm should be visible forming sharp costophrenic angles on the lateral sides of a chest image.⁵⁸ The dome of the right hemidiaphragm is at the level of the anterior end of the sixth rib with the right hemidiaphragm up to 2.5 cm higher than the left.^{58,61} The right hemidiaphragm overlies the liver, and the left hemidiaphragm overlies the stomach and spleen.⁵² The most informative sign of diaphragmatic rupture seen on chest images is the visualization of abdominal viscera above the diaphragm (with or without a focal constriction of herniated viscera as they pass through the violated diaphragm—the collar sign).⁵⁶ Unexplained elevation of a hemidiaphragm of 6 cm is correlated with injury to that hemidiaphragm.⁵⁶ The stomach appears below the left hemidiaphragm but is only identifiable if there is air present in the stomach (gastric bubble).⁵³ An elevated diaphragm can also signify effusion, lobar atelectasis, and diaphragmatic paralysis.⁶⁵ Noteworthy is that an effusion and

infiltrates may hide parts of the diaphragm presenting radiologically as blunting of the costophrenic angles.⁶⁵

Extra-luminal (outside the bowel)⁵⁷ air may be recognized beneath the diaphragm⁶² on an erect chest image. Free air in the abdominal cavity will usually present under the diaphragm as a crescentic lucency under the surface of one or both hemidiaphragm.⁵⁷ In the supine position, a small amount of free air will not show on the chest image.⁵⁷ Free air is more easily seen beneath the right hemidiaphragm over the discrete density of the liver than beneath the left hemidiaphragm due to the presence of the gastric bubble beneath the left hemidiaphragm which may confuse the reader.⁵⁷

2.5 Factors impacting image quality

Radiographic image quality is a descriptive term that compares the degree of representation of an object and the intended outcomes displayed on an image.^{2,66} Differently stated it is the exactness of representation of the patient's anatomy on the image.² A need for high-quality images is essential to obtain an accurate diagnosis.² High radiographic image quality can only be obtained through careful consideration by a radiographer of image receptor factors, geometric factors, and subject factors.² This research focuses on geometric factors and image receptor factors including size distortion, spatial resolution, contrast resolution, and dark noise of an image. These factors are inherent in the imaging system and are primary determinants of radiographic image quality.^{2,67} Since the quality of the images was compared in this study, it was important to consider the main factors affecting image quality.⁶⁸ The factors influencing image quality related to this study are discussed below.

2.5.1 Size distortion

Distortion is the unequal magnification of different parts of an object.⁶⁹ Distortion is caused by object thickness, object position, and object shape.⁶⁹ The thicker the object is the more the distortion.^{2,69} Irregular anatomy contributes to increased distortion due to varying the object plane and the image plane.⁶⁹ Distortion is less if the region of interest is positioned at the centre of the x-ray beam during an investigation.⁶⁹ Hence, distortion is one of the causes of radiographic image misrepresentation as it interferes with the image detail and the subsequent diagnosis.^{67,70}

Image quality is improved by minimizing the OID and increasing the SID which reduces the size distortion.² Size distortion can be determined by object thickness, position, and shape.²³ Generally, thin objects are less distorted.² During conventional x-ray imaging, objects are distorted more if the object plane and image plane are not parallel.²³ Often foreshortening and

elongation is a common form of distortion on images and is caused by an increase of angle between the object plane and image plane.⁶⁸ Therefore, the positioning of an object before imaging is paramount to ensure good image quality.²³ Important to note is that orthopaedic surgeons use images to accurately measure the prosthesis sizes before an operation is performed⁷¹ and other surgeons use undistorted images in scaling the size of an image to the real size of the anatomical part when performing operations. Therefore, size distortion should be limited to the minimum to ensure that the true size of the prosthesis or the body is reflected to minimize measurement errors.⁷¹

The geometry of the x-ray beam can also contribute to the distortion of the anatomy presented on the image. Although the Lodox x-ray system has a fan x-ray beam in contrast to the cone-beam x-ray in conventional x-ray systems, distortion is not excluded on images of both systems.⁷¹ However, it is important to minimize the non-linear distortion as much as possible. The Lodox x-ray system consists of x-ray detectors and an x-ray source mounted on the opposite sides of a C-arm.⁷² The C-arm moves linearly to image a patient with a collimated fan x-ray beam producing images that are accurate in the scanning direction but distorted in the beamwidth direction.¹² This fan x-ray beam that is used in the Lodox x-ray machine causes only the areas towards the edges of the image to be distorted due to non-linear distortion.^{71,73} The cone x-ray beam of a conventional x-ray system contributes to magnification on all the sides of the object compared to the Lodox x-ray system.¹⁰

Focal-spot size can contribute to minimizing magnification. Most conventional machines use a controlled rectangular focal spot and not a point source of x-radiation (0.1 mm to 1.5 mm).^{4,5,23} However, the inherent magnification between Lodox x-ray systems and conventional x-ray systems has not yet been quantified.

To inform the significance of size distortion/magnification on the image quality of the Lodox x-ray system compared to conventional x-ray systems, this research investigated this relationship using the SID prescribed for CXR for conventional x-ray systems and Lodox x-ray systems.⁴⁷ The SID for conventional imaging systems was 180 cm and 130 cm (maximum distance) for the Lodox x-ray systems.¹

2.5.2 Spatial resolution

Spatial resolution is also referred to as image detail.⁷⁴ Differently stated image detail refers to the ability of a system to show sharp outlines for the anatomy shown on the image.^{2,74} It should thus accurately record small objects that have high-subject contrast.² The ability of the imaging system to record a small object of high-subject contrast is quantified by the 'spatial frequency and

modular transfer function' which is determined by the image receptor, motion, and geometric blur.^{4,23} Spatial resolution is expressed as the number of line pairs per millimetre (lp/mm) consisting of lead lines separated by interspaces of equal sizes.² The measurement of spatial frequency relates to the number of line pairs in a determined length expressed as line pairs per millimetre (lp/mm) or line pairs per centimetre (lp/cm).² Spatial resolution is determined by the geometry of the focal spot size, distortion, and the amount of scattered radiation.⁷⁴

The tool used to determine the spatial resolution of an imaging system is called a line pair test pattern.² This test pattern is used to measure how far apart two objects must be before they can be seen as separate and in detail on the image.² Currently, a quality control test tool called the line pair gauge and NORMI 13 are used to measure the amount of spatial resolution for imaging systems.⁷⁵ The higher the spatial resolution, the smaller the object that can be imaged and the better the spatial resolution.⁷⁶ Most conventional imaging systems have an average spatial resolution of approximately 8 lp/mm² while the Lodox x-ray system has 5 lp/mm.⁷⁷

Clinically, spatial resolution is the ability of an imaging system to image small, high-contrast objects, such as calcifications in soft tissue.² Therefore, a radiographic image that has a greater spatial resolution or recorded detail has a limited amount of unsharpness of the anatomical structures hence improving diagnosis.⁷⁴ Small focal spots created by an increased anode angle give a better spatial resolution.⁷⁸ A reduced focal spot also reduces focal spot blur which is an undesirable illusion that reduces spatial resolution at the edges and in the middle of the images.² In the x-ray tube of both conventional x-ray systems and Lodox x-ray systems, focal-spot blur is small on the anode side and large on the cathode side of the image.²

The two imaging modalities have a difference in SID where the Lodox x-ray system uses a 130 cm SID and the conventional x-ray systems use a SID of 180 cm.⁴⁴ The OID affects the image's sharpness due to the increased size of the penumbra.⁷⁴ The use of a longer SID results in less magnification, less focal-spot blur and this improves the spatial resolution of an image.² Additionally, spatial resolution can be reduced by x-ray tube motion-related unsharpness which occurs when the x-ray tube and detector move at the same time such as during Lodox imaging.¹ This movement may cause a penumbra on the image and add to secondary radiation (scatter) on the image thus lowering the special resolution.^{1,79,80}

Since no research could be located to establish the difference in spatial resolution between conventional x-ray systems and Lodox x-ray systems and the impact this has on the images, the researcher will measure the values of spatial resolution of the two systems and then compare the values obtained for the images produced by each imaging system.

2.5.3 Contrast resolution

Contrast resolution is the ability of the imaging system to distinguish many shades of grey from black to white on an image.^{2,74} Ideally, an imaging system should be able to show objects that do not vary much in density from the surrounding tissue on an image.² The principle descriptor for contrast resolution is grayscale, also called dynamic range or contrast detectability.² Contrast resolution is influenced by scattered radiation and dark noise.² In principle, images with less scattered radiation and low dark noise have increased contrast resolution.²

The two primary factors that contribute to increased scatter radiation are increased kVp and increased x-ray field size.⁶⁸ For conventional x-ray systems, the x-ray field size can be reduced by beam restricting devices that are designed to control and minimize scattered radiation by limiting the x-ray field size to the region of interest only.⁴³ Where most conventional x-ray systems have a kVp range from 25 to 150kVp, the Lodox x-ray system has a kVp range from 50 to 145kVp^{43,77} which indicates that the two systems have almost the same range of kVp settings.⁷⁷ Since kVp is a significant contributor to scattered radiation, radiographers should always use the lowest reasonable kVp to penetrate the anatomical part optimally as higher kVp settings will increase the Compton scatter which will then reduce the contrast resolution.²

For the Lodox x-ray system, there is minimal radiation scatter attributed to the Lodox beam and detector configuration where a fan beam of 6 mm (length when the light reaches the detector and along the scanning length) is used.⁸¹ This beam is restricted by a narrow slit and a fan-width adjustment collimator into a laser-like fan beam of primary x-ray photons which spreads out in only one direction across the scanning direction.⁷⁷ This narrow beam reduces the number of x-rays scattered that cause the dark noise on the image, hence reducing the contrast resolution.¹ On the contrary, a conventional x-ray system emits an x-ray beam from a conical-shaped source that spreads out in four directions after collimation.^{1,43} Although there is a structural variation for these two imaging systems, there is a need for empirical research to establish any differences in contrast resolutions for the two imaging systems.

2.5.4 Dark noise

Image noise is a grainy, mottled, random disturbance or uneven appearance on an x-ray image that reduces the clarity of visualization of a recorded object.⁷⁶ This is also referred to as dark noise.⁸² Image noise can be inherent in imaging systems, but some of the factors affecting image noise fall under the control of the radiographer.⁶⁸ Minimising image noise raises the image quality by improving contrast resolution.²³ Image noise is expressed as the signal-to-noise ratio (S/N).⁴³ A

high signal-to-noise ratio indicates less noise on an image;⁴³ hence, dark noise is inversely proportional to image contrast.⁴³

The signal in a radiographic image is that portion of the image forming x-rays that represent the anatomy of the image.² The signal represents the difference between those x-rays transmitted to the image receptor and those absorbed photoelectrically inside the body of the patient.⁴³ In digital radiography, image noise has less effect on the image density due to the ability of the computer to compensate for a lack of density, therefore, noise affects mostly the contrast resolution of the image.⁴³ Differently stated, lower noise results in a better image because it improves contrast resolution.²

Image noise can be caused by a quantum mottle and scatter radiation.² Quantum mottle refers to the random nature by which x-rays interact with the image receptor and is controlled by the mAs used to acquire the image.^{43,83} Quantum mottle is the highest when very few photons interact with the image receptor² giving the final image a grainy appearance. Noteworthy is that although at increased mAs settings there is low noise, there is also an increased radiation dose to the patient.² Therefore, it is important to maintain a balance between the noise and contrast resolution of an image.⁴³

As mentioned in 2.5.3, the three primary factors that influence the relative intensity of scatter radiation that reaches the image receptor are field size, and patient thickness.^{2,43} The radiation scatter that causes noise on an image is primarily caused by Compton interaction between the body electrons and the photons.² When kVp increases, the interaction between photons and electrons increases, hence increasing noise on an image.² Thus, the appropriate selection of kVp should be adequate to form an optimal image only.² Additionally, the more the beam is restricted by collimation the less the amount of radiation that reaches the image receptor, the less the scatter and hence less noise.² Therefore, it is essential to reduce the noise by restricting the beam only to the region of interest (ROI). Furthermore, it is recommended that a radiographer should always aim at using adequate milliampere (mAs) and low kilovoltage (kVp) settings to reduce quantum mottle.²

To minimize the scatter radiation, the Lodox x-ray system has been fitted with a detector that has a scatter absorbing housing that eliminates the remaining scatter before it is detected.⁸⁴ This can increase the signal-to-noise ratio of the image.⁸⁴ Additionally, Lodox linear slot scanning technology uses only a 6 mm aperture that is lead collimated.⁸⁴ The controlled aperture minimizes the amount of scattering compared to the rectangular collimated surface of a

conventional x-ray system.^{43,84} In addition to a narrowed aperture, there is a post-patient rejection grid that absorbs the scatter before reaching the surface of the image receptor.⁸⁴

In conventional x-ray systems, a wide beam x-ray source results in increased scattered x-ray photons that increase scatter radiation which increases the noise on the image.^{2,43,84} Additionally, the higher probability of scattered radiation when using conventional x-ray systems causes relatively high amounts of scattered radiation throughout the x-ray room.⁶⁸

Despite the difference in technology between the conventional x-ray systems and Lodox x-ray systems, the researcher wanted to verify if there are significant differences in the amount of dark noise for the two imaging systems and how this impacts the image quality.

2.6 Development of clinical protocols

A protocol is a set of rules or official procedures consisting of fixed steps; that must be followed in all cases that govern the state of affairs.^{7,9} In the medical profession, protocols are used to provide a step-by-step guide to deliver treatment or care, and inform who should do what and when, and in which order the executions should be made.⁸ In other words, protocols are prescriptive of what must be done. A protocol can thus be used as a guideline to manage a clinical condition from clinical diagnosis through treatment.⁹ Clinical protocols are developed to ensure best practice and to provide evidence-based care.⁸⁻⁹ Unlike clinical guidelines (discussed below), a clinical protocol usually consists of a significant volume of information but provides less detail.⁸ In this research, a protocol guideline also known as a clinical guideline or best practice guideline was established and the outcome was used to develop the final product of this research; which was referral pathway (imaging protocol) for Lodox imaging.

Clinical guidelines are also general rules, but they provide more specific detail.⁸ Clinical guidelines are thus usually presented in greater depth and contain specific supportive information.⁸ Although clinical protocol and clinical guidelines are used interchangeably, a clinical protocol is seen as a document that has legislative responsibility.⁸ A clinical protocol presents protocol guidelines and best practice guidelines.⁸ The best practice guidelines are also called clinical guidelines; or statements of best practice. Both protocol guidelines and clinical guidelines are systematically developed.⁷⁻⁸ The protocol guidelines are more specific and are expected to be followed in detail with little scope for variations.⁷ Protocol guidelines are used in areas with high risks like trauma and emergency units in hospitals.⁸ In this research, protocol means a clinical protocol that has been used to present protocol guidelines or best practice guidelines for clinical use. A referral pathway (imaging protocol) has been developed to guide the management of a patient undergoing imaging using the Lodox x-ray system⁸ (see Chapter 6).

2.6.1. Implications of using clinical guidelines in practice

The use of guidelines in clinical practice has been informed to close a gap between the existing and optimal practice.⁸ Guidelines improve the quality of healthcare while decreasing costs and over-utilization of resources, influencing decisions about health interventions, and outlining procedures to be followed thus helping clinicians to make evidence-based decisions.⁸ The use of clinical guidelines can be an effective means of both changing the process of healthcare delivery and improving outcomes.⁸ The use of guidelines has been associated with improved patient management outcomes.⁸

2.6.2 Process of development of referral pathway (imaging protocol) guidelines

The consensus method, which entails a group decision-making process, is recommended for extracting professional collective knowledge used in the development of guidelines.⁸⁵ This collective knowledge is also called experts' opinion.⁸⁵⁻⁸⁶ The two common consensus methods of data collection are 1) the Delphi technique or 2) the Nominal Group Technique.⁸⁵⁻⁸⁷ Although consensus methods of developing guidelines are suggested, they have the potential to flaw the conclusion if the process includes expert opinions only.⁸ For the development of guidelines, the literature suggests that both a systematic synthesis of existing literature and the opinion of experts should be used to minimize bias.⁸ However, in this research, there was limited content published on protocol development for the Lodox x-ray system and the researcher, therefore, relied on expert opinions while referring to the available resources. The Delphi technique, unlike the Nominal Group Technique, is popular for the development of guidelines because it does not require participants to assemble.³⁷ When using the Delphi technique, the questionnaire can be emailed and repeat rounds can be done remotely without synchronous participation.⁸⁶⁻⁸⁸ Unlike the Delphi technique, the Nominal Group Technique requires an extended engagement in a common sitting until consensus is reached.⁸⁹⁻⁹⁰ The Delphi technique of data collection requires group facilitation that uses a multistage process designed to convert individual opinion into group consensus (also called general agreement). The Delphi technique involves these stages: identifying a research problem, literature synthesis, development of a questionnaire, conducting an anonymous iterative survey, which may be posted or emailed. Experts are asked to rate or rank the statements to determine whether they agree or disagree with the statements; individual feedback is obtained; feedback is summarised, and questions are emailed back to participants who previously participated. This process is then repeated until consensus is reached.³⁷ The iterative process is continued until the greatest level of consensus is reached or a predetermined

number of rounds have been completed. Participants do not meet face-to-face or interact directly.

As confirmed from the literature, the process to develop a referral pathway (imaging protocol) should involve four steps:

1. Step 1: A questionnaire is emailed or mailed to a group of experts on the topic of discussion. These participants individually rate or rank their agreement with specific statements that have been presented by a researcher.
2. Step 2: The researcher or someone organizing the Delphi technique collates and summarises the responses and documents the preliminary level of group consensus for each item. Care should be taken not to lose the meaning of the information supplied by the participants. The summarised outcome for this phase is then used to generate a second round. The questions that have reached consensus in the first round are not repeated in subsequent rounds.
3. Step 3: A second questionnaire, displaying the summarised response and consensus level, is sent back to the participants, who are again allowed to rank their initial judgment considering the group's response. Any respondent who holds an opinion that still differs substantially from that of the group should provide a brief explanation or reason for disagreeing. This is usually in the form of a semi-structured open-ended questionnaire.⁸⁵
4. Step 4: Steps 2 and 3 above are repeated after considering the emerging pattern of group consensus and reasons for dissent. The number of rounds is determined by the level of agreement (consensus) which is set by the researcher or by the participants. In this context, consensus means no new concerns or input is given by any of the participants. Noteworthy is that there is no firm or universally accepted norm for consensus.

To ensure the development of quality guidelines, the researcher used a process recommended by an international team of guidelines developers and researchers called the AGREE collaboration (Appraisal of Guidelines, Research, and Evaluations).⁹¹ This organization is tasked with the development of instruments that are used to assess the process of guidelines development and reporting.⁹¹ The AGREE team proposes six domains to be used in the appraisal of guidelines. These domains are scope and purpose, stakeholder involvement, the rigour of development, clarity of presentation, applicability, and editorial independence.⁹¹ The domains assess the quality of practice guidelines, provide direction on guidelines development and guide on what information to be reported in the guidelines.⁹¹ The researcher used the AGREE II validation method that is proposed internationally for the two rounds of the Delphi technique used in this

study.^{38,87,91} (discussed in detail in Chapter 3). The guidelines developed for this study will inform the referral of trauma patients for chest imaging with the Lodox x-ray system.

CHAPTER 3: RESEARCH DESIGN AND METHODOLOGY

3.1. Introduction

Research methodology is a systematic way of solving a problem through a research process using predetermined methods, procedures, and tools.^{34,92} It is also a study on how research is done scientifically by applying various steps adopted by a researcher in solving an existing problem.^{28,34}

This research aimed at developing an adult chest referral pathway (imaging protocol) for trauma patients undergoing Lodox imaging at trauma units. This chapter presents the research methodology that was applied throughout the research including a theoretical framework, conceptual framework, research paradigm, research approach, research design and mode of inquiry, research settings, and research methods that were used during the data collection for the study.

3.2 Theoretical background

The theoretical background of this research underpins the research paradigm, research approach, and mode of inquiry.

3.2.1 Research paradigm

A paradigm is the fundamental belief and assumptions from which knowledge is built. It is also someone's world view.⁹³ A research paradigm helps the researcher to be organised in his observation, judgement, and interpretation of the research throughout the process.⁹⁴⁻⁹⁶ The researcher used a positivist paradigm.⁹² which is based on a rationalised empirical philosophy that is defined as a scientific method of testing a theory, describing an experiment through observation and measurement.⁹⁶ The researcher used observation and measurements to collect the data which was used to draw a logical conclusion about the outcome of this research.⁹⁷ A positivist paradigm follows a quantitative mode of inquiry.⁹² In this research, the observation method (which has been presented as content analysis) was used in determining the similarities between the images and the measurement was the method that was used to determine the factors impacting the image quality of the two types of imaging systems.⁹⁷⁻¹⁰⁰ The e-Delphi method has been used in the formulation of the guidelines (see Section 3.6.1).

3.2.2 Research approach

A research approach refers to the way a researcher thinks about the researchable phenomena or situation.¹⁰¹ It is the philosophical assumptions, or philosophical framework, that a researcher

adopts to research a topic.³⁴ There are three main approaches to research; adductive, inductive, and deductive reasoning.¹⁰¹ The deductive approach entails applying a general principle of reasoning to a specific case and is used in testing theories and their propositions.¹⁰¹ An inductive approach entails the generalisation of principles of reasoning from a specific case.³⁶ It is used to develop theory through observations of empirical reality, from which a general inference is deduced.⁹² Deductive reasoning is linked to a quantitative mode of inquiry, while inductive reasoning is linked to a qualitative mode of inquiry.⁹² The researcher used deductive reasoning to investigate the similarity between and the quality of images obtained from both the conventional and Lodox x-ray systems. Deductive reasoning was also used in the formulation and verification of the guidelines that were developed. The data collected on similarity and quality of images guided the formulation of questions that were used to formulate and verify protocol guidelines for imaging an adult chest imaging for trauma patients.⁹⁷

3.2.3 Mode of Inquiry

Research methodology uses two main modes of inquiry to formulate answers for set research questions, namely, quantitative- and qualitative modes.³⁶ Each mode of inquiry has its unique weaknesses and strengths.³⁴ To accumulate the data for this research, the researcher used the quantitative mode of inquiry in both phases of research. The quantitative mode of inquiry was used in the analysis of data obtained in the coding of the images, measuring them and in the formulation and verification of clinical guidelines. This was performed by expressing the obtained data in terms of precise mathematical formulae to obtain functional relationships.⁹²

3.2.4 Research design

The research design is a blueprint of how the research will be conducted.³⁴ The research design should be sensitive to the research problem, research question, research aim, and the purpose of the research.³⁵ For phase one of the study, a descriptive, correlational design was used to examine and identify the interrelationship between the variables of different imaging systems under investigation in this research.³⁶ This design was used to express the interrelationships between two variables among a group of subjects. It also expresses the direction and magnitude of the relationships. This design was used to establish the relationship between factors affecting the image quality and the images produced by the Lodox x-ray systems and conventional x-ray systems. The researcher used a comparative, descriptive design to measure the level of distortion, spatial resolution, contrast resolution and image noise. For phase 1 of this research, content analysis was used.^{97,100,102-103} To achieve Objectives 1 and 2 of Phase 1, a descriptive

correlation design was used.³⁶ to correlate the findings of the image similarity, image quality and the factors affecting image quality.

Phase 2 of the research used consensus methods of data collection. Consensus methods entail the extraction of professional knowledge that is difficult to express and formulate by a researcher alone.⁸⁵ The e-Delphi method was used in the development of a referral pathway (imaging protocol) for Lodox imaging through a consensus approach since there was scant information or research-based evidence available on chest imaging using the Lodox x-ray system.⁸⁵ The e-Delphi method was used to formulate and verify the referral pathway (imaging protocol) for a patient undergoing chest imaging with the Lodox x-ray system.

3.3 Conceptual framework

The conceptual framework for the research is presented diagrammatically as follows:

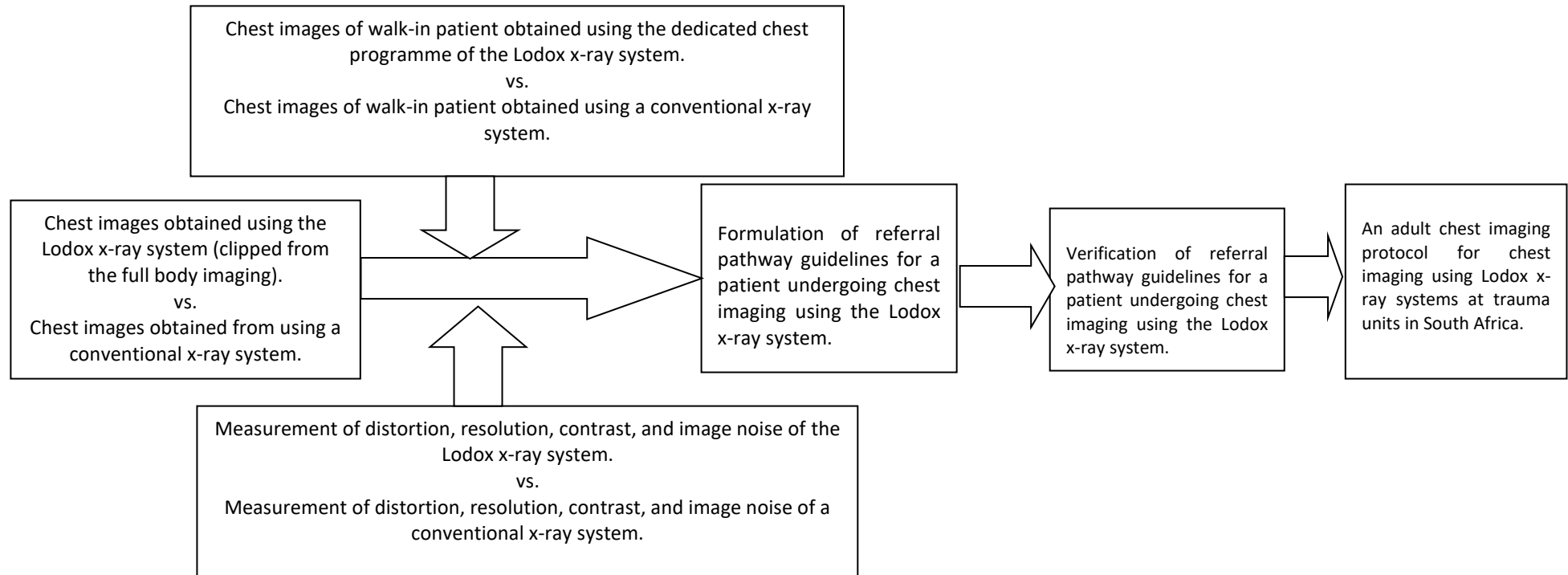


Figure 3.1: Flow diagram on the conceptual framework

3.4 Research Methods

Research methods are all techniques or tools used to collect data.⁹⁷ The researcher used the content analysis method, the structured observation method, and the e-Delphi method to develop an adult chest referral pathway (imaging protocol) for trauma patients undergoing imaging with a Lodox x-ray system.^{100,102-103} Each method has been used to address the respective objectives in Phase 1 and Phase 2 of this research.

3.5 Research Setting

This research was conducted at hospitals in South Africa with a functioning Lodox x-ray system. South Africa is a country with a rich history of advancement in the application of the use of Lodox imaging in trauma units and forensic pathology.¹³ Among the 121 Lodox x-ray systems installed at trauma units globally, 28 (23.14%) are in South Africa. Therefore, South Africa was an appropriate research setting for this study.³² Five of the 28 hospitals with a Lodox x-ray system in South Africa were contacted for data collection for this research.

3.5.1 Data Accumulation for Phase 1

The researcher used content analysis to address objectives 1 and 2 for Phase 1 (see 3.5.3.2 & 3.5.4.2). Content analysis was suitable for assessing the diagnostic similarity between trauma chest images acquired with conventional x-ray systems and those acquired with Lodox x-ray systems for the same patient.¹⁰⁰ Four radiologists read the images and then assigned a value which was later analysed by a statistician. Structured observation was used to compare the size distortion, spatial resolution, contrast resolution and noise of the imaging systems from which the images used in objective 1 were obtained.

Content analysis is a systematic empirical way of data collection from visual content.¹⁰²⁻¹⁰³ Hence content analysis may use a quantitative form of analysis which entails an assessment of what may be counted e.g. images, words and news items.^{97-98,100} This type of analysis relates to a positivistic paradigm that was developed from the mid-1900s in America to apply subjectivity to the cultural meaning¹⁰⁰ and can also be defined as a measurement of proportions indicating popularity or index of intensity counting frequencies of a phenomenon in a scenario to gauge significance with other scenarios.^{97,100} While using scientific observation,¹⁰³⁻¹⁰⁴ content analysis involves devising and then categorising the unit of analysis to establish phrases that are assigned codes.^{100,103} After the unit of analysis is assigned a code, it is recorded on a coding schedule which can be in the form of a checklist.¹⁰⁰ In this research, normal anatomical and pathological patterns represented

on an image were scored by four radiologists and represented using a numerical value for statistical analysis.

A coding schedule can be in the form of a checklist with each row containing each of the units of analysis that will be rated on an image.¹⁰⁰ A coding manual is a description and numbering code that is assigned to each phrase or word used to refer to a unit of analysis.¹⁰⁰ In this research codes varied from 2 indicating 'visible or good', 1 indicating 'partially visible or satisfactory', 0 indicating 'poor or invisible' and -1 indicating 'absent' or 'not expected on the image'. The coding manual was also used to guide the tabulation.¹⁰⁰ A tabular representation has rows indicating each unit of analysis and columns representing codes assigned on the phases used to identify the unit of analysis. Descriptive statistics like mode and frequencies were then derived from the tables. Inferential statistics were used to determine the similarity between the images acquired using both systems.⁹²

3.5.2 Unit of analysis for images used in Objectives 1 and 2 (Phase 1)

For the data accumulated for Objective 1 of Phase 1 of the study, diagnostic similarity refers to the anatomical and pathological patterns presentation on two images of the same patient which carry the same value in diagnosis. In Objective 1, Phase 1, two images of the same patient were compared for similarity, one acquired using a Lodox x-ray system and the other one acquired using a conventional x-ray system. In Objective 2, the image quality of a CXR was compared for the same patient who had undergone imaging with both imaging systems.

Representation of normal and pathological structures was scored in terms of how images appeared. The unit of analysis was described and scored as stated (see Annexure B). The appearance of the anatomical and pathological patterns on the full-body Lodox chest images (cropped images) was compared to the images obtained from the conventional x-ray system. Inferential statistics were used to determine the similarity of the images for both systems.⁹² The resultant data was converted to frequencies and proportions, which was graphically represented.

In addition, the quality assurance parameters (see Annexure C) for the two systems were measured and the average score was graphically represented to derive their association with the outcome of the image analysis.

The inclusion criteria for Objectives 1 and 2 of Phase 1 were:

- Patients of 18 years and older,
- Patients referred for CXR images to be obtained with a conventional x-ray imaging system,

- Patients that were conscious and could independently sign a consent form,
- Ambulant, conscious, oriented, and responsive patients.

The exclusion criteria for objectives 1 and 2 of phase one were:

- Patients below the age of 18 years,
- Unconscious patients who could not follow instructions during the imaging in Objective 2.

3.5.3 Objective 1 of Phase 1

Objective 1 of Phase 1 assessed the diagnostic similarity between adult trauma chest images acquired using the full-body programme of a Lodox x-ray unit and a conventional x-ray unit for the same patient. The researcher used content analysis (see 3.5) to assess the diagnostic similarity between the acquired images.¹⁰⁰

3.5.3.1 Sample selection and sample size for Objective 1 of Phase 1

A total of 278 images, 139 chest images obtained from Lodox x-rays systems, and 139 chest images obtained from conventional x-rays systems were reported by radiologists for normal anatomical and pathological patterns.

3.5.3.2 Data collection for Objective 1 of Phase 1

Retrospectively, 139 chest images clipped from full-body Lodox images and 139 chest images acquired using conventional x-ray systems were reported and the findings were compared by four radiologists. The images were coded and all details (e.g the systems used to acquire the images) were blinded. Among the four radiologists who participated in this research, two radiologists worked at state/government hospitals and reported the images together while the other two radiologists were working at a private hospital and reported the images together. The radiologists at both institutions (government and private) discussed and recorded the findings by coding the checklists by scoring the parameters/units of analysis as visible/good (scored as 2), partially visible/satisfactory (scored as 1), or invisible/poor (scored as 0) and absent/not expected on the image (scored as -1) for each image (see Annexure B). This objective aimed to compare the quality of chest images obtained using the full-body programme of the Lodox x-ray system to those acquired using the conventional x-ray system.

3.5.3.3. Data analysis for Objective 1 of Phase 1

The resultant data was converted to frequencies and proportions which were graphically represented. Inferential statistics were used to compare the results obtained for both x-ray systems. The tests included the nonparametric independent Mann-Whitney U test since the

participants in the two groups could not be linked and all tests were done at a 5% level of significance.

3.5.3.4 Validation for Objective 1 of Phase 1

Images were coded and blinded to avoid bias in reporting. Four radiologists reported the images. Two radiologists from a state/government hospital and two radiologists from a private hospital performed the reporting. At both institutions, the two radiologists discussed and recorded their findings on a checklist for each set of images. inter-reader reliability between the radiologists at the state/government hospital and those at the private hospital was established. inter-reader variability was performed by comparing the analysed data from 10 known images that had been reported by the state/government radiologists and those that had been reported by the private radiologists. intra-reader variability was obtained by comparing the analysed data of known images that had been reported by the same radiologists after two months. Intra-reader variability is an error that occurs from the same individuals after a repeat of a same-measured or observed object by the same individuals over a duration of time.¹⁰⁵ Inter-reader variability is an error that occurs between two individuals or groups that had measured or observed the same object.¹⁰⁵ the difference between their findings defines the extent of the errors. In this research, these errors indicated the interpretation bias of the radiologists that interpreted the images.¹⁰⁵

3.5.4 Objective 2 of Phase 1

Objective 2 of Phase 1 of this research assessed the diagnostic quality of adult chest images acquired using the chest-dedicated imaging programme of the Lodox x-ray system and those acquired using a conventional x-ray system about the level of size distortion, spatial resolution, contrast resolution, and image noise. As was mentioned in Section 3.5.1, the researcher used content analysis to assess the diagnostic quality of adult chest images of the same patient performed with both imaging systems. The outcome of the diagnostic quality of the chest images was linked to the results that were obtained after measuring the level of size distortion, spatial resolution, contrast resolution, and image noise to identify the causes of any possible differences in the image quality.

3.5.4.1 Sample selection and sample size for Objective 2-Phase 1

Five (5) Lodox imaging systems were included for data collection. The Lodox x-ray systems were purposively selected from the 28 Lodox x-ray systems installed across South Africa. Purposive sampling involves a conscious selection of participants/objects.³⁶ The hospitals with the highest number of patients undergoing Lodox scanning were selected. Purposive sampling was also used

to select the to select the walk-in patients at the five hospitals where this research was conducted. Each patient underwent an examination using the Lodox and a conventional x-ray system. The participants were patients aged 18 years and above who were referred by their physician for chest imaging due to a suspected pathology or undergoing a follow-up examination of a known chest pathology. A total of 77 images were obtained (one conventional image could not open). Thirty-nine (39) Lodox CXR images and thirty-eight (38) conventional CXR images were reported by the consultant radiologists. One image obtained from a conventional x-ray system did not open on a MicroDicom viewer with the software that was used to read the images. A statistician proposed a sample of 34 images from each set of images which would ensure a confidence value of above 80% (see Annexure F).

3.5.4.2. Data collection of Objective 2 of Phase 1

To collect the prospective data for objective 2 of Phase 1, thirty-nine (39) walk-in patients aged 18 years and above underwent chest imaging with the Lodox chest-dedicated programme after completing the requested chest images using a conventional x-ray system. This additional chest PA image with the Lodox x-ray system was acquired using the system's standard imaging parameters. Noteworthy is that the SID used with the conventional imaging system was 180 centimetres, but it was 130 centimetres (maximum distance) for the Lodox x-ray system.⁴⁴ Once the images were obtained, the radiologists assessed the anatomical and pathological patterns on the images by assigning a code to the units of analysis/parameters using an online structured checklist (see Annexure B). There was additional space for a comment on the checklist. The coded checklists were downloaded in MS Excel format and analysed to compare the quality of the images acquired using both the x-ray systems.

3.5.4.3. Data analysis of Objective 2 of Phase 1

The data was analysed using descriptive statistics like frequencies and proportions to summarise the results. Inferential statistics, which included tests like the independent nonparametric Mann-Whitney U test was done to compare the same parameters for the two sets of images. The individuals could not be linked between the two sets of data hence the use of independent testing. Power analysis, using the G*Power version 3.1.9.2 shows that if assuming a large effect size of 0.5, a significance of 5% and a power analysis of 80%, then a sample of 64 images per group will be needed.

3.5.4.4 Validation of Objective 2 of Phase 1

For the two imaging systems used to generate the images, the same parameters, namely, distortion, spatial resolution, contrast resolution and image noise were used to compare the quality of the image for the two systems.

3.5.5 Measurement of factors affecting image quality

The following section describes the process followed to measure the parameters that influence image quality for the two imaging systems explored in this research.

3.5.5.1 Research method used in measurement for Objective 2 Phase 1.

Measurement refers to the process of describing abstract concepts in terms of specific indicators by assigning numbers to the indicators according to specific rules.^{34,97} Measurements consist of rules for assigning numbers to the variables that are being measured.³⁶ Measurement is an empirical evidence-based method of data collection for creating objective scientific knowledge.³⁴ In scientific measurement, the adequacy of the rules used in assigning numbers to attributes assures the adequacy of the scores obtained.³⁴ Upon meeting the defined rules, numbers are assigned to a variable consistently in a numerical form.³⁴ In other words, the numbers assigned to the objects represent quantities or sizes numerically.³⁴ The validity and reliability of a procedure are dependent on the credibility of the measurement procedure and measuring instrument.³⁴

In this research, the level of distortion, spatial resolution, contrast resolution and image noise of Lodox x-ray systems and conventional x-ray systems were measured using a NORMI 14 phantom which is a tool that is used to measure the resolution, contrast and image noise on x-ray images.^{2,47,106} The researcher recorded the indicated parameters for the image pairs on a checklist and then data was plotted on a bar graph.¹⁰⁷ Checklists are used when there are specific, observable items, actions or attributes to be recorded. Sometimes they have a space for additional comments.¹⁰⁸ The researcher wanted to establish if there was a difference in the spatial resolution, contrast resolution and image noise which might impact the quality of the images produced by the Lodox- and conventional x-ray systems respectively.

3.5.5.2 Sample selection and sample size used in measurement for Objective 2 of Phase 1

The researcher purposively sampled Lodox- and conventional x-ray systems to acquire the images. Purposive sampling is the choice of easily accessible and available subjects that meet the criteria of the research.⁹⁵ The researcher used the Lodox and conventional x-ray systems that were used in Objective 1 to minimise the costs and time in the data-collection process. The level

of distortion, spatial resolution, contrast resolution and image noise was measured for each imaging system to compare the image quality. These measurements were performed on Lodox- and conventional x-ray systems at the five hospitals from which the data for Objective 1 and Objective 2 of Phase 1 was collected.

3.5.5.3 Process used in measuring the level of distortion, spatial resolution, and contrast resolution

The researcher measured distortion, spatial resolution, contrast resolution and image noise with the assistance of a physicist and the radiographer in charge of quality control at each of the included institutions using the NORMI 13 phantom (see figure 3.2).⁷⁵ Each variable was measured four times and the average value obtained was written down. This was repeated for all the included institutions. Another tool used was a downloadable MicroDicom viewer to obtain values such as pixel values to determine image noise.¹⁰⁹ During the procedure, the phantom and copper plate were strapped such that the surface was fully in contact with the erect Bucky of the x-ray unit. The data was captured on a quality assurance checklist developed by the researcher (see Annexure C).

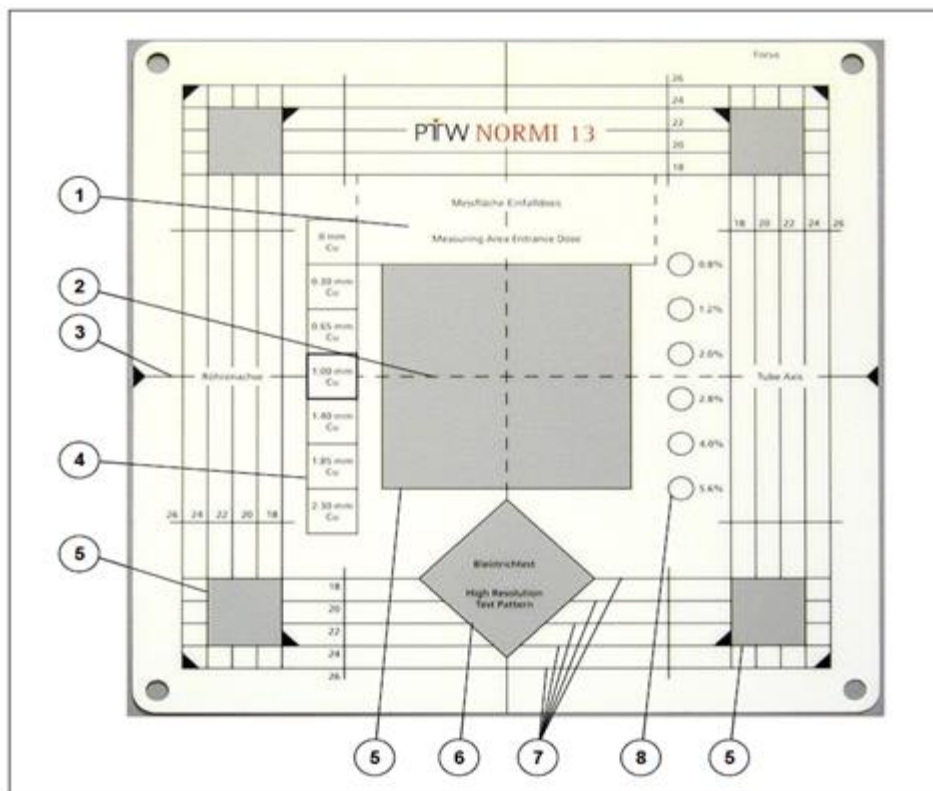


Figure 2: NORMI 13 test object

- | | |
|---|--|
| <ul style="list-style-type: none"> 1 Dose measurement area, marking not radiopaque 2 Crosshairs for central alignment, not radiopaque 3 X-ray tube axis 4 Dynamic steps | <ul style="list-style-type: none"> 5 Free area for signal normalization 6 X-ray test pattern for spatial resolution 7 Radiation-absorbing line marks for light field adjustment 8 Low contrast objects for contrast resolution |
|---|--|

Figure 3.2: A schematic representing o the NORMI 13 Phantom¹¹⁰

3.5.5.4 Description of phantom used in the measurement process

The NORMI 13 phantom (T42023) has specific dimensions; 300 mm x 300 mm x 10 mm.⁷⁵ This test tool has different regions that display various quality control measurements on an image for quantification purposes.¹¹¹ The NORMI 13 phantom shows a dynamic step labelled 4 on an image for measuring contrast resolution, an x-ray test pattern labelled 6 for measuring spatial resolution and a radiation-absorbing line 7 for size distortion (see Figure 3.2).⁷⁵ The NORMI 13 phantom has a seven-step greyscale range that represents a range from white to black on a processed image.⁷⁵ Ideally, all steps of the dynamic range must be discernible on a varying density.⁶⁸ However, depending on the dynamic range of an imaging system, these densities may vary giving different values.⁷⁵ The researcher used the greyscale of the NORMI 13 phantom to quantify the contrast resolution (dynamic range) of the two imaging systems⁷⁵ and also to evaluate the number of line

pairs per millimetre (lp/mm) to obtain the spatial resolution for the imaging systems.^{43,68} This data was obtained from the section labelled 6 (see Figure 3.2) of the NORMI 13 phantom image. To establish size distortion, the researcher used a radiopaque line labelled 7 on the NORMI 13 phantom (see Figure 3.2). The average measured length of the lines on the images and the averaged true length of these lines on the phantom were also established. The average was obtained by measuring this length three times. The percentage of the scaling error (also known as size distortion) was determined by establishing a percentage of (average of measured length minus average of true length) and the outcome was divided by the true size of this line.^{68,75} The formula below was used to establish the scaling error.

$$\frac{(\text{Average measured length} - \text{Average true length})}{\text{True Length}}$$

3.5.5.5 Process used in measuring image noise (dark noise).

The image noise (dark noise) was measured using a copper plate of dimension 15 X 15cm and a thickness of 0.5mm. The exposures were made at a distance of 180cm (conventional systems) and 130cm (Lodox x-ray systems) respectively.⁴⁴ The values were read from a MicroDicom viewer to obtain the pixel values on five evenly distributed sites on a processed image.¹⁰⁹ The average pixel value was obtained for the two imaging systems compared and plotted on a graph to obtain (see Figure 4.4).

3.5.3.6 Validation for the measurements used in Objective 2 of Phase 1

The degree of validity of a measuring instrument is the ability to actually measure the parameters in question and to accurately measure a parameter of interest.³⁴ To ensure the validity of measurement for this objective, the researcher used the NORMI 13 phantom which is the most recent tool used to measure the constancy of the quality assurance parameters of imaging systems.¹¹⁰ Quality assurance parameters were measured three times and averaged. Then numerical figures were established to minimise measurement error.³⁶ To further ensure validity, the researcher was assisted by the medical physicists and radiographers in charge of quality control at the institutions that participated in the research. A medical physicist is a professional in charge of the quality control of the imaging equipment at a radiology facility.¹¹²

3.6 Formulation of referral pathway (imaging protocol) guidelines

3.6.1 Introduction

Objective 1 of Phase 2 of the research involved the formulation of referral pathway (imaging protocol) guidelines for adult patients undergoing chest imaging with Lodox x-ray systems. A guideline document is a document that has been systematically developed for the purpose of health interventions whether in the form of clinical, public or policy interventions for evidence-based decision-making.¹¹³⁻¹¹⁴ Differently stated guidelines are systematically developed standards of practice recommended by a team of experts in a particular discipline.¹¹³

In this research, the formulation and verification of referral pathway (imaging protocol) guidelines for patients undergoing chest imaging with Lodox x-ray systems were performed using the Delphi method.⁸⁵ This was performed by contacting the medical doctors and nurses who had specialised in trauma and had worked at trauma units that use Lodox x-ray systems. The e-Delphi used in this study is presented in the next section.

3.6.2 Research method used for the formulation of guidelines

The e-Delphi method of research is a technique used to survey and collect data on expert opinion in a given theme.³⁹ It is a multistage approach of data collection in which a subsequent stage is built based on the outcome of the previous stage.⁴⁰ This research deployed a two-round e-Delphi process which involved the completion of a questionnaire (see Annexure J) by a panel of experts (doctors and nurses) at the trauma unit to give an opinion on indicators to be used as referral pathway (imaging protocol) guidelines for Lodox imaging at the casualty departments of the participating hospitals.³⁹ Ninety-six (96) trauma specialists (doctors and nurses) were contacted to participate in this research. In the first round of the e-Delphi, all the available trauma specialists (nurses and doctors) were consulted to formulate a questionnaire on issues of high pertinence. The researcher used the Delphi technique because it does not require face-to-face meetings and it is possible to use a bigger population from diverse geographical locations.³⁷ The experts for this research were located in different areas within the country and therefore it was advantageous to use the e-Delphi technique of data collection.³⁷ The questionnaire (see Annexure J) was sent to the participants who were practising as trauma specialists. Their response was summarised and used to generate a second questionnaire.³⁹

This second questionnaire was returned to the participants who participated in Round 1. In Round 2, the participants were expected to reconsider their previous opinion, add an opinion, or agree with the outcome of the previous round. The repeat rounds were done until consensus was

reached.³⁹ According to Hasson, Keeney and McKenna (2000), consensus is the conversion of diverse ideas to a common group opinion. Although the Delphi method is often used to obtain consensus, this is not always the case.⁴⁰ The question of whether consensus is desired or not is based on the aim of the study, the correctness of the answer and appropriateness of the responses.⁴⁰ Since the initial questionnaire was designed by experienced trauma specialists (doctors and nurses) who had academic and clinical experience, the number of rounds in which participants were contacted before reaching consensus was expected to be few.

Inclusion criteria for the formulation and verification of referral pathway (imaging protocol) guidelines

Medical doctors and nurses who had specialised in trauma and had worked at hospitals with a Lodox x-ray system participated in this research.

Exclusion criteria for the formulation and verification of referral pathway (imaging protocol) guidelines

Nurses and trauma specialists that had not worked at hospitals with the Lodox x-ray system, radiologists, radiographers and medical doctors who were not trauma specialists, were excluded.

Validity and reliability of the e-Delphi technique

The use of participants with relevant knowledge and expertise on the research topic (trauma specialists and nurses who had specialised in trauma) aimed to ensure a quality outcome for the research.

3.6.3 Sample selection and sample size used for the formulation of referral pathway (imaging protocol) guidelines

The sample constituted nurses and doctors who were trauma specialists and had worked at trauma units where the Lodox x-ray system was used. Ninety-six (96) individuals were contacted and received the questionnaire link.

3.6.3.1 Sample selection

During a trauma conference from 21-22 November, 2019 at Century City in Cape Town the researcher requested trauma specialists to voluntarily supply their contact details in a booklet that was circulated to the attendants if they were willing to participate in this research. The condition was that participants must have worked at trauma units where Lodox x-ray systems were used. In addition, the researcher obtained contacts using snowball sampling. Snowball sampling is a sampling method where a mutual friend supplies the contact of participants

because they know them.⁹⁵ For this study, known trauma specialists who were working at a hospital were requested to introduce the specialists that were known to be working or had worked at a trauma unit where the Lodox x-ray system was used. Additionally, participants were selected based on the set criteria (having worked with the Lodox x-ray system) and therefore purposive sampling was appropriate.¹¹⁵ Ninety-six (96) trauma specialists working with Lodox x-ray system x-ray systems at casualty units in SA were contacted. For the e-Delphi technique, there is no recommended sample size; however, the quality of the panel of participants is significant.¹¹⁶ About fifteen participants are suggested as being a manageable sample.

3.6.4 Data collection process and analysis for the formulation of referral pathway (imaging protocol) guidelines

For the Delphi technique, two to three rounds are preferred.⁴⁰ The Delphi technique of data collection is used mainly to gain consensus about a topic from several experts on that topic.⁸⁷ The Delphi process is only completed once consensus is reached.

In this research, data were collected in two rounds. To formulate the questionnaire, three experts were consulted to assist the researcher in the formulation of a provisional questionnaire on issues of high pertinence about referral pathway (imaging protocol) guidelines for patients undergoing Lodox imaging. This is called a modified Delphi technique.¹¹⁶ In a modified Delphi technique, pre-set questions, which can be semi-structured or structured are used in the first round of the Delphi.¹¹⁶ The questionnaire was developed based on literature or supported by the three experts.¹¹⁶ The questionnaire was then sent to 96 participants who had worked with the Lodox imaging system. Responses were summarised and used to generate a questionnaire for use in a second round.¹¹⁷ This questionnaire was returned in the second round to all the participants who were requested to reconsider, agree, or rank their previous opinion.

The e-Delphi questionnaire had two sections, A and B. Section A contained demographic questions and Section B contained questions specific to the referral pathway (imaging protocol) guidelines for use at trauma units for patients undergoing Lodox imaging (see Annexure J). The data generated in the first round was quantitative. Among the responses, phrases with similar meanings were coded and a percentage was obtained for each code. Questions that had reached consensus in the first round were included in the questionnaire for Round 2. In Round 2, the participants were expected to indicate if they agreed or disagreed and to rank the statements or list of items. During the repeat round, consensus was reached by establishing a percentage.¹¹⁷ It has been suggested that to conclude that consensus was reached, the researcher should reflect on the aim of the research and the nature of responses to inform consensus.⁸⁷ In other words, to

find the correct answer, outliers may be considered as they might be right. There is no universal agreed level of consensus; therefore, each Delphi study must have a pre-set consensus level depending on the sample numbers, the aim of the research and resources available.¹¹⁸ To ensure participation, a reminder email was sent, and follow-up calls were made to the participants to remind them to engage with the questionnaire. Once consensus was reached, the data analysis (see 5.3.1) started.

3.6.5 Validation of the process used in the formulation of referral pathway (imaging protocol) guidelines

The rigour of this objective was assured by getting an opinion from trauma specialists who are experts and have experience in using the Lodox x-ray system at trauma units. To get more valid answers, more than one round of the Delphi was conducted to generate credible input.

3.7 Verification of referral pathway (imaging protocol) guidelines

This section presents the verification of the referral pathway (imaging protocol) guidelines that were formulated (Objective 1 of Phase 2) for patients undergoing imaging with Lodox x-ray systems at trauma units. Verification is the process of checking, confirming and making sure that the products meet the intended specifications needed by the user.¹¹⁹ In research, verification refers to the mechanisms used by a researcher in the process of implementing methodology and design towards ensuring reliability and validity of the results obtained, hence rigour.¹¹⁹ To achieve rigour, a researcher should attain validation in the process of verification.¹¹⁹ The validation of the developed guidelines was performed using an e-Delphi method and validation process that was guided by the criteria developed by an international team of guidelines developers and researchers called AGREE collaboration (AGREE II).⁹¹ The criteria were developed from guiding attributes for guideline development and reporting and evaluation as set out in the literature which is inclusive of the AGREE II instrument.¹²⁰

The attributes that guided the development of the guidelines were constructed into a five-scale checklist. The final responses were collated and emailed to the experts who were expected to read through the draft guidelines, rate the guidelines and then write comments outlining their opinions. The ratings and comments (from the experts) were compared and summarised. Participants remained anonymous from each other, and controlled feedback was facilitated by the researcher. Summaries of the views, ratings and refined guidelines were emailed back to each expert. Participants were given another opportunity to change their responses, concur with the views of the other participants or choose to stay within their views.

3.7.1 Validation of data collection and process of guideline developed

Validation is the process of ensuring that the product is acceptable to the end-user.¹¹⁹ In this study, the researcher developed the protocol guidelines from which the clinical protocol was developed. Therefore, it was important to ensure that the outcome was acceptable to the users who were the trauma specialists that referred patients for imaging with the Lodox x-ray system. Validation and verification achieve the rigour of the research.¹¹⁹

Trauma specialists (nurses and doctors) who were working at a casualty department that uses the Lodox x-ray system assisted researcher in developing and validating the data collection instrument that was used questionnaire (Annexure J). The data collection instrument was also piloted with a trauma specialist who did not participate in this research. The second questionnaire was developed and sent in the subsequent e-Delphi round until a consensus was reached (see 5.4.2). The questionnaires were anonymously sent and none of the respondents saw the input from their counterparts. This ensured that the answers given were unbiased by the domination of specific individuals or fear of falsified judgement by other participants. The wording of the questionnaire remained in Round 1 and Round 2 of e-Delphi were structured as close as possible to minimise biases due to misinterpretation likely to arise from the participants. Due to variation of the processes and methods that may be used in the development of guidelines, the researcher embarked on using the recommendations made by an international team of guideline developers and researchers, known as the Appraisal of Guidelines, Research and Evaluation (AGREE) Collaboration.⁹¹ This team developed a tool for assessing the process of guideline development and reporting of these guidelines.⁹¹ The tool developed consisted of 23 items comprising six quality-related domains.⁹¹ These domains were the scope and purpose, stakeholder involvement, the rigour of development, clarity of presentation, applicability, and editorial independence. The key changes from the original document from AGREE II involved refinements to the purpose, response scale and items of the instrument.⁹¹ After consensus was reached, the researcher sent a validation tool to the trauma specialists (doctors and nurses) to rate the quality of the developed guidelines. The rating scale validated the process and the guidelines by scoring the criteria suggested by the international body of researchers and guideline developers.¹²⁰ Medical doctors and trauma specialists' nurses working at trauma units with Lodox x-ray systems were proposed to have adequate experience in the above-mentioned areas of expertise and were identified as being able to give valuable inputs. The rating scale was explained, and the descriptions of the criteria were provided in the guideline instrument as outlined below. The ratings were as follows: strongly disagree = 1; disagree = 2; agree = 3 and strongly agree = 4 (see Annexure G).

3.7.2 Description of the framework used in the validation of the protocol guidelines

The framework below was derived from the AGREE II document.^{91,120} This framework has been used as a guide in the process of formulating and validating the guidelines and was recommended by the AGREE collaboration.⁹¹

3.7.2.1 Domain 1: Scope and purpose

This domain entails a description of the objective of the guideline, answers the research questions covered by developing the guidelines and indicates the population to be covered by these guidelines.¹²⁰ The objective of developing these guidelines was to develop a clinical protocol for adult chest imaging for use at trauma units for patients undergoing Lodox imaging. The protocol will guide the imaging of trauma patients, minimise the radiation dose, and reduce the cost of imaging. The researcher will answer the question “How can an adult chest imaging protocol be developed for patients undergoing Lodox imaging at trauma units?”. The targeted population to which these guidelines will be applied is approximately 59 308 690 which is the current population of South Africa (i.e., in 2020) according to the year 2020 United Nations data.¹²¹

3.7.2.2 Domain 2: Stakeholder involvement

This validation domain informs that guidelines must be developed by experts who are in the relevant profession.¹²⁰ Also, the views and preferences of the target population have to be sought and the targeted user of the guidelines need to be defined.¹²⁰ In this study, doctors and nurses who are trauma specialists and have worked at trauma units with the Lodox x-ray system were the experts. They are also the end-users of the chest imaging clinical protocol that will be developed.

3.7.2.3 Domain 3: Rigour of development.

This domain informs the systematic method that should be used in the search for evidence. Criteria for selecting the evidence has to be clearly described and strengths and limitations of the body of evidence need to be clearly described.¹²⁰ To minimise the variation of the processes and methods that may be used in the development of protocol guidelines, the proposed methods of formulating and verifying the protocol guidelines by AGREE Collaboration were used.^{91,120} For this study, the researcher used the consensus method (e-Delphi) to contact participants who were experts at trauma units where a Lodox x-ray system was used. Therefore, the information given was based on experience. The experts who were trauma specialists critically reviewed and validated the developed protocol guidelines and clinical protocol. There were no risks involved in

the use of the guidelines and protocol that was developed. The protocol developed will minimise radiation dose and medical bills on the patients while reducing the patient waiting time.

3.7.2.4 Domain 4: Clarity of presentation

This domain checks that the recommendations are specific and unambiguous, the different options for management of the condition or health issue are presented and key recommendations are easily identifiable.¹²⁰ The researcher presented the recommendations after developing the protocol for use during adult chest imaging for trauma patients with the Lodox x-ray system considering the financial and human resources abilities for hospitals in South Africa.

3.7.2.5 Domain 5: Applicability

This domain ensures that the guideline and protocol describe facilitators and barriers to its application.¹²⁰ Additionally, the guideline developed has provided advice/ tools on how the recommendations can be put into practice.¹²⁰ Researcher has presented these recommendations in Section 6.6. The potential implications of applying the recommendations for the developed clinical protocol have been considered in Section 6.5. The researcher presented the guidelines in a way that is easy to understand, adapt and apply at trauma units across hospitals that use Lodox x-rays systems in South Africa. This has been affected by using the English language, which is a medium of instruction in training institutions.

3.7.2.6 Domain 6: Editorial independence

This domain ensures that the views of the funding body have not influenced the content of the guideline.¹²⁰ Competing interests of guideline development group members have been recorded and addressed.¹²⁰ The researcher worked independently of the funding bodies in establishing the results. Additionally, the views and opinions of the participants were presented without bias. The researcher was assisted by experts e.g., radiologists, physicists, and a statistician in working to produce a credible result. This minimised any bias.

3.7.3 Determination of consensus in e-Delphi technique

A simple definition of consensus is 'a general agreement'.¹²² Differently stated, it refers to a general agreement by a group of people where all members agree about something.¹¹⁷ When using the Delphi technique, consensus within the different rounds is used to measure the agreement of the individual participants for each statement which then provides a group opinion and the extent to which participants agree with one another.³⁷ Generally, consensus is reached when the final set of statements is acceptable to all participants. Noteworthy is that consensus

differs for many studies based on Delphi technique so there is uncertainty about the best criteria to confirm consensus.^{37,123} The most frequent method that is used to determine consensus is the use of a median score above a predefined threshold and a high level of agreement between participants (for example, a median score above a certain level and a certain percentage of overall rating being in the lowest or highest tertile).

In this research, the lowest level of agreement was 1.00% and the highest level of agreement was 100.00%. The lower tertile was 1.00% with the middle tertile 50.00% and the upper tertile at 100.00%. Therefore, the median was 50.00% but the researcher used a 75.00% score as the percentage agreement for consensus in this study.³⁷ To reach consensus when using the Delphi technique, literature advises that statements that do not reach consensus should be included in subsequent rounds.³⁷ In this research, the lowest level of agreement was 1.00% and the highest level of agreement was 100.00%. The lower tertile was 1.00% with the middle tertile 50.00% and the upper tertile at 100.00%. Therefore, the median was 50.00% but the researcher used a 75.00% score as the percentage agreement for consensus in this study.³⁷ To reach consensus when using the Delphi technique, literature advises that statements that do not reach consensus should be included in subsequent rounds.³⁷ The researcher engaged the participants in two rounds only due to attrition but also used an extended duration of participation and used more reminders in the second round than the first round of e-Delphi. Review, critique, recommendations, editing, amendments of phrases and rating of the guidelines by the experts who validated the guidelines were adopted by the researcher to avoid biasness.

3.8 Summary

In Phase 1 of this research, Objective 1 assessed the diagnostic similarity between adult trauma chest images acquired using the full-body programme of a Lodox x-ray unit and a conventional x-ray unit for the same patient. The researcher used content analysis method to assess the diagnostic similarity between the acquired images.¹⁰⁰ The sample size constituted 278 images. One hundred and eighty-nine images were obtained from the conventional x-ray system and the same number from the Lodox x-ray system. This data was analysed and used to address this objective. Additionally, Objective 2 assessed the diagnostic quality of adult chest images acquired using the chest-dedicated imaging programme of the Lodox and those acquired using a conventional x-ray system about the level of size distortion, spatial resolution, contrast resolution, and image noise. In this objective 77 images were analysed. The outcome of the diagnostic quality of the chest images was linked to the results that were obtained after measuring the level of size distortion, spatial resolution, contrast resolution, and image noise to

identify the causes of any possible differences in the image quality. The sample size of the images constituted 38 images from a conventional x-ray system and 39 images from a Lodox x-ray system. These images were taken on conventional x-ray systems and Lodox x-ray systems at the five hospitals from which the data for Objective 1 and Objective 2 of Phase 1 was collected. The outcome for this data was presented to the experts for the development of clinical guidelines for Lodox imaging.

In Phase 2 of this research, trauma specialists who were nurses and doctors working at trauma units participated in the formulation and verification of the protocol guidelines. The researcher used the e-Delphi method to address Objective 1 and Objective 2. The e-Delphi method is a technique used to survey and collect data electronically from experts on a given theme.³⁹ Objective 1 involved the formulation of the clinical guidelines for adult patients undergoing chest imaging with Lodox x-ray systems. The verification of the referral pathway (imaging protocol) guidelines that were formulated on Objective 1 of Phase 2 for patients undergoing imaging with Lodox x-ray systems at trauma units was done in this phase. Verification involved the process of checking, confirming and making sure that the products met the intended specifications needed by the user.¹¹⁹ The researcher verified the developed protocol guidelines by validating the findings. The validation of the developed guidelines was performed using an e-Delphi method guided by the criteria developed by an international team of guidelines developers and researchers called the AGREE collaboration (AGREE. II).⁹¹

In the next chapter, the researcher presents the findings of the data that was collected using the research methods that have been discussed in this chapter.

CHAPTER 4: RESULTS PHASE ONE: DIAGNOSTIC SIMILARITY AND QUALITY OF IMAGES

4.1 Introduction

This chapter presents the results for Phase 1 on the diagnostic similarity between chest images of adult trauma patients acquired using the full-body programme of Lodox x-ray systems and the chest images acquired using conventional x-ray systems respectively concerning the level of distortion, spatial resolution, contrast resolution and image noise (dark noise). Two images of the same patient were compared for similarity, one acquired using a Lodox x-ray system and the other one acquired using a conventional x-ray system (see 3.5). The images were collected from five hospitals to address objectives 1 and 2. A checklist with variables was scored by radiologists on images for the same patient obtained from both imaging systems. The results obtained are represented graphically in this chapter (see 4.3).

4.2 Diagnostic similarities of chest images obtained from Lodox- and conventional x-ray systems

This section addresses the objective to assess the diagnostic similarity between chest images of adult trauma patients acquired using the full-body programme of Lodox x-ray systems and those acquired using conventional x-ray systems. A total of 278 images comprising 139 chest images obtained from the Lodox imaging system and 139 chest images obtained from conventional x-rays systems were evaluated by four radiologists. Two radiologists from public hospitals and two from private hospitals assessed the images. The data obtained are presented below.

4.3 Analysis of diagnostic similarities of the images

The checklist (see Annexure B) was printed and completed by two radiologists working at a state hospital. Their two private hospital counterparts completed the same checklist, using an online format that had been uploaded to the website (<https://wema.co.za/survey/>). During this research study, face-to-face data collection could not be done due to COVID-19 which is a highly infectious disease that caused a global pandemic in 2020 and 2021 with consequent instituted lockdown regulations.¹²⁴ The information from the checklists was captured on an Excel spreadsheet and imported into the R-core team software for data analysis..¹²⁵ One hundred and thirty-nine (139) chest images were acquired for each of the Lodox x-ray systems (using the full-body programme) and conventional x-ray systems. The acquired images were rated by the radiologists for diagnostic similarities using the checklist with coding which varies as follows: 1 indicating visible or good, 2 indicating partially visible or satisfactory, 0 indicating poor/invisible and -1 indicating absent.

4.4 Results for diagnostic similarity of the images

4.4.1 Artefacts and beam penetration

Table 4.1 represents the results from the comparison of visibility of artefacts and the quality of beam penetration for the two imaging systems. Radiologists identified and scored artefacts and penetration seen on the images (see Annexure B).

Table 4.1: Diagnostic similarities for artefacts and beam penetration

| % | Conventional x-ray systems (139) | | | | Lodox x-ray full-body programme (n=139) | | | |
|---|--|--------------------|-----------------|--------|---|--------------------|-----------------|---------|
| | Good visibility | Partial visibility | Poor visibility | Absent | Good visibility | Partial visibility | Poor visibility | Absent |
| | Diagnostic similarities for IMAGING ARTEFACTS | | | | | | | |
| | 20.86% | 2.88% | 0.00% | 76.26% | 0.00% | 0.00% | 0.00% | 100.00% |
| | Diagnostic similarities for PENETRATION | | | | | | | |
| | 73.38% | 25.90% | 0.72% | 0.00% | 99.28% | 0.72% | 0.00% | 0.00% |

In Table 4.1, images acquired with the conventional x-ray systems displayed exposure artefacts and chevron artefacts on 29 (20.86%) images with good visibility. Of the total images (139), 4 (2.88%) artefacts were rated as partly visible and 106 (76.26%) displayed no artefacts. The images acquired with the Lodox x-ray systems did not display any exposure/chevron artefacts on 139 (100.00%) of the images.

For the images acquired with conventional x-ray systems, 102 (73.38%) images had good penetration, 36 (25.90%) images had satisfactory penetration while 1 (0.72%) image was poorly penetrated. The 138 (99.28%) Lodox images, had good beam penetration and 1 (0.72%) image had satisfactory beam penetration.

The p-values on a null hypothesis test $p < 0.0001$ on artefacts and $p < 0.0001$ on the penetration of the x-ray beam indicate that there is significance difference between conventional x-ray system and Lodox x-ray system images.

4.4.2 The trachea, bronchial and vascular patterns

Table 4.2 shows the comparison between the visibility of the normal anatomy of the trachea, bronchial and vascular patterns observed using the two categories of images.

Table 4.2: Diagnostic similarities for the trachea, bronchial and vascular patterns

| % | Conventional x-ray systems (n=139) | | | | Lodox x-ray FULL-BODY PROGRAMME (n=139) | | | |
|---|---|--------------------|-----------------|--------|---|--------------------|-----------------|--------|
| | Good visibility | Partial visibility | Poor visibility | Absent | Good visibility | Partial visibility | Poor visibility | Absent |
| | Diagnostic similarities for LUNG PARENCHYMA | | | | | | | |
| | 84.17% | 15.83% | 0.00% | 0.00% | 100.00% | 0.00% | 0.00% | 0.00% |
| | Diagnostic similarities for PULMONARY VASCULATURE | | | | | | | |
| | 82.01% | 17.99% | 0.00% | 0.00% | 100.00% | 0.00% | 0.00% | 0.00% |
| | Diagnostic similarities for. TRACHEOBRONCHIAL STRUCTURES | | | | | | | |
| | 64.02% | 28.78% | 3.60% | 3.60% | 99.28% | 0.72% | 0.00% | 0.00% |

The trachea, bronchial and vascular patterns: Table 4.2 indicates that lung parenchyma was displayed in 117 (84.17%) conventional x-ray images with good visibility and 22 (15.83%) images with partial visibility. All 139 (100.00%) Lodox images were rated with good visibility. For the conventional systems, the pulmonary vasculature was scored with good visibility for 114 (82.01%) images, while 25 (17.99%) images were scored with partially visible pulmonary vasculature. All the Lodox images (139, 100.00%) were rated with good visibility for pulmonary vasculature.

The anatomy of tracheobronchial structure: Eighty-nine (89, 64.02%) conventional images presented good visibility for tracheobronchial structures. Forty (40, 28.78%) images were rated as showing partially visible tracheobronchial structures and on 5 (3.60%) images the tracheobronchial structures were absent. The same percentage of tracheobronchial structures were poorly visible. For the Lodox images, tracheobronchial structures had a good visibility rating for 138 (99.28%) of the images while 1 (0.72%) image was rated partially visible for tracheobronchial structures.

The p-values for a null hypothesis test $p < 0.0001$ on the anatomy of lung parenchyma, $p < 0.0001$ on the anatomy of pulmonary vasculature and $p < 0.0001$ on anatomy of tracheobronchial structure indicate there is significant difference between conventional x-ray system and Lodox x-ray system images.

4.4.3 The lung parenchyma

The section below presents the results on the visibility of the lung parenchyma for the images acquired using both imaging systems. The visibility of lung parenchyma diseases is presented in

two categories: interstitial (infiltrative) disease (Table 4.3) and air space (alveolar) disease (Table 4.4).

Table 4.3: Diagnostic similarities for the lung parenchyma (infiltrative) disease

| | Conventional x-ray systems (n=139) | | | | Lodox x-ray system (FULL-BODY PROGRAMME) (n=139) | | | |
|----------|--|--------------------|-----------------|--------|--|--------------------|-----------------|---------|
| | Good visibility | Partial visibility | Poor visibility | Absent | Good visibility | Partial visibility | Poor visibility | Absent |
| % | Diagnostic similarities for BULLAE | | | | | | | |
| | 2.90% | 0.00% | 0.00% | 97.10% | 0.00% | 0.00% | 0.00% | 100.00% |
| | Diagnostic similarities for. INTERSTITIAL CHANGES | | | | | | | |
| | 17.27% | 4.31% | 0.00% | 78.42% | 19.42% | 0.00% | 0.00% | 80.58% |
| | Diagnostic similarities for LUNG CONTUSION | | | | | | | |
| | 17.27% | 6.47% | 2.88% | 73.38% | 0.00% | 0.00% | 0.00% | 100.00% |
| | Diagnostic similarities for LUNG. INFILTRATES | | | | | | | |
| | 62.59% | 6.47% | 0.00% | 30.94% | 65.22% | 0.00% | 0.00% | 34.78% |
| | Diagnostic similarities for NODULES | | | | | | | |
| | 14.39% | 0.72% | 0.72% | 84.17% | 25.90% | 0.00% | 0.00% | 74.10% |

Bullae: The conventional images displayed bullae with good visibility on 4 (2.90%) images and 134 (97.10%) images, bullae were absent. The total number of conventional images (N) on this question was 138. On all the Lodox images (N=139) (100%), bullae were absent.

Interstitial changes/opacities: Twenty-four (24, 17.27%) conventional images display good visibility for interstitial opacities; 6 images had interstitial changes that were partially visible (4.31%); and for 109 (78.42%) images interstitial opacities were absent (N=139). The Lodox images displayed interstitial changes on 27 (19.42%) images with good visibility while these changes were absent on 112 (80.58%) images (N=139).

Pulmonary contusion: Lung contusion was rated with good visibility on 24 (17.27%) conventional images. On 9 (6.47%) images, lung contusion was rated as partially visible, poorly visible on 4 (2.88%), and absent on 101 (73.38%). All the Lodox x-images (139, 100.00%) did not display lung contusion. On both imaging systems, the number of images was 139.

Lung infiltrates: The conventional x-ray images displayed lung infiltrates with good visibility on 87 (62.59%) images. For 9 (6.47%) images, lung infiltrates were rated partially visible, and for 43

(30.94%) images lung infiltrates were absent. The Lodox images displayed lung infiltrates on 90 (65.22%) images with good visibility while for 48 (34.78%) images, lung infiltrates were absent. The total number of images (N) on the Lodox x-ray system was 138.

Nodules were well-visualised (good visibility) on 20 (14.39%) conventional x-ray images, partially visualised on 1 (0.72%) image and poorly visualised on another image 1 (0.72%). Nodules were seen on 117 (84.17%) images. The Lodox images displayed nodules with good visibility on 36 (25.90%) images while on 103 (74.10%) images nodules were absent. On both imaging systems, the number (N) of images was 139.

- Diagnostic similarities for bullae p-value = 0.0439 indicate a significant difference on the images obtained from the two-imaging system.
- Diagnostic similarities for interstitial changes p-value = 0.7869 indicate no significant difference between images obtained from the two imaging systems.
- Diagnostic similarities for lung contusion p-Value < 0.0001 indicate a significant difference between images obtained from the two-imaging system.
- Diagnostic similarities for lung infiltrates p-value = 0.9494 indicate no significant difference
- Diagnostic similarities for nodules p-value = 0.0327 indicate a significant difference between images obtained from conventional x-ray system and lodox x-ray system.

Table 4.4: Diagnostic similarities for the lung parenchyma (alveolar disease)

| % | Conventional x-ray systems(n=139) | | | | Lodox x-ray system (FULL-BODY PROGRAMME) (n=139) | | | |
|---|---|--------------------|-----------------|--------|--|--------------------|-----------------|---------|
| | Good visibility | Partial visibility | Poor visibility | Absent | Good visibility | Partial visibility | Poor visibility | Absent |
| | Diagnostic similarities for. AIR BRONCHOGRAM | | | | | | | |
| | 32.35% | 1.47% | 0.00% | 66.18% | 48.92% | 0.00% | 0.00% | 51.08% |
| | Diagnostic similarities for GRANULAR GLASS OPACITY | | | | | | | |
| | 14.07% | 2.96% | 0.00% | 82.96% | 0.00% | 0.00% | 0.00% | 100.00% |

Air bronchograms had good visibility on 44 (32.35%) conventional images. Two (1.47%) images displayed air bronchograms with partial visibility and they were absent on 90 (66.18%) images. The total number of images on the conventional x-ray system was 136. For the Lodox images, air bronchograms were displayed with good visibility on 68 (48.92%) images while on 71 (51.08%)

images, the air bronchograms were absent. The Lodox x-ray system had a total number of 139 images.

Granular glass opacity: The conventional images displayed a granular glass pattern on 19 (14.07%) images with good visibility. Four (2.96%) images displayed a granular glass pattern with partial visibility while for 111 (82.96%) images a granular glass pattern was absent. The total number of images from the conventional x-ray system was 134. A granular glass pattern was not visible on any of the Lodox images (138, 100%).

The P-value for a null hypothesis test on diagnostic similarities for air bronchogram (p-value = 0.0081) and granular glass opacity (p-value = 0.0001) indicates a significant difference between images obtained from conventional x-ray system and Lodox x-ray system.

4.4.4 The pleura

Table 4.5 presents the results on the similarity of disorders of the pleura for the two imaging systems.

Table 4.5: Similarity of disorders of the pleura for the two imaging systems

| % | Conventional x-ray systems (n=139) | | | | Lodox x-ray FULL-BODY PROGRAMME (n=139) | | | |
|---|---|--------------------|-----------------|--------|---|--------------------|-----------------|---------|
| | Good visibility | Partial visibility | Poor visibility | Absent | Good visibility | Partial visibility | Poor visibility | Absent |
| | Diagnostic similarities for EFFUSIONS | | | | | | | |
| | 27.34% | 5.04% | 1.44% | 66.19% | 21.58% | 0.00% | 0.00% | 78.42% |
| | Diagnostic similarities for PNEUMOTHORAX | | | | | | | |
| | 14.39% | 6.47% | 2.88% | 73.38% | 0.00% | 0.00% | 0.00% | 100.00% |
| | Diagnostic similarities for SURGICAL EMPHYSEMA | | | | | | | |
| | 14.49% | 0.72% | 2.17% | 82.61% | 18.71% | 0.00% | 0.00% | 81.29% |

Effusions: The images acquired using conventional x-ray systems displayed pleural effusion on 38 (27.34%) with good visibility. Seven (7, 5.04%) images were rated with partial visibility while 2 (1.44%) displayed poor visibility for effusion. For 92 (66.19%) images, pleura effusion was absent. The Lodox images displayed pleural effusion on 30 (21.58%) images with good visibility while on 109 (78.42%) Lodox images, pleural effusion was absent.

Pneumothorax: 20 (14.39%) of the conventional images were rated with good visibility for pneumothorax; 9 (6.47%) images had partial visibility; 3 (2.16%) images had poor visibility and on 107 (76.98%) images, a pneumothorax was absent. Eight (5.76%) Lodox images displayed pneumothorax with good visibility while on 131 (94.24%) a pneumothorax was absent.

Surgical emphysema: Surgical emphysema was rated with good visibility on 20 (14.49%) conventional images. On 1 (0.72%) image, surgical emphysema was partially visible; 3 (2.17%) displayed poor visibility and for 114 (82.61%) images, surgical emphysema was absent. The total number of conventional x-ray images was 138. The Lodox images displayed surgical emphysema on 26 (18.71%) images with good visibility while on 113 (81.29%) images surgical emphysema was absent. The total number of images on Lodox x-ray system images was 139.

The p-value for a null hypothesis test for diagnostic similarities for effusions (p-value =0.0452) and pneumothorax (p-value <0.0001) indicates a significant difference between images obtained from conventional x-ray system and those obtained from Lodox x-ray system. The diagnostic similarities for surgical emphysema (p-value = 0.6898) indicated that no significant difference was found between the images obtained from the conventional x-ray system and those obtained from the Lodox x-ray system.

4.4.5 Mediastinal structures

Table 4.6 presents the results on the visibility of mediastinal structures for the two imaging systems.

Table 4.6: Diagnostic similarities for the mediastinal structures

| % | Conventional x-ray systems(n=139) | | | | Lodox x-ray system (FULL-BODY PROGRAMME) (n=139) | | | |
|---|--|--------------------|-----------------|--------|--|--------------------|-----------------|---------|
| | Good visibility | Partial visibility | Poor visibility | Absent | Good visibility | Partial visibility | Poor visibility | Absent |
| | Diagnostic similarities for the CARDIAC. AND. AORTA OUTLINE | | | | | | | |
| | 80.43% | 17.39% | 0.72% | 1.45% | 99.28% | 0.00% | 0.00% | 0.72% |
| | Diagnostic similarities for MEDIASTINAL. INJURIES (N=139) | | | | | | | |
| | 1.45% | 1.45% | 0.72% | 96.38% | 0.00% | 0.00% | 0.00% | 100.00% |
| | Diagnostic similarities for PNEUMOMEDIATINUM (n=138) | | | | | | | |
| | 0.72% | 2.90% | 2.17% | 94.20% | 1.45% | 0.00% | 0.00% | 98.55% |

Cardiac and aorta outline visualised: The conventional images displayed the cardiac and aorta outline on 111 (80.43%) images with good visibility, on 24 (17.39%) images with partial visibility and 1 (0.72%) image with poor visibility. On 2 (1.45%) images, the cardiac and aorta outline was absent. The Lodox images displayed good visibility of the cardiac and aorta outline on 138 (99.28%) images while on 1 (0.72%) images, the cardiac and aorta outline was absent. The total number of conventional x-ray system images was 138 while that from Lodox x-ray system images was 139.

Mediastinal injuries were displayed with good visibility on 2 (1.45%) conventional images; 2 (1.45%) images had partial visibility while 1 (0.72%) image was rated with poor visibility. On 133 (96.38%) images, mediastinal injuries were absent. Mediastinal images were absent on all the Lodox images (139, 100%). The total number of conventional x-ray system images was 138 while that from Lodox x-ray system images was 139.

Pneumomediastinum: The conventional images displayed pneumomediastinum on 1 (0.72%) image with good visibility; 4 (2.90%) images showed partial visibility; 3 (2.17%) images were rated with poor visibility and on 130 (94.20%) images, pneumomediastinum was absent. The Lodox images displayed pneumomediastinum on 2 (1.45%) images with good visibility while on 136 (98.55%) images, pneumomediastinum was absent. The total number of conventional x-ray system images and that of Lodox x-ray system images was 138 each.

The p-values for a null hypothesis test for diagnostic similarities on the cardiac and aorta outline (p-value < 0.0001), mediastinal injuries (p-value = 0.0240) indicate a significant difference between the images obtained from the two-imaging system. The diagnostic similarities for pneumomediastinum p-value = 0.0582 indicate no significant difference between the images obtained from conventional x-ray system and that from Lodox x-ray system.

4.4.6 The thoracic cage

Table 4.7 presents the results on the visibility of structures of the thoracic cage for both imaging systems.

Table 4.7: Diagnostic similarities for the structures of the thoracic cage

| | Conventional x-ray systems(n=139) | | | | Lodox x-ray system (FULL-BODY PROGRAMME) (n=139) | | | |
|----------|--|--------------------|-----------------|--------|---|--------------------|-----------------|---------|
| | Good visibility | Partial visibility | Poor visibility | Absent | Good visibility | Partial visibility | Poor visibility | Absent |
| % | Diagnostic similarities for BREAST TISSUE/MAMMARY TISSUE | | | | | | | |
| | 22.06% | 7.35% | 0.00% | 70.59% | 21.58% | 0.00% | 0.00% | 78.42% |
| | Diagnostic similarities for the DIAPHRAGMS | | | | | | | |
| | 65.47% | 31.65% | 0.00% | 2.88% | 82.01% | 17.27% | 0.72% | 0.00% |
| | Diagnostic similarities for EXTRA-LUMINAL AIR | | | | | | | |
| | 3.62% | 0.00% | 0.72% | 95.65% | 2.88% | 0.00% | 0.00% | 97.12% |
| | Diagnostic similarities for FRACTURES OF THE RIBS AND CLAVICLES | | | | | | | |
| | 19.42% | 4.32% | 0.00% | 76.26% | 12.23% | 0.00% | 0.00% | 87.77% |
| | Diagnostic similarities for THORAC SOFT TISSUE | | | | | | | |
| | 73.19% | 12.32% | 0.00% | 14.49% | 99.28% | 0.00% | 0.00% | 0.72% |
| | Diagnostic similarities for FRACTURES OF THE THORACIC SPINE | | | | | | | |
| | 0.00% | 0.74% | 2.22% | 97.04% | 0.00% | 0.00% | 0.00% | 100.00% |
| | Diagnostic similarities for the THORACIC SPINE LESIONS | | | | | | | |
| | 0.00% | 0.00% | 1.08% | 97.84% | 0.00% | 0.00% | 0.00% | 100.00% |
| | Diagnostic similarities for VERTEBRAL BODY OR SPINOUS FRACTURE | | | | | | | |
| | 0.00% | 0.00% | 2.19% | 97.81% | 0.00% | 0.00% | 0.00% | 100.00% |

Breast/Mammary tissue: The conventional x-ray systems displayed the mammary tissue on 30 (22.06%) images with good visibility, on 10 (7.35%) images with partial visibility while on 96 (70.59%) images the mammary tissue was absent. In comparison, the Lodox images displayed the mammary tissue on (30, 21.58%) images with good visibility, but on 109 (78.42%) images the mammary tissue was absent. The total number of conventional x-ray system images was 136 while that for Lodox x-ray system images was 139.

The diaphragms: Ninety-one (91, 65.47%) conventional images were displayed with good visibility; on 44 (31.65%) images, the diaphragms were partially visible; and on 4 (2.88%) images, the diaphragm was absent. The Lodox images displayed the diaphragms on 114 (82.01%) images with good visibility, 24 (17.27%) images with partial visibility and 1 (0.72%) image with poor visibility. The total number of conventional x-ray system images and that for Lodox x-ray system images was 139 each.

Extra-luminal air was displayed on 5 (3.62%) conventional images with good visibility, 1 (0.72%) had poor visibility while on 132 (95.65%) images extra-luminal air was absent. The Lodox images displayed extra-luminal air with good visibility on 4 (2.88%) images with an absence of extra-luminal air on 135 (97.12%) images. The total number of conventional x-ray system images was 138 while that for Lodox x-ray system images was 139.

Fracture of ribs and clavicles: The conventional images showed fractures of the ribs and clavicles on 27 (19.42%) images with good visibility. Six (6, 4.32%) images were rated with partial visibility, while 106 (76.26%) images did not show fractures of ribs and clavicles. The Lodox images displayed fractures of ribs and clavicles on 17 (12.23%) images with good visibility while 122 (87.77%) images of rib- and clavicle fractures were absent. The total number of conventional x-ray system images and that for Lodox x-ray system images was 139 each.

Soft tissues of the thoracic wall: The images acquired using a conventional x-ray system displayed soft tissue of thoracic cage on 101 (73.19%) of images with good visibility; 17 (12.32%) images were partially visible, while 20 (14.49%) did not display soft tissue of thoracic wall. On the other hand, images acquired using a Lodox x-ray system displayed soft tissue of thoracic wall on 138 (99.28%) images with good visibility whereas 1 (0.72%) image did not display soft tissues of the thoracic wall. On both imaging systems, there was a total number of 138 images each.

Fracture of the thoracic spine: The images acquired using conventional x-ray systems displayed fractures of thoracic spines on 1 (0.74) image. The visibility was rated as “partially visible”, 3 (2.22%) images were rated as “poorly visible”, while 131 (97.04%) images did not display thoracic spine fracture. The images acquired using the Lodox x-ray system did not show fractures of the thoracic spine (139, 100%). The total number of conventional x-ray system images was 135 while that for Lodox x-ray system images was 139.

Thoracic spine lesion: The images acquired using conventional x-ray systems displayed thoracic spine lesions on 3 (1.08%) as poorly visible while 136 (97.84%) images did not display thoracic spine lesions. Thoracic spine lesions were absent on all images acquired using Lodox x-ray system images (139, 100.00%). The total number of conventional x-ray system images and that for Lodox x-ray system images was 139 each.

Fracture of vertebral body and spinous processes fracture: On images acquired using a conventional x-ray system, fractures of the vertebral bodies and spinous processes were poorly visible on 3 (2.19%) images and absent on 134 (97.81%) images. On the other hand, no images acquired using Lodox x-ray system images (139, 100%) showed fractures of the vertebral bodies

or spinous processes. The total number of conventional x-ray system images and that for Lodox x-ray system images was 139 each.

The p-values for a null hypothesis test $p = 0.2385$ on mammary glands, $p = 0.0828$ for thoracic spine lesion, $p = 0.0807$ on fracture of vertebral body and spinous process fracture and $p = 0.5202$ on extra luminal air indicate no significant difference between images obtained from the conventional x-ray system and those obtained from the Lodox x-ray system. On the other hand, p-values of $p < 0.0001$ on soft tissues of thoracic wall, $p = 0.0417$ on fracture of thoracic spine, $p = 0.0240$ on fractures of ribs or clavicle and $p = 0.0015$ on diaphragm indicate a significant difference between images obtained from the conventional x-ray system and those obtained from the Lodox x-ray system.

4.4.7 Discussion of the results for the comparison of diagnostic similarities for chest images (conventional x-ray systems and Lodox full-body programme)

The Lodox x-ray systems had better penetration than the conventional x-ray systems. Also, the Lodox x-ray systems seemed better than the conventional x-ray systems in showing pulmonary vasculature, lungs parenchyma, lung infiltrates, thoracic cage soft tissue outlines, trachea and proximal bronchi, pulmonary vessels periphery of the lung, cardiac and aorta outline, retro-cardiac and mediastinum outline, thoracic spine, vertebral bodies and disc spaces, surgical emphysema, nodules, interstitial pathologies, air bronchograms and diaphragms. On the other hand, the conventional x-ray systems were better than the Lodox x-ray systems at showing lung contusions, extra-luminal air, granular glass opacities, bullae, mediastinal injuries and fractures of the clavicle and ribs. Overall, the Lodox x-ray system seems to show most of the features better than the conventional x-ray systems.

4.5 Diagnostic quality (Conventional and Lodox Chest Dedicated Programme Images)

This section presents the results for Objective 2 of Phase 1 where the diagnostic quality of adult chest images acquired using the Lodox chest-dedicated imaging programme compared to images acquired using a conventional x-ray system concerning the level of distortion, spatial resolution, contrast resolution and image noise. Thirty-nine (39) images were obtained using Lodox- x-ray systems and thirty-eight (38) images using conventional x-rays systems. A patient who was referred for conventional CXR by a physician underwent an additional image that was performed using a Lodox x-ray system. Therefore, each patient had a chest image performed using both imaging systems. These images were reported by the consultant radiologists (see 3.5.2.1).

4.5.1 Data analysis on diagnostic quality of images

Thirty-eight (38) conventional chest images and thirty-nine (39) Lodox chest images were evaluated by the radiologists and variables on the checklist were rated by assigning a code. These codes varied from 1 representing Visible or Good, 2 representing partially visible or satisfactory, 0 representing poor/invisible, and -1 representing absent. The radiologists' coded checklists were captured using Microsoft Excel and R-core team software for data analysis.¹²⁵. The outcomes of the data analysis are presented under the following subheadings.

4.5.2 Artefacts and Beam penetration

Table 4.8 presents the results on the visibility of artefacts and the quality of beam penetration as was observed on the images acquired using the Lodox chest-dedicated programme and conventional x-ray systems.

Table 4.8: Diagnostic quality for imaging artefacts and beam penetration

| % | Conventional systems (N=38) | | | | Lodox chest-dedicated programme (N=39) | | | |
|---|--|--------------------|-----------------|--------|--|--------------------|-----------------|--------|
| | Good visibility | Partial visibility | Poor visibility | Absent | Good visibility | Partial visibility | Poor visibility | Absent |
| | Diagnostic similarities for. IMAGING. ARTEFACTS | | | | | | | |
| | 10.53% | 0.00% | 2.63% | 86.84% | 2.56% | 0.00% | 0.00% | 97.44% |
| | Diagnostic similarities for PENETRATION | | | | | | | |
| | 97.37% | 0.00% | 2.63% | 0.00% | 97.44% | 2.56% | 0.00% | 0.00% |

Thirty-three 33 (86.84%) conventional x-ray system images displayed no artefacts while 38 (97.44%) Lodox x-ray system images displayed no artefacts. Four 4 (10.53%) conventional x-ray system images and 1 (2.56%) Lodox x-ray system image displayed artefacts with a good visibility.

The conventional images displayed good x-ray beam penetration for 37 (97.3%) images while Lodox x-ray system images displayed a good beam penetration (38, 97.44%). For both systems, only one image displayed suboptimal (partial) penetration.

The p-value for a null hypothesis test of $p=0.0892$ on exposure and chevron exposure artefacts and a p-value of $p=0.9852$ on the penetration of the x-ray beam indicate that there was no significant difference between images obtained from the conventional x-ray system and the Lodox x-ray system images.

4.5.3 The trachea, bronchial- and vascular patterns

Table 4.9 presents the results on the visibility of the normal anatomy of the trachea, bronchial and vascular patterns on the conventional x-ray systems images and the Lodox x-ray system images.

Table 4.9: Diagnostic quality for the trachea, bronchial and vascular patterns

| % | Conventional systems (N=38) | | | | Lodox chest-dedicated programme (N=39) | | | |
|---|---|--------------------|-----------------|--------|--|--------------------|-----------------|--------|
| | Good visibility | Partial visibility | Poor visibility | Absent | Good visibility | Partial visibility | Poor visibility | Absent |
| | Diagnostic similarities for PULMONARY VASCULATURE | | | | | | | |
| | 97.37% | 2.63% | 0.00% | 0.00% | 97.44% | 2.56% | 0.00% | 0.00% |
| | Diagnostic similarities for. TRACHEOBRONCHIAL STRUCTURES | | | | | | | |
| | 100.00% | 0.00% | 0.00% | 0.00% | 100.00% | 0.00% | 0.00% | 0.00% |

Pulmonary vasculature: The conventional images displayed the anatomy of the pulmonary vasculature on 37 (97.37%) images while the Lodox images displayed the same structures on 38 (97.44%) images, both with good visibility. For both systems, only one image was rated as partially visible. Both systems displayed trachea-bronchial structures on 100% of the images with good visibility.

Tracheobronchial structures: All images obtained from both conventional x-ray systems and Lodox x-ray systems displayed tracheobronchial structures with good visibility.

The p-values for a null hypothesis ($p = 0.3236$) on the anatomy of lungs parenchyma, and ($p = 0.9999$) on anatomy of pulmonary vasculature indicate that there was no significant difference between the conventional x-ray system and the Lodox x-ray system images. On the anatomy of tracheobronchial structures, no p-value was assigned because 100.00% of images were similar.

4.5.4 The lung parenchyma

This section presents the results on diagnostic quality (visibility of structures) for the lung parenchyma for conventional images and Lodox chest-dedicated programme images under two categories, namely interstitial (infiltrative) disease (Table 4.10) and air space (alveolar) disease (Table 4.10 and Table 4.11).

Table 4.10: Diagnostic quality for the lung parenchyma (infiltrative disease)

| | Conventional systems (N=38) | | | | Lodox CHEST-DEDICATED PROGRAMME (N=39) | | | |
|---|--|--------------------|-----------------|---------|--|--------------------|-----------------|---------|
| | Good visibility | Partial visibility | Poor visibility | Absent | Good visibility | Partial visibility | Poor visibility | Absent |
| % | Diagnostic similarities for BULLAE | | | | | | | |
| | 2.63% | 0.00% | 0.00% | 97.37% | 0.00% | 0.00% | 0.00% | 100.00% |
| | Diagnostic similarities for. INTERSTITIAL CHANGES | | | | | | | |
| | 2.63% | 0.00% | 0.00% | 97.37% | 17.95% | 0.00% | 0.00% | 82.05% |
| | Diagnostic similarities for LUNG CONTUSION | | | | | | | |
| | 0.00% | 0.00% | 0.00% | 100.00% | 0.00% | 0.00% | 0.00% | 100.00% |
| | Diagnostic similarities for LUNG. INFILTRATES | | | | | | | |
| | 60.53% | 0.00% | 0.00% | 39.47% | 58.97% | 0.00% | 0.00% | 41.03% |
| | Diagnostic similarities for NODULES | | | | | | | |
| | 15.79% | 0.00% | 0.00% | 84.21% | 35.90% | 0.00% | 0.00% | 64.10% |

Bullae: On the conventional x-ray system images, bullae were absent on 37 (97.37%) and presented with good visibility on 1 (2.63%) images. Bullae were absent on all the Lodox x-ray system images (39, 100%).

Interstitial changes (Interstitial opacities): While conventional x-ray systems displayed interstitial changes with good visibility on 1 (2.63%) images, the Lodox x-ray system displayed interstitial changes with good visibility on 7 (17.97%) images. Interstitial changes were absent on 37 (97.37%) conventional x-ray system images and on 32 (82.05%) Lodox x-ray systems images.

Lung infiltrate had good visibility on 23 (60.53%) conventional x-ray system images and 23 (58.97%) Lodox x-ray system images but absent on 15 (39.47%) conventional x-ray system images and 16 (41.03%) Lodox x-ray system.

Nodules were well-visualised on 6 (15.79%) conventional x-ray system images and on 14 (35.90%) Lodox x-ray system images. Additionally, nodules were absent on 25 (64.10%) Lodox x-ray system images and on 32 (84.21%) conventional x-ray system images.

The p-values for null hypothesis $p = 0.8950$ on lung infiltrates (interstitial) and $p = 0.3235$ on bullae indicate that there was no significant difference between the conventional x-ray system and the Lodox x-ray system images. On the other hand, there was a significant difference

identified on interstitial changes interstitial opacities ($p = 0.0294$) and nodules ($p = 0.0464$). There was no p-value assigned on the pulmonary contusion because 100.00% of images from conventional x-ray system and Lodox x-ray system were similar.

Table 4.11: Diagnostic quality of the lung parenchyma (alveolar disease)

| % | Conventional systems (N=38) | | | | Lodox CHEST-DEDICATED PROGRAMME (N=39) | | | |
|---|---|--------------------|-----------------|---------|--|--------------------|-----------------|---------|
| | Good visibility | Partial visibility | Poor visibility | Absent | Good visibility | Partial visibility | Poor visibility | Absent |
| | Diagnostic similarities for AIR BRONCHOGRAM | | | | | | | |
| | 31.58% | 0.00% | 0.00% | 68.42% | 33.33% | 0.00% | 0.00% | 66.67% |
| | Diagnostic similarities for GRANULAR GLASS OPACITY | | | | | | | |
| | 0.00% | 0.00% | 0.00% | 100.00% | 0.00% | 0.00% | 0.00% | 100.00% |

Air bronchograms were well-visualised on 12 (31.58) conventional x-ray system images and on 13 (33.33%) Lodox x-ray system images. Air bronchograms patterns were absent on 26 (68.42%) conventional x-ray system images and on 26 (66.67%) Lodox x-ray system images.

Granular glass opacities were absent on all images of both the conventional x-ray system and the Lodox x-ray system.

The p-value for null hypothesis test $p = 0.8752$ on air bronchogram indicates that there was no significant difference between images obtained from the conventional x-ray system and the Lodox x-ray system images. On the other hand, there was no p-value assigned on granular glass opacity because 100.00% of the conventional x-ray system and the Lodox x-ray system images were similar.

4.5.5 The disorders of the pleura

The visualisation of disorders of the pleura on the images of the two imaging systems is presented in Table 4.12.

Table 4.12: Diagnostic quality for the pleura

| | Conventional systems (N=38) | | | | Lodox CHEST-DEDICATED PROGRAMME (N=39) | | | |
|---|---|--------------------|-----------------|--------|--|--------------------|-----------------|--------|
| | Good visibility | Partial visibility | Poor visibility | Absent | Good visibility | Partial visibility | Poor visibility | Absent |
| % | Diagnostic similarities for EFFUSIONS | | | | | | | |
| | 34.21% | 0.00% | 0.00% | 65.79% | 51.28% | 0.00% | 0.00% | 48.72% |
| | Diagnostic similarities for PNEUMOTHORAX | | | | | | | |
| | 10.53% | 0.00% | 0.00% | 89.47% | 12.82% | 0.00% | 0.00% | 87.18% |
| | Diagnostic similarities for SURGICAL EMPHYSEMA | | | | | | | |
| | 16.22% | 0.00% | 0.00% | 83.78% | 17.95% | 0.00% | 0.00% | 82.05% |

Effusion: Pleural effusion was displayed with good visibility on 13 (34.21%) conventional x-ray system images and on 20 (51.28%) Lodox x-ray system images. Pleural effusion was absent on 25 (65.79%) conventional x-ray system images and on 19 (48.72%) Lodox x-ray system images.

Pneumothorax had good visibility on only 4 (10.53%) conventional x-ray system images and on 5 (12.82%) Lodox x-ray system images. Pneumothorax was absent on most images of both systems; conventional x-ray system (34, 89.47%) images and Lodox x-ray system (34, 87.18%) images.

Surgical emphysema: Surgical emphysema was absent on 31 (83.78%) conventional x-ray system images and on 32 (82.05%) Lodox x-ray system images. This pathology was well-visualised on only 6 (16.22%) conventional x-ray system images and 7 (17.95%) Lodox x-ray system images.

The p-values on the null hypothesis test $p=0.7626$ on pneumothorax, $p=0.1342$ on pleural effusion and $p=0.8484$ on surgical or subcutaneous emphysema indicate that there was no significant difference between the conventional x-ray system and the Lodox x-ray system images on pneumothorax and surgical/ subcutaneous emphysema

4.5.6 Mediastinal structures and associated pathologies.

The visibility of mediastinal structures for both imaging systems has been presented in Table 4.13 in this section.

Table 4.13: Diagnostic quality of the mediastinal structures

| % | Conventional systems (N=38) | | | | Lodox CHEST-DEDICATED PROGRAMME (N=39) | | | |
|---|--|--------------------|-----------------|---------|--|--------------------|-----------------|---------|
| | Good visibility | Partial visibility | Poor visibility | Absent | Good visibility | Partial visibility | Poor visibility | Absent |
| | Diagnostic similarities for the CARDIAC. AND. AORTA OUTLINE | | | | | | | |
| | 84.47% | 10.53% | 0.00% | 0.00% | 89.74% | 7.69% | 2.56% | 0.00% |
| | Diagnostic similarities for MEDIASTINAL. INJURIES | | | | | | | |
| | 0.00% | 0.00% | 0.00% | 100.00% | 0.00% | 0.00% | 0.00% | 100.00% |
| | Diagnostic similarities for PNEUMOMEDIATINUM | | | | | | | |
| | 2.63% | 0.00% | 0.00% | 97.37% | 5.13% | 0.00% | 0.00% | 94.87% |

Cardiac and aorta outline: The cardiac and aorta outlines were well-visualised for both conventional- images (34; 89.47%) and Lodox (35; 89.74%) images. Four (10.53%) conventional x-ray system images and three (7.69%) Lodox x-ray system images were rated as partially visible. Lodox x-ray system had one (2.56%) image that showed cardiac and aorta outline as poorly visible.

Mediastinal injuries: For both systems, mediastinal injuries were absent on all the images.

Pneumomediastinum: Both conventional x-ray system (37; 97.37%) and Lodox images (37; 94.87%) images displayed no pneumomediastinum (absent) while on 1 (2.63%) conventional x-ray system and 2 (5.13%) Lodox (2, 5.13%) images pneumomediastinum was well-visualised.

The-p-values on the null hypothesis test, $p = 0.9999$ on cardiac and aorta outline and $p = 0.5843$ on pneumomediastinum indicate that there was no significant difference between images of cardiac aorta and pneumomediastinum obtained from the conventional x-ray system and those from the Lodox x-ray system. However, there was no p-value was assigned to the mediastinal injuries because images from the conventional x-ray system and those from the Lodox x-ray system were 100.00% similar.

4.5.7. The thoracic cage

Table 4.14 presents the results on the visibility of structures of the thoracic cage for the two systems.

Table 4.14: Diagnostic quality of the structures of the thoracic cage

| | Conventional systems (N=38) | | | | Lodox CHEST-DEDICATED PROGRAMME (N=39) | | | |
|---|--|--------------------|-----------------|---------|--|--------------------|-----------------|---------|
| | Good visibility | Partial visibility | Poor visibility | Absent | Good visibility | Partial visibility | Poor visibility | Absent |
| % | Diagnostic similarities for BREAST. TISSUE | | | | | | | |
| | 36.84% | 2.63% | 0.00% | 60.53% | 2.64% | 0.00% | 0.00% | 74.36% |
| | Diagnostic similarities for the. DIAPHRAGMS | | | | | | | |
| | 65.79% | 34.21% | 0.00% | 0.00% | 61.54% | 38.46% | 0.00% | 0.00% |
| | Diagnostic similarities for EXTRA-LUMINAL AIR | | | | | | | |
| | 5.26% | 0.00% | 0.00% | 94.74% | 5.13% | 0.00% | 0.00% | 94.87% |
| | Diagnostic similarities for FRACTURES OF THE RIBS AND CLAVICLES | | | | | | | |
| | 2.63% | 0.00% | 0.00% | 97.37% | 5.13% | 0.00% | 0.00% | 94.87% |
| | Diagnostic similarities for. THORAC SOFT TISSUE | | | | | | | |
| | 100.00% | 0.00% | 0.00% | 0.00% | 100.00% | 0.00% | 0.00% | 0.00% |
| | Diagnostic similarities for THORACIC SPINE FRACTURE | | | | | | | |
| | 0.00% | 0.00% | 0.00% | 100.00% | 0.00% | 0.00% | 0.00% | 100.00% |
| | Diagnostic similarities for the THORACIC SPINE LESIONS | | | | | | | |
| | 0.00% | 0.00% | 0.00% | 100.00% | 0.00% | 0.00% | 0.00% | 100.00% |
| | Diagnostic similarities for VERTEBRAL BODY OR SPINOUS FRACTURE | | | | | | | |
| | 0.00% | 0.00% | 0.00% | 100.00% | 0.00% | 0.00% | 0.00% | 100.00% |

Breast tissue: While 14 (36.84%) conventional x-ray system images displayed the breast tissue with good visibility, only 10 (25.64%) Lodox x-ray system images displayed the breast tissue with good visibility. Twenty-three (60.53%) conventional x-ray system images did not show breast tissue. One (2.64%) Lodox x-ray system image showed breast tissue as partially visible but was absent on 29 (74.36%) images.

Diaphragms: The diaphragms were well-visualised on 25 (65.79%) images of conventional x-ray system images and 24 (61.54%) Lodox x-ray system images. The diaphragm was partially visible on 13 (34.21%) conventional x-ray system images and 15 (38.46%) Lodox images.

Extra-luminal air was rated absent on most images for both systems (conventional 36, 94.74% and Lodox 37, 94.87%). It was only rated with good visibility on 2 (5.26%) conventional x-ray system images and 2 (5.13%) Lodox x-ray system images.

Fracture of ribs and clavicle: The conventional x-ray system (37, 97.37%) and Lodox x-ray system (37, 94.87%) images did not show fractures of the ribs and clavicles. One (1) (2.63%) conventional x-ray system image and 2 (5.13%) Lodox x-ray system images displayed fracture of ribs and clavicle.

Soft tissues of thoracic wall: The visibility of soft tissue was rated well for all the images obtained using the conventional x-ray system and the Lodox x-ray system.

Fracture of the thoracic spine was absent on all images obtained by conventional x-ray system and Lodox x-ray system.

Thoracic spine lesion: No thoracic spine lesions were present on any of the images obtained using conventional x-ray system and Lodox x-ray system.

Fracture of the vertebral bodies or spinous processes: All the images obtained from the conventional x-ray system and Lodox x-ray system did not display any fractures of the vertebral body or spinous processes.

The-p-values on the null hypothesis test $p=0.2244$ on the outline of mammary tissue, $p=0.7047$ on the diaphragm, $p=0.9894$ on extra luminal air, $p=0.05843$ for the ribs and clavicle fractures indicate that there was no significant difference. However, p-value was not assigned to the soft tissues of thoracic wall, fracture of thoracic spine, thoracic spine lesion and fracture of vertebral body or spinous process fracture because 100.00% of the images obtained from the conventional x-ray system and lodox x-ray system were similar.

Missing variables

In the establishment of similarities of the images as well as diagnostic similarities, the researcher presented and discussed 26 of the 30 variables on the checklist. This is because some of the variables were assimilated into others; for example, those with the same meaning were discussed under one heading. The researcher combined the variables “pulmonary vessels peripherally demonstrated” with pulmonary vasculature. The demonstration of pulmonary vessels peripherally was discussed under pulmonary vasculature. The discussion of pulmonary vasculature covered the pulmonary vessels peripherally demonstrated. The variable “thoracic spine-vertebral bodies and disc spaces” was discussed under thoracic spine lesions. The discussion of thoracic spine covered the discussion of vertebral and disc spaces. The variable on the retro-cardiac and mediastinum outline was discussed under mediastinal injuries and cardiac outline. There were no other comments given on the checklist.

4.5.8 Discussion of the results for the comparison of diagnostic similarities for chest images (conventional x-ray systems and Lodox chest-dedicated programme).

The two imaging systems seem to have almost similar findings on the visualisation of various anatomical patterns as well as pathological patterns. Both the conventional x-ray system and Lodox x-ray system showed the visualisation of trachea and proximal bronchi, thoracic cage soft tissue outlines and pulmonary vessels at the peripheral edges of the lung with good visibility on all the images. Both imaging systems had over 97.00% beam penetration, thoracic spine vertebral bodies, disc spaces and visualisation of pulmonary and lung parenchyma. Both systems had over 80.00% retro-cardiac and mediastinum outline with good visibility. The Lodox x-ray system was better than the conventional x-ray system at showing fractures of the clavicle, nodules, effusions, retro-cardiac structures, mediastinum structures, pneumothorax, interstitial diseases, and fractures of ribs, fractures of clavicle and lung parenchyma. On the other hand, the conventional x-ray system was better than the Lodox x-ray system at showing the diaphragm and breast tissue outline. Noteworthy is that, although the Lodox x-ray system seems to show most radiological patterns better than the conventional x-ray system, the two imaging systems seem to have almost the same abilities in showing both normal anatomical and pathological patterns on the radiological images.

4.6 Results of measurement of factors impacting on image quality

This objective was meant to compare the images performed using the two imaging systems concerning their system-specific inherent factors that might affect the quality of the images (see 2.5). The level of distortion, spatial resolution, contrast resolution and image noise (dark noise) on chest images for the same patient acquired using both imaging systems were measured prospectively. This was done to compare the quality of the images by measuring the factors impacting imaging quality using the NORMI-13 phantom (see 3.5.3.4). The images were performed on patients at five of the six sampled hospitals. This is because the installation site of the Lodox x-ray system in one of the hospitals could not allow the Lodox x-ray system to be manoeuvred to utilise a horizontal beam. The images obtained prospectively were performed under controlled conditions (e.g., SID used = 180cm for the conventional x-ray systems and 130cm for the Lodox x-ray systems) (see 2.5.2) which ensured more reliable results than images obtained retrospectively. The measurements were conducted with the assistance of a medical physicist and the radiographer in charge of the quality control tests at the sampled hospitals. Each of the variables was measured four times whereafter an average value was calculated and recorded for each (see 2.5.2).

4.6.1 Measurement of variables on the images

The phantom that was used is a NORMI 13 phantom (see Figure 3.2 – Chapter 3).⁷⁵ Additionally, a downloadable MicroDicom viewer was used for measurement and to obtain the pixel values to determine image noise.¹⁰⁹ (See section 3.5.3.5). During the procedure, the phantom and copper plate was strapped onto the Bucky such that the surface was fully in contact with the Bucky. The data was captured on the quality assurance checklist (see Annexure C). The results of the measurements for the level of distortion, spatial resolution, and contrast resolution and image noise are addressed in the following section.

4.6.1.1 Comparison of distortion (size distortion/geometric distortion)

Figure 4.1 presents a comparison of the level of distortion for the two imaging systems. The measurement of distortion was performed by exposing the NORMI 13 phantom to predetermined exposure factors. The lines on the produced images were measured and the outcome was compared with the true length of the lines on the phantom (see section 3.5.3.4).

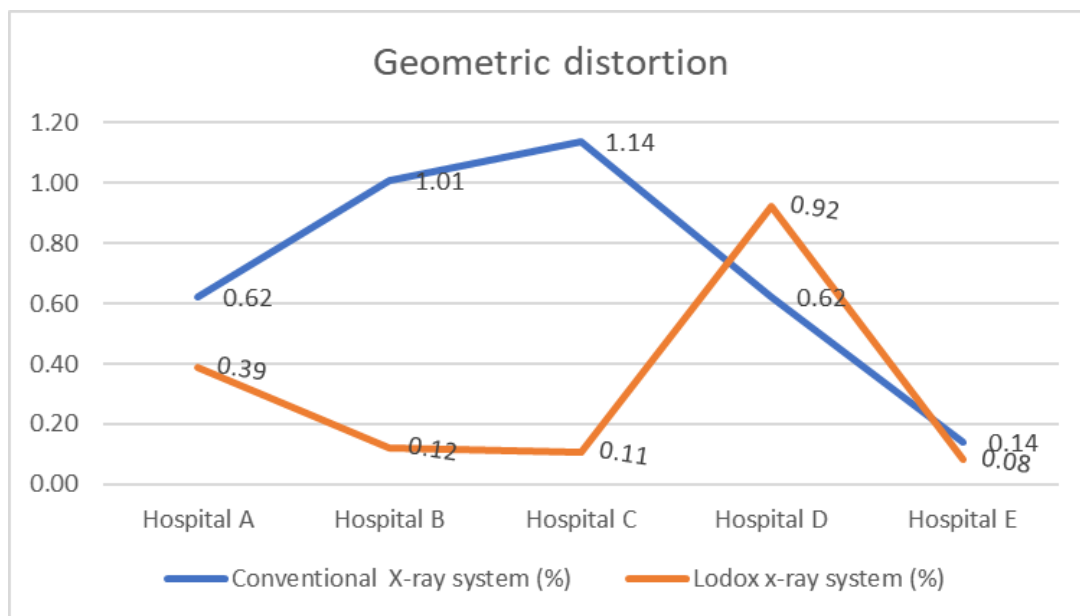


Figure 4.1: Comparison of geometric distortion for the two imaging systems

Evident from the figure is that the conventional x-ray system at hospital C recorded the highest percentage of geometric distortion (scaling error) of 1.14% while the Lodox x-ray system at the same hospital recorded the lowest percentage of geometric distortion (0.11%). At hospital D, the Lodox x-ray system recorded the highest percentage geometric distortion with 0.92% while the distortion for the conventional system at this hospital was recorded at 0.62%. The values for

geometric distortion when comparing the two systems also show a significant difference at hospital B with the conventional x-ray system 1.01% and the Lodox x-ray system at 0.12%.

On average for the five hospitals, the conventional x-ray systems recorded a geometric distortion of 0.70% compared to the Lodox x-ray systems which recorded a geometric distortion of 0.34%. The average value for the geometric distortion was obtained by summation of the geometric distortion values for the five hospitals and then the resultant value was divided by the number of hospitals (values for Hospital A + Hospital B + Hospital C + Hospital D + Hospital E divided by five).

4.6.1.2 Comparison of spatial resolution

Figure 4.2 presents a comparison of the measurement of spatial resolution for the two imaging systems. The number of line pairs per/mm was measured on the resultant image to obtain spatial resolution value for the imaging systems (see section 3.5.3.4).

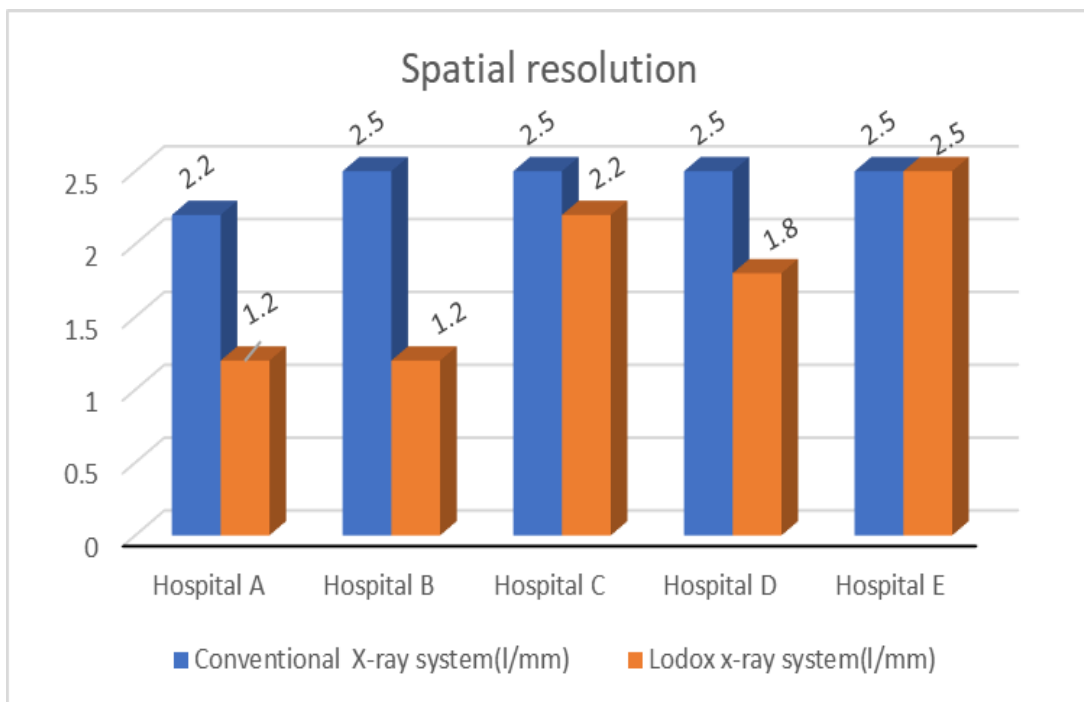


Figure 4.2: Comparison of spatial resolution for the two imaging systems

At hospitals B, C, D and E, the conventional x-ray systems recorded the highest values of spatial resolution at 2.5l/mm. At hospital E, the Lodox x-ray system recorded the same value (2.5l/mm). At the other hospitals, lower values were recorded by the two systems respectively with 2.2l/mm for the conventional systems at hospital A and the Lodox x-ray systems at 1.2 l/mm (hospital B), 2.2l/mm (hospital C) and 1.8l/mm (hospital D). The lowest measured value for spatial resolution was 1.2l/mm for the Lodox x-ray systems at the selected hospitals. The lowest measured spatial resolution for conventional x-ray (2.21l/mm) was for the hospital A.

On average for the five hospitals, the conventional x-ray systems recorded a spatial resolution of 2.37l/mm while the Lodox x-ray systems recorded spatial resolution of 1.97l/mm. It can be concluded that there is no significance difference between the partial resolution of the Lodox x-ray system and that of a conventional x-ray system.

4.6.1.3 Comparison of contrast resolution

Figure 4.3 presents a comparison of the measurement of contrast resolution for the two imaging systems. The NORMI 13 phantom has a seven-step greyscale range that represents a range of densities from white to black on a resultant image. The greyscale on the dynamic steps of the resultant image of NORMI 13 phantom was measured to quantify the contrast resolution for the two imaging systems.

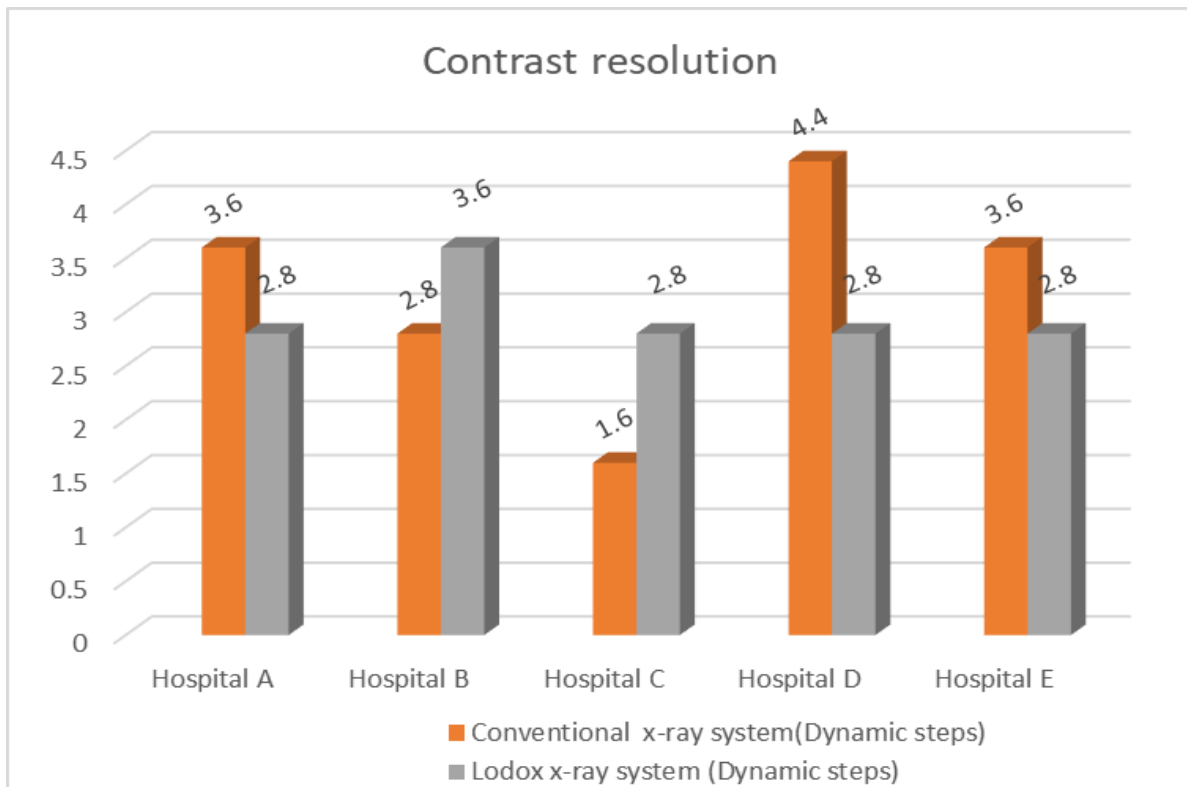


Figure 4.3: Comparison of contrast resolution for the two imaging systems

At hospital C, the conventional x-ray system recorded the highest value for contrast resolution (4.4) while the highest value recorded for the Lodox x-ray systems (3.6) was recorded at hospital B. At the other hospitals (A, C, D & E), the Lodox x-ray systems recorded a contrast resolution value of 2.8 with the lowest value of contrast resolution recorded for the conventional x-ray system at hospital C at 1.6.

On average for the five hospitals, the conventional x-ray systems recorded a contrast resolution of 2.67 and the Lodox x-ray systems showed a contrast resolution of 2.47.

4.6.1.4 Comparison of image noise (dark noise)

The image noise (dark noise) was measured using a copper plate of dimension 150mm by 150mm and a thickness of 0.5mm (see section 3.5.3.5). The exposures were made at SIDs of 180cm (conventional systems) and 130cm (Lodox x-ray systems). A MicroDicom viewer was used to obtain the standard deviations of pixel intensities values on five regions of acquired copper plate images. These regions were distributed across the copper plate image. The average value for each copper plate was obtained. This procedure was repeated for the five hospitals. The average image noise values for the two imaging systems are presented in Figure 4.4.

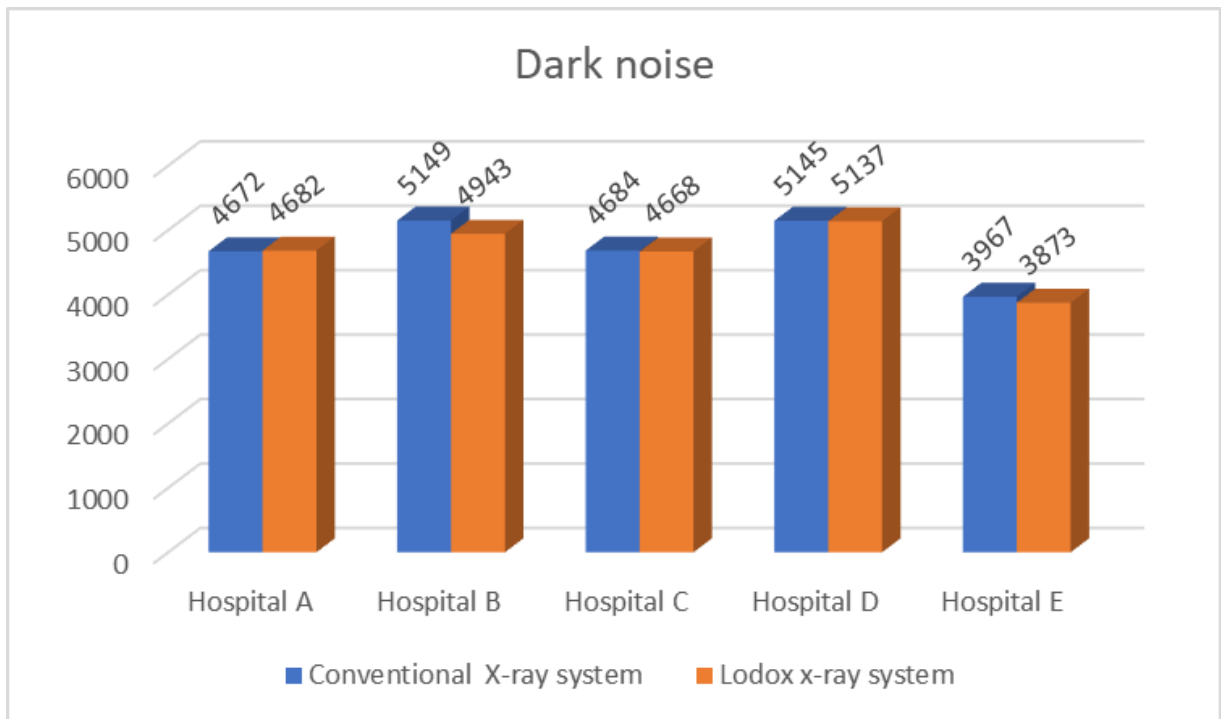


Figure 4.4: Comparison of image noise (dark noise) for the two imaging systems

The conventional system at hospital B recorded the highest dark noise value 5145 while the Lodox x-ray system at hospital D recorded the highest value for dark noise at 5137. The lowest values for dark noise were recorded at hospital E by both the conventional (3967) and the Lodox (3873) systems at hospital E. At hospitals A, C and D, both systems recorded equal dark noise levels with the highest levels at hospital D.

The average image noise value for the conventional x-ray systems and that for the Lodox x-ray system in the five hospitals was 3936.17 and 3883.83, respectively. This indicates an insignificant variation of the resultant image noise values between the two imaging systems.

4.6.1.5 Discussion of the results of the measurement of factors impacting image quality

Considering geometric distortion, the conventional x-ray systems recorded a geometric distortion of 0.70% compared to the Lodox x-ray systems which recorded a geometric distortion of 0.34. This implies that the conventional x-ray systems recorded almost double the geometric distortion when compared to the Lodox x-ray systems. A high level of geometric distortion might cause misinterpretation (measurement of the true sizes of organs that need prosthesis or implants). However, this outcome could be attributed to the divergent nature of the beam of the conventional x-ray systems. As discussed in Chapter 2 (see section 2.5.4), the x-ray beam of the Lodox x-ray system is linear and emanates from a slot that is collimated by a narrow slit that controls the beam along with the object when scanning; hence, the beam is only divergent on the side.

The measurement for spatial resolution obtained from the five hospitals where data was collected indicates that the conventional x-ray systems recorded a spatial resolution of 2.37 l/mm while the Lodox x-ray systems recorded 1.97 l/mm of spatial resolution. This indicates a difference of 0.4l/mm between the two imaging systems which implies that the ability of the two systems to generate images, where small, high-contrast objects can be visualised, is almost the same.

Similarly, the contrast resolution of the two-imaging system seems to have minor differences where the conventional x-ray systems recorded a contrast resolution of 2.67 steps compared to the Lodox x-ray systems which recorded a contrast resolution of 2.47 steps. This indicates a difference of 0.20 steps between the two imaging systems. Contrast resolution is important for image quality as it allows the differentiation of many shades of grey from black to white for the anatomy of a given region.

Image noise is a factor that is undesirable on an image. The less the image noise the higher the diagnostic value. The two imaging systems did not show significant differences in the values of the dark noise that was obtained (see section 4.6.1.4).

4.7 Discussion of the data analysis for diagnostic similarity and diagnostic quality of chest images

The chest images were retrospectively retrieved from the Picture Archiving and Communication Systems (PACS) at the radiology departments. The chest images had been performed using the Lodox x-ray system and conventional x-ray system and were obtained from the same patients within 24 hours of each other. Radiologists reported these images by scoring Annexure B. The results were captured on a spreadsheet and analysed using R-core team software for data analysis.¹²⁶ The resultant data were used to compare the Lodox x-ray system and the conventional x-ray images in terms of the appearance of the pathological and anatomical patterns. All tests were performed at a 5% level of significance. A p-value of less than 0.05 indicated that the null hypothesis can be rejected which then indicates that a significant difference exists between the distribution of data in the two categories of the groups. Each p-value was presented for every variable that was observed and scored as was stated in Annexure B. The analysis applied to phase one of this research is presented in the following section.

4.7.1 Inter-rater agreement

Inter-rater reliability also referred to as interobserver reliability is the degree to which different observers or raters judge or assesses to estimate the same phenomena.¹²⁸ Inter-rater reliability is the extent to which two or more raters (in this case were radiologists who observed, judged, and read the images) agreed on the assigned code. Knowledge of inter-rater reliability is crucial in evaluating the validity and generalisability of the results. Two radiologists from public hospitals and two from private hospitals reviewed the images.¹²⁹ Two radiologists at the private hospitals sat together and discussed the observable features¹²⁸ before assigning a score to the observable features on an image. The inter-reader reliability informed the degree of similarity to which these radiologists scored the observable features on the image. Inter-rater results were obtained by comparing the results of radiologists at the public hospital when compared with the results from the private hospital. High reliability is achieved if similar results are produced under consistent conditions.¹²⁸

Although the two terms are often used interchangeably, there is a technical distinction between the terms agreement and reliability and therefore the terms intra-reader agreement (IRA) and inter-rater reliability (IRR) are used. Fundamentally in the context of research studies, an agreement is defined as the degree to which scores/ratings are identical, whereas reliability relates to the extent of variability and error inherent in a measurement.¹²⁹

A sample of ten images was read by radiologists from the public hospital as well as those from the private hospitals. This ensured inter-rater agreement. The two radiologists from a public and a private hospital respectively repeated the reading of the images after six months. This ensured intra-reader variability. The agreement (inter-rater and intra-rater) reliability are usually expressed in terms of percentage agreement or Cohen's Kappa.¹³⁰ Cohen's Kappa (κ) is a measure of inter-rater agreement for categorical scales when there are two raters. The percentage agreement is calculated as the number of agreement scores divided by the total number of scores.¹³⁰ Cohen's Kappa calculation of agreement was developed to account for the possibility that raters guessed on at least some variables due to uncertainty.¹³⁰ Although Cohen's Kappa is widely used in health there is no clarity of the values that may be used in health-related research.¹³⁰ Although Cohens Kappa values have been stated for reference purposes, the researcher has used the percentage agreement in reporting this research.

4.7.2 Percentage agreement between radiologists at a public hospital and those from a private hospital

Overall, the percentage agreement was 68.30%.

Cohens Kappa

- Null hypothesis (H_0): $\kappa = 0$. The agreement is the same as the chance agreement.
- Alternative hypothesis (H_a): $\kappa \neq 0$. The agreement is different from the chance agreement.

Kappa statistics and strength agreement¹³¹ indicates that when reporting Cohen Kappa results the researcher must indicate that values from ≤ 0 means or indicates no agreement, 0.01–0.20 indicate none to a slight agreement, 0.21–0.40 indicate fair agreement, 0.41– 0.60 indicate moderate agreement, 0.61–0.80 indicates substantial agreement and 0.81–1.00 indicate almost perfect agreement.¹³⁰ In this research, Cohen's Kappa for the raters of the images was = 0.445 and the P-value was = <0.0001 . The null hypothesis was thus rejected (since the p-value was less than 0.05 and a test at a 5.00% level of agreement was used). This shows that the agreement was high enough that it was not just given by chance. The Kappa value was 0.445 which shows a moderate agreement. The united rater agreement suggests a possible value that is as close as possible in support of the validity of this research.

4.7.3 Intra-rater reliability

Intra-rater reliability is the degree of agreement between repeated administrations of observation or judging or diagnostic test performed by a single rater.¹²⁹ It is also an individual consistency of measurement.¹³² Two radiologists read the images (together) at the public hospitals and the private hospitals. The researcher wanted to understand how these results compared when the radiologists scored the images more than once after a duration of time. The researcher thus compared the initial results/scores of the selected images for radiologists at the public hospital with those that were performed after six months on the same images. This was repeated on the radiologists at the private hospitals.

- Percentage agreement among radiologists at the public hospital

Overall, the percentage agreement was 73.80%, Cohens Kappa was = 0.555 and the P-value was <0.0001

- Percentage agreement among radiologists at private Hospital

Overall, the percentage agreement = 98.60%, Cohens Kappa was 0.973 and the P-value was <0.0001

4.7.4 Summary

The reliability agreement for the four radiologists (two from a public hospital and two from a private hospital) who rated the pathological- and anatomical structures on the images was 68.30%. The intra-rater agreement for the radiologists at the private hospitals was 98.60% while that for the two radiologists at the public hospitals was 73.80%. Overall, the agreement between the radiologists at the private hospitals was higher than the percentage agreement for the radiologists in the public hospitals. Although there was a difference in the degree of agreement, the overall agreement was equal to 73.80% and above. This means that the results obtained had no significant variation and are reliable if the scoring of the images were to be done by a different radiologist. Currently, it is known that there is no empirical evidence that images obtained from the Lodox x-ray system differ in diagnostic value although they are often used for diagnostic purposes in some radiology departments in South Africa (Annexure A). This means the findings of this research may be generalised and the outcome has reduced errors in rating/scoring the images. The discrepancy in radiological scoring evidenced as inter-rater variability is inevitable due to human error in the observation and interpretation skills of a human observer.¹³³ It is estimated that 4% of radiologists' daily work contain errors.¹³³ The differences in inter-rater

reliability of radiologists in public hospitals and those in private hospitals has been shown in other research conducted in the United Kingdom.¹³³ This study indicates that the inter-rater viability should not be used as an indicator of the radiologists' ability to report.¹³³

The inter-rater agreement for the radiologists at the private hospitals was 98.60%. Cohen's Kappa for two raters was 0.973 and the P-value was <0.0001 while that for the radiologists at the public hospitals was 73.80% (Cohens Kappa was = 0.555 and P-value was <0.0001). Overall, the agreement between the radiologists in the private hospital was 24.80% higher than the agreement for the radiologists in the public hospital. The differences in the level of agreement could be associated with variation of experience (number of images assessed or years of experience) of the radiologists. The radiologists at the public hospitals were also involved in the teaching of radiology students alongside participating in reporting of images. The time they spent at the clinical sites could be less than that of the private radiologists.

4.8 Summary

The conventional x-ray systems recorded a geometric distortion of 0.70% compared to the Lodox x-ray systems which recorded a geometric distortion of 0.34%. This is almost twice the value obtained on conventional systems. It can be concluded that conventional x-ray systems have a bigger geometric distortion than Lodox x-ray systems. For spatial resolution, conventional x-ray systems recorded a spatial resolution of 2.37l/mm while the Lodox x-ray systems recorded 1.97 l/mm of spatial resolution. This value was obtained using a line/space pattern and therefore this value indicates no significant difference between the spatial resolution of the conventional x-ray systems and Lodox x-ray systems. For contrast resolution, the conventional x-ray systems recorded a contrast resolution of 2.67 and the Lodox x-ray systems showed a contrast resolution of 2.47. It can be concluded that there is no significant difference between the contrast resolutions of the two imaging systems. The dark noise obtained from the conventional x-ray systems and that for the Lodox x-ray systems were 3936.17 and 3883.83 respectively. This indicates an insignificant variation of the resultant image noise values between the two imaging systems.

The outcome of the measurement of the factors influencing image quality indicates that the Lodox x-ray systems have a slight advantage to supply images with good visibility of the anatomy or pathology on the image which is influenced by the level of geometric distortion (see 4.5.1.1).

CHAPTER 5: FORMULATION AND VERIFICATION OF REFERRAL PATHWAY (IMAGING PROTOCOL) GUIDELINES

5.1 Introduction

This phase of the research was conducted to achieve Objectives 1 and 2 of Phase 2 of the study. This chapter presents the demographic details of the participants, results on the formulation of the referral pathway (imaging protocol) guidelines and the results for the verification of the guidelines.

Objective 1 of Phase 2 was aimed at formulating referral pathway (imaging protocol) guidelines for a patient undergoing Lodox imaging and Objective 2 of Phase 2 was aimed at verifying the referral pathway (imaging protocol) guidelines for a patient undergoing Lodox imaging (see section 3.6 and 3.7). Responses from the questionnaire (see Annexure J) were analysed by the researcher. The demographic details of the participants are reported in Table 5.1. Content analysis was used to analyse the comments, inputs, and recommendations from the participants for Section B of the questionnaire (Annexure J). Similar responses were summarised into a single question to be posed in e-Delphi Round 2. The researcher analysed the data and converted the collected data from e-Delphi Round 1 to referral pathway (imaging protocol) guidelines that were verified in the e-Delphi Round 2 (Annexure L).

5.2 Participants' demographics

Table 5.1 shows the demographic information of the participants in e-Delphi round 1 and e-Delphi Round 2. In e-Delphi Round 1, there were eighteen (n=18) participants who responded out of ninety-six (N=96) who were contacted by the researcher. The same participants were engaged in the second round of e-Delphi where the referral pathway (imaging protocol) guidelines verification (e-Delphi Round 1) and validation (e-Delphi Round 2) were done.

Table 5.1: Participants' demographic details (n=18) for Rounds 1 and 2 of the e-Delphi process

| CONSTRUCT | RANGE | FREQUENCY |
|---|--------------|-----------|
| Age groups (in years) | 20 -30 | 5 |
| | 31 - 40 | 12 |
| | Above 40 | 1 |
| Gender | Male | 8 |
| | Female | 10 |
| Duration of experiences at trauma units | 1 – 10 years | 14 |

| CONSTRUCT | RANGE | FREQUENCY |
|---|---|-----------|
| | 11 – 20 years | 4 |
| Duration of experiences at trauma units with a Lodox x-ray system | 1 – 10 years | 16 |
| | 11 – 20 years | 2 |
| Universities/colleges where trauma qualifications were obtained | University of Pretoria | 12 |
| | University of Cape Town | 1 |
| | Chris Hani Baragwanath Nursing College | 1 |
| | University of the Witwatersrand | 1 |
| | Sefako Makgatho Health Science University | 1 |
| | Stellenbosch University | 1 |
| | University of KwaZulu-Natal | 1 |
| | University of Free State | 1 |

As seen from Table 5.1, the majority of participants were between 31–40 years of age (12, 66.67%) followed by five (27.78%) participants in the age group from 20–30 years and one (5.56%) above 40 years of age. Ten (55.56%) participants were female and eight (44.44%) were male. The majority (14, 77.78%) of the participants had between 1–10 years of experience in working at a trauma unit with the rest (4, 22.22%) having between 11–20 years of experience in working at a trauma unit.

Sixteen (88.89%) of the participants had between 1–10 years' experience working at trauma units with a Lodox x-ray system while only two (11.11%) participants had between 11–20 years' experience working at trauma units with a Lodox x-ray system. The universities where the participants obtained their qualifications were the University of Pretoria (12, 66.67%) and the University of Cape Town, the Chris Hani Baragwanath Nursing College, the University of the Witwatersrand, the Sefako Makgatho Health Science University, the Stellenbosch University, the University of KwaZulu-Natal, and the University of Free State, all with one (5.56%) participant each.

5.3 Results on the formulation of the referral pathway (imaging protocol) guidelines (e-Delphi Round 1)

The results for the objective on the formulation of referral pathway (imaging protocol) guidelines (e-Delphi Round 1) for a patient undergoing Lodox imaging is presented in this section.

Ninety-six (N=96) trauma specialists were contacted to participate in the e-Delphi Round 1 questionnaire. Since the researcher did not know the participants who had worked with the Lodox x-ray system, the researcher set the first question as a custom validation question where the participants who had not worked with the Lodox x-ray system were eliminated from participation in the research. The link was also cell phone compatible which allowed the participants to respond on their cell phone, tablet, or laptop. The researcher sent a letter of invitation and an information and consent document (Annexure I) which outlined the title of the research, the objectives, deadlines and conditions of participation to the participants. A file was attached that summarised the findings from the previous phase of the study (see section 4.5) for their reference. To confirm informed consent, participants had to click a button to accept or decline participation. The questionnaire had twenty-eight (28) short questions apportioned into Section A and Section B (see Annexure J). Section A contained questions on the demographic details and Section B contained questions on the clinical indications for the referral of patients for imaging with the Lodox x-ray system with questions related to the imaging patterns that specialists wanted to see on the various x-ray images. The researcher gave participants one month to respond to these questions. E-mail reminders were sent on Mondays, Wednesdays, and Fridays at 12h00. The researcher chose this duration as it was expected that this was the time when most of the participants were on lunch break and could access their cell phones and laptops to participate in this research. An anonymous link to the questionnaire was also shared on a WhatsApp group chat to facilitate participation.

The following results were obtained in e-Delphi Round 1. Content analysis was used to analyse the data (see 3.6.4).

5.3.1 Training for referral of patients for Lodox imaging

This section presents the results on the participants' responses about who is responsible for requesting imaging with the Lodox x-ray system (Section B, Q 7, 8 & 9) (see Table 5.2) and the necessity of training for healthcare workers who are responsible for requesting imaging with the Lodox x-ray system (Section B, Q 10, 11, 12 & 13) (see Table 5.3).

Table 5.2: Referral of patients for Lodox imaging(n=18)

| Referral of patients for Lodox imaging | | Consensus | |
|--|---|-------------|------------|
| | | Yes | No |
| Question 7. (n=18) | The necessity to have universal referral guidelines for Lodox imaging in hospitals | 17 (94.44%) | |
| Question 8. (n=10) | Who should request full-body Lodox imaging on trauma patients? | | |
| | • All (trauma specialists, medical practitioners, and nurses) | | 6 (60.00%) |
| | • Medical practitioner | | 3 (30.00%) |
| | • Nurses | | 1 (10.00%) |
| Question 9. (n=10) | The reasons for your choice on who should refer | | |
| | • Nurses, trauma specialists and other medical practitioners are involved in the evaluation of the patient | 8 (80.00%) | |
| | • Medical practitioner. It is a very “comprehensive” way of making a quick assessment and it helps in quick lifesaving management | | 1 (10.00%) |
| | • All the professionals could request Lodox x-ray imaging except the nurses | | 1 (10.00%) |

Seventeen (94.44%) of the eighteen respondents indicated that it is necessary to have universal referral (imaging protocol) guidelines at all the hospitals for trauma patients to undergo Lodox imaging. One participant (5.56%) indicated that it was not necessary to have universal referral (imaging protocol) guidelines. Consensus of 90.00% (calculated as 17/18x100) was obtained hence the researcher acknowledges the need for the establishment of universal referral (imaging protocol) guidelines for trauma patients undergoing Lodox imaging at the participating hospitals.

Six of the ten (60.00%) respondents indicated that trauma specialists, medical practitioners and nurses can refer patients for Lodox imaging. Three of the ten (30.00%) indicated that a medical practitioner working at a trauma unit can refer a patient for Lodox imaging while one of the respondents (10.00%) indicated that nurses may refer a patient for Lodox imaging. This confirms a consensus of 90.00% for this question.

Eight (8.00%) of the 10 respondents who answered this question indicated the reason for nurses, trauma specialists and other medical practitioners to refer the patient for Lodox imaging was because these professionals were involved in the evaluation of the patient on arrival at the trauma unit. One (10.00%) respondent indicated referral by a medical practitioner in the trauma

units as ‘very comprehensive’ as this professional could do a quick assessment which assisted in quick lifesaving management. Another respondent believed that all the professionals should be allowed to request Lodox imaging, except the nurses. The researcher adopted a consensus of 80.00% for this question.

Table 5.3: Training on Lodox imaging(n=18)

| Training on the Lodox x-ray system | | Consensus | |
|------------------------------------|--|--------------|------------|
| | | Yes | No |
| Question 10. (n=18) | Did you receive training on the use of the Lodox x-ray system before referring patients for Lodox imaging? | 14 (77.78%) | |
| Question 11. (n=18) | Have you received training on the regional dedicated programmes of the Lodox x-ray system? | 18 (100.00%) | |
| Question 12. (n=18) | If you did not receive training, do you still request Lodox imaging with the regional dedicated programmes? (n=18) | 18 (100.00%) | |
| Question 13. (n=10) | What training would you like to receive for Lodox imaging? (n=10) | | |
| | • Training on when to use the Lodox x-ray system | | 4 (40.00%) |
| | • Any training would be beneficial | | 2 (20.00%) |
| | • Need training on how to operate the machine | | 2 (20.00%) |
| | • Need no training on Lodox imaging | | 2 (20.00%) |

Fourteen (77.78%) of the 18 respondents indicated that they had not received training on the use of the Lodox x-ray system before referring patients while four (22.22%) stated that they had received such training. A 77.00% consensus was adopted that trauma specialists did not receive training on the use of the Lodox x-ray system.

All the participants (18, 100.00%) indicated that they did not receive training on the use of the regional dedicated programmes for the Lodox x-ray system; this indicated a consensus of 100.00%.

Four (40.00%) respondents indicated that they need training on when to use the Lodox x-ray system by having a clear referral (imaging protocol) guideline, two (20.00%) indicated that any training would be beneficial to them, two (20.00%) indicated they needed training on how to operate the machine and the other two (20.00%) indicated that they needed no training on Lodox

imaging. Because 80.00% of the participants indicated that they need training, a consensus of 80.00% was achieved on this question.

Although consensus was reached for these questions, they were sent to the participants again in e-Delphi Round 2.

5.3.2 Triage and clinical indication for patients undergoing Lodox imaging (n=18)

Table 5.4 presents the results on the activities that are performed at a prehospital setting before requesting Lodox imaging (Section B, Q 14) and the range/values of vital signs as indicators for the referral of a patient for Lodox imaging (Section B, Q15) (Table 5.5).

Table 5.4: Activities that are performed at a prehospital setting before Lodox imaging

| | Activities that are performed at a prehospital setting before Lodox imaging | Consensus | |
|-----------------------------|--|--------------|----|
| | | Yes | No |
| Question 14 n=10 | • Conduct initial patient triage | 10 (100.00%) | |
| | • Maintenance of airway patency and ventilation | 10 (100.00%) | |
| | • Provide resuscitation and stabilisation of severely injured patients | 9 (90.00%) | |
| | • Transfer seriously injured patients to higher levels of care | 8 (80.00%) | |
| | • Haemorrhagic control and sustenance of circulation | 10 (100.00%) | |
| | • Intravenous fluid therapy | 9 (90.00%) | |
| | • Administering intravenous fluids | 9 (90.00%) | |
| | • Immobilisation on a spine board and application of a cervical spine protection | 10 (100.00%) | |
| | • Connection of the patient to a monitor for vital sign surveillance | 10 (100.00%) | |
| | • Gathering information; mechanism of injury, patient history and time of injury | 10 (100.00%) | |

Ten (100%) of the participants rated the following activities to be performed before requesting Lodox imaging as essential (must be performed): conduct initial patient triage; haemorrhagic control and sustenance of circulation; immobilisation on a spine board and application of cervical spine protection; connection of the patient to a monitor for vital sign surveillance and the gathering information; mechanism of injury; patient history; and time of injury. Ninety per cent

(90%) of the participants rated the following activities as essential to be performed before requesting Lodox imaging: provide resuscitation and stabilisation of severely injured patients; intravenous fluid therapy; and administering intravenous fluids. Only 8 (80.00%) of participants indicated the transfer of seriously injured patients to higher levels of care as essential before Lodox imaging.

This question attained consensus of above 80.00% for all the activities that were proposed to be performed at a prehospital setting before requesting Lodox imaging.

Table 5.5: Vital signs indicative of referral for Lodox imaging (n=18)

| | Range/values of vital signs indicative of referral for Lodox imaging | Consensus | |
|----------------------|--|------------|---------------------------|
| | | Yes | No |
| Question 15. n=10 | <ul style="list-style-type: none"> Blood pressure | | 5 (50.00%). 6 (60.00%) |
| Question 16. n=10 | <ul style="list-style-type: none"> Respiration rate (RR) | 8 (80.00%) | |
| Question 17. n=10 | <ul style="list-style-type: none"> Glasgow-coma-scale (GCS) | | 6 (60.00%) |
| Question 18. n=10 | <ul style="list-style-type: none"> Heart (Pulse) rate | | 5 (50.00%) |

Six (60%) of participants indicated that the Heart (Pulse) rate must be between 60 and 140 before a patient can be referred for Lodox imaging. For respiration rate (RR), 80.00% of the participants indicated a rate of between 10 and 28 breaths per minute as good enough for referral for imaging. For the blood pressure (systole), varying results were received with five (50.00%) participants indicating that the blood pressure (systole) should be 90 and above. One participant (1, 10.00%) indicated that the blood pressure must be above 60 and below 120. One participant (1, 10.00%) indicated that the blood pressure must be 110; one indicated that the blood pressure needs to be normotensive; the other indicated that the blood pressure is above 100 and below 160; one did not indicate a value for the blood pressure. Fifty per cent (5, 50.00%) of the participants indicate the Glasgow Coma Scale(GCS) need to be less than eight.

E-Delphi Round 1, Section B. Question 15

Briefly indicate range or values for vital signs of an adult patient that need a referral for full-body Lodox imaging. i) Blood Pressure (systole)

Five (10, 50.00%) of the participants indicated that the blood pressure of the adult patient must be above ninety. Two participants (1, 10.00%) indicated that the blood pressure must be above 60 and below 120; one participant (1, 10.00%) indicated that the blood pressure must be 110; one indicated that the blood pressure needs to be normotensive; the other indicated that the blood pressure is above 100 and below 160; one did not indicate a value for the blood pressure.

E-Delphi round one, Section B. Question 16

Briefly indicate range or values for vital signs of an adult patient that need a referral for a full-body Lodox scan. ii) Respiration rate (RR)

Eight (80.00%) of the participants indicated that the respiration rate of the adult patient must be between 10 and 28. One participant (1, 10.00%) indicated that the respiration rate must be between 20 and 35. One of the participants did not give a numerical value to this question. The researcher adopted 80.00% as a consensus for this question that the respiration rate of the adult patient must be between 10 and 28 per minute.

E-Delphi round one, Section B. Question 17

Briefly indicate the range of values for vital signs of an adult patient that need a referral for a full-body Lodox scan. iii) Glasgow Coma Scale(GCS)

Six (60.00%) of the ten participants indicated that a value of more than 8 should be used while 20% indicated that GCS must be less than 12 indicating a need for a referring patient for a Lodox scan. Two (20.00%) indicated stated that any value may be used, and the two others did not indicate any numerical value to this question. The researcher adopted a consensus for this research as 60.00% that GCS must be more than eight as an indication of a patient need for a referral of a full-body Lodox scan.

E-Delphi round one, Section B. Question 18

Briefly indicate range or values for vital signs of an adult patient that need a referral for a full-body Lodox scan. iv) Heart (pulse) rate

Six (6, 60.00%) of the 10 participants indicated that heart (pulse) rate must be between 60 and 140 for a patient that needs a referral for a full-body Lodox scan. One (1, 10.00%) indicated that

the heart (pulse) rate may be between above 50 and below 130. One (1, 10.00%) indicated that the heart (pulse) rate may be between 110 and 135; one participant (1, 10.00%) indicated that the heart (pulse) rate must be between 60 and 200. One participant (1, 10.00%) did not assign a numerical value to this question.

E-Delphi round one, Section B. Question 19 (n=11).

Table 5.6 indicates the clinical indications that guide a decision to refer a patient for full-body Lodox imaging.

Table 5.6: Clinical indications for Lodox imaging

| Clinical indication for Lodox imaging | Consensus | |
|---|-----------|------------|
| | Yes | No |
| Ballistic injuries: Injuries caused on a body by the impact of a projectile object. The patient may be referred for Lodox imaging after sustaining injuries from accelerating objects or falling from a height, gunshot injuries, pellets, shrapnel, arrowheads, and body accelerated against an object. | | 3 (27.00%) |
| Pregnant patients. Lodox imaging may be used on pregnant female patients. | | 1 (9.09%) |
| Mechanism of injury. Mechanism of injury would assist in determining the use of the Lodox x-ray system. For example, in blunt trauma injuries. | | 1 (9.09%) |
| Congenital survey pathological survey: Lodox x-ray system may be used for screening patients for pathologies, for example, the congenital abnormalities of the spine e.g., spinal deformity e.g., Kyphoscoliosis and lordosis, and scoliosis and limb length. | | 1 (9.09%) |
| A skeletal radiological survey; for detection of focal or widespread abnormalities of the skeleton e.g., multiple myeloma, metastasis, congenital skeletal abnormalities in children, babygram on stillbirth. The Lodox uses a low radiation dose and therefore it is appropriate for the use in taking these images. Lodox x-ray system can be used to identify multiple myeloma, metastasis, congenital skeletal abnormalities in children, and babygram on stillbirth. | | 1 (9.09%) |
| Forensic investigation: Ingested substances for body packers and child abuse. Lodox x-ray system may be used for investigation of child abuse or ingested illicit drugs. | | 2 (18.18%) |
| None. Lodox x-ray system for any radiological investigation. | | 2 (18.18%) |

Clinical indications for Lodox imaging thus include:

- ✓ Ballistic injuries: Injuries caused on a body by the impact of a projectile object. Three (3, 27.00%) of the 11 participants who engaged in this question indicated that the patient may be referred for Lodox imaging after sustaining injuries from accelerating objects or falling from a height, gunshot injuries, pellets, shrapnel, arrowheads from impact from an accelerating body against an object.
- ✓ Pregnant patients. One (1, 9.09%) of the eleven participants indicated that Lodox imaging may be used on pregnant female patients.
- ✓ Mechanism of injury. One (1, 9.09%) participant indicated that the mechanism of injury would assist in determining the use of the Lodox x-ray system. For example, in blunt trauma injuries.
- ✓ Congenital survey/pathological survey: One (1, 9.09%) participant indicated that the Lodox x-ray system may be used in screening patients for pathologies; for example, the congenital abnormalities of the spine e.g., spinal deformity e.g., Kyphoscoliosis and lordosis, and scoliosis and limb length.
- ✓ A skeletal radiological survey: for detection of focal or widespread abnormalities of the skeleton e.g., multiple myeloma, metastasis, congenital skeletal abnormalities in children, babygram on stillbirth. The Lodox uses a low radiation dose and therefore it is appropriate for the use in taking these images. One participant (1, 9.09%) indicated that the Lodox x-ray system can be used to identify multiple myeloma, metastasis, congenital skeletal abnormalities in children, and babygram on stillbirth.
- ✓ Forensic investigation: Ingested substances for body packers and child abuse. Two (18.18%) participants indicated that the Lodox x-ray system may be used for the investigation of child abuse or ingested illicit drugs.
- ✓ None. Two (18.18%) of the 11 participants indicated that they cannot use the Lodox x-ray system for any radiological investigation.

Since all the suggestions given by the participants ranged between 27.00% and 9.00%, a consensus was not reached. Therefore, the researcher adopted all the suggested clinical indications in this section for resending in the second round of the e-Delphi questionnaire.

E-Delphi Round 1, Section B. Question 20 (n=10)

Table 5.7 represents the responses of the participants on the ranking of regional images (chest, abdomen, skulls, extremity, and spine) in order of priority in the management of a patient at the emergency/trauma unit.

Table 5.7: Regional images in order of priority in trauma patient management

| Regional images in order of priority in trauma patient management | Consensus | |
|--|------------|------------|
| | Yes | No |
| 1. The CXR was indicated to have a priority in the management of the patient. | | 7 (70.00%) |
| 2. The abdomen and pelvis x-ray were the third in the priority of imaging after chest and spine x-ray images. | | 6 (60.00%) |
| 3. Skull x-ray 8/10 (80.00%). The skull x-ray was selected as number five and was in the order of taking skull images during the trauma. | 8 (80.00%) | |
| 4. The extremities (lower limb and upper limb) x-rays were the fourth in order of priority of imaging. | | 7 (70.00%) |
| 5. The spine (Cervical, Thoracic, Lumbar and Sacral) x-ray was selected the second in order of priority of management of the patient. | | 5 (50.00%) |

- ✓ The chest x-ray (CXR) was indicated to have a priority in the management of the patient. Seven of the ten respondents (70.00%) agreed with this.
- ✓ The abdomen and pelvis x-ray were the third in the priority of imaging after chest and spine x-ray images. Six of the ten respondents (60.00%) agreed with this.
- ✓ Skull x-ray 8/10 (80.00%). The skull x-ray was selected as number five and was the order of taking skull images during the trauma. Eight of the ten respondents (80.00%) indicated that the skull would be number five after chest, spine, abdomen, and extremities x-rays.
- ✓ The extremities (lower limb and upper limb) x-rays were the fourth in order of priority of imaging. Seven of the ten respondents (70.00%) agreed with this.
- ✓ The spine (cervical, thoracic, lumbar, and sacral) x-ray was selected second in order of priority of management of the patient. Five of ten respondents (50.00%) agreed that this region is second in the priority of management of the patient.

Prioritisation of spine, abdominal pelvic, extremities and skull imaging in the management of a patient at the emergency/trauma unit was selected by ten participants (n=10). Seven out of 10 participants indicated that CXR was a priority and the skull imaging was the last in the order of priority on the management of a polytrauma patient. This created a consensus of 70.00% that chest Imaging was the priority amongst the imaging of the spine, abdominal pelvic, extremities and skull in the management of a patient at emergency/trauma unit. Spine imaging was selected by five of the seven (50.00%) participants to be performed after CXR images; this created a consensus of 50.00%. Abdominal-pelvic imaging was selected by 6/10 (60.00%) as third in the list of priority imaging. This created a consensus of 60.00%. Seven of the 10 participants (70.00%) selected lower- and upper extremity imaging (70.00%) as fourth in the list of priority imaging. This created a consensus of 70.00%.

This question was not sent back to the participants in the second round since the consensus amongst most of the questions was above 50.00%.

Table 5.8 below presents the participants' suggestions on clinical indications to be used for the referral of patients for imaging of the skull with the Lodox x-ray system.

E-Delphi Round one, Section B. Question 21 (n=10).

Table 5.8: Clinical indication for skull Lodox imaging

| Clinical indications for skull Lodox imaging | Consensus | |
|--|-----------|------------|
| | Yes | No |
| No clinical indication that should suggest Lodox imaging | | 4 (40.00%) |
| Suspected head injury | | 3 (30.00%) |
| Facial bone injuries with no associated symptoms of intracranial pathology (e.g., scalp laceration): | | 2 (20.00%) |

Clinical indications for skull Lodox imaging were:

- ✓ None: Four (40.00%) of the 10 participants indicated that they would not refer patients for skull Lodox imaging.
- ✓ Suspected head injury: Three (30.00%) participants indicated that suspected head injury may be referred for skull Lodox imaging.

- ✓ Facial bone injuries with no associated symptoms of intracranial pathology (e.g., scalp laceration): Two (20.00%) participants indicated that suspected facial bone injuries may be referred for skull Lodox imaging.

This question was sent in the second round of e-Delphi because none of the suggestions given by the participants reached a consensus of above 50.00%.

Skull Lodox imaging may be requested if there are facial bone injuries with no associated symptoms of intracranial pathology (e.g., scalp laceration). Otherwise, CT imaging is the appropriate imaging modality. In the second round, six (6) of the seven (7) participants indicated that skull Lodox imaging may be requested for facial injuries. The consensus was 85.71%.

E-Delphi, Section B. Question 22 (n=10)

Table 5.9 presents the respondents' suggestions on what was suggested to be used as a clinical indication for chest Lodox imaging:

Table 5.9: Clinical indications for chest Lodox imaging

| Clinical indications for chest Lodox imaging | Consensus | |
|---|-----------|------------|
| | Yes | No |
| Any post-traumatic wounds on a chest | | 1 (10.00%) |
| Blunt and penetrating injury | | 1 (10.00%) |
| Any abnormal findings on cardiovascular or respiratory examination examinations | | 1 (10.00%) |
| Chest Pain, Dyspnoea, Tachypnoea | | 1 (10.00%) |
| Use of accessory muscles in breathing | | 1 (10.00%) |
| Abnormal breath sounds | | 1 (10.00%) |
| Suspected rib fractures, | | 1 (10.00%) |
| Paradoxical chest movement | | 1 (10.00%) |
| Suspected aspiration | | 1 (10.00%) |
| Blunt chest trauma, hypoxia, penetrating chest trauma | | 1 (10.00%) |
| Clinical features of Lower respiratory tract infection | | 1 (10.00%) |
| Suspected metastasis | | 1 (10.00%) |
| Frail chest, swelling and tenderness | | 1 (10.00%) |

Clinical indications for a chest Lodox imaging were:

- ✓ Any post-traumatic wounds on a chest. One (10.00%) of the 10 participants indicated that a post-traumatic wound may be referred for chest Lodox scan.
- ✓ Blunt and penetrating injury: One (10.00%) of the ten participants indicated that Blunt and penetrating injury may be referred for chest Lodox scan.
- ✓ Any abnormal findings on cardiovascular or respiratory examination examinations. One (10.00%) of the 10 participants indicated that a post-traumatic wound may be referred for chest Lodox scan.
- ✓ Chest pain, Dyspnoea, Tachypnoea. One (10.00%) of the 10 participants indicated that chest pain, dyspnoea, and tachypnoea may be referred for a chest Lodox scan.
- ✓ Use of accessory muscles in breathing. One (10.00%) of the 10 participants stated that the use of accessory muscles on breathing may be an indication referred for chest Lodox x-ray imaging.
- ✓ Abnormal breath sounds: One (10.00%) of the 10 participants indicated that abnormal breath sounds may be referred for chest Lodox imaging.
- ✓ Suspected rib fractures, haemothorax or pneumothorax. One (10.00%) of the 10 participants indicated that suspected rib fractures, haemothorax or pneumothorax may be referred for chest Lodox imaging.
- ✓ Paradoxical chest movement. One (10.00%) of the 10 participants indicated paradoxical chest movement may be referred for chest Lodox imaging.
- ✓ Suspected aspiration, one (10.00%) of the 10 participants indicated that suspected aspiration may be referred for chest Lodox imaging.
- ✓ Blunt chest trauma, hypoxia, and penetrating chest trauma. One (10.00%) of the 10 participants indicated that blunt chest trauma, hypoxia, penetrating chest trauma may be referred for chest Lodox imaging.
- ✓ Clinical features of Lower respiratory tract infection. One (10.00%) of the 10 participants indicated that lower respiratory tract infection may be referred for chest Lodox imaging.
- ✓ Suspected metastasis. One (10.00%) of the 10 participants indicated that suspected metastasis may be referred for chest Lodox imaging.

- ✓ Frail chest, swelling and tenderness. One (10.00%) of the 10 participants indicated that frail chest, swelling and tenderness may be referred for chest Lodox imaging.

This question was sent in the second round of e-Delphi because none of the suggestions given by the participants reached a consensus of above 50.00%.

E-Delphi Round 1, Section B. Question 23 (n=10)

Table 5.10 represents the respondents' suggestions for clinical indication abdominal-pelvic Lodox imaging.

Table 5.10: Clinical indications for abdominal-pelvic Lodox imaging

| Clinical indications for abdominal-pelvic Lodox imaging | Consensus | |
|--|-----------|------------|
| | Yes | No |
| Blunt or penetrating trauma injury at the abdominopelvic region | | 2 (20.00%) |
| Suspected fracture of the pelvis with associated abdominal tenderness | | 3 (30.00%) |
| Unstable pelvis, haematuria, and abdominal tenderness | | 1 (10.00%) |
| Tenderness on the abdominal and pelvis, unexplained blood loss, bruising or swelling of the abdomen and pelvic regions | | 1 (10.00%) |
| Painful abdomen and pelvis, deformity limb length discrepancy, decreased range of movement at hips | | 1 (10.00%) |
| Abdominal distension, vomiting, constipation, or obstipation after a trauma | | 1 (10.00%) |

Clinical indications for abdominal-pelvic Lodox imaging were:

- ✓ Blunt or penetrating trauma injury at the abdominopelvic region. Two (20.00%) of the 10 participants indicated that blunt or penetrating trauma injury may be referred for abdominopelvic Lodox imaging.
- ✓ Suspected fracture of the pelvis with associated abdominal tenderness. Three (30.00%) of the 10 participants indicated that suspected fracture of the pelvis may be referred for abdominopelvic Lodox imaging.
- ✓ Unstable pelvis, haematuria, and abdominal tenderness. One (10.00%) of the 10 participants indicated that unstable pelvis, haematuria, and abdominal tenderness may be referred for abdominopelvic Lodox imaging.
- ✓ Tenderness on the abdominal and pelvis, unexplained blood loss, bruising or swelling of abdomen and pelvis regions. One (10.00%) of the 10 participants indicated that tenderness

on the abdominal and pelvis, unexplained blood loss, bruising or swelling of abdomen and pelvis regions may be referred for abdominopelvic Lodox imaging.

- ✓ Painful abdomen and pelvis, deformity limb length discrepancy, decreased range of movement at hips. One (10.00%) of the 10 participants indicated that painful abdomen and pelvis, deformity limb length discrepancy, decreased range of movement at hips. maybe referred for abdominopelvic Lodox imaging.
- ✓ Abdominal distension, vomiting, constipation, or obstipation after a trauma. One (10.00%) of the 10 participants indicated abdominal distension, vomiting, constipation, or obstipation after trauma may be referred for abdominopelvic Lodox imaging.

This question was sent in the second round of e-Delphi because none of the suggestions given by the participants reached a consensus of above 50.00%.

E-Delphi Round 1, Section B. Question 24 (n=10)

Table 5.11 represents clinical indications for limb/extremities (lower and upper limb images) Lodox imaging.

Table 5.11: Clinical indications for limb/extremities Lodox imaging

| Clinical indications for limb/extremities (lower and upper limb images) Lodox imaging | Consensus | |
|--|------------|------------|
| | Yes | No |
| Tenderness and deep lacerations | | 1 (10.00%) |
| Deep penetrating wounds | | 1 (10.00%) |
| Unstable pelvis, haematuria, and abdominal tenderness | | 1 (10.00%) |
| Abnormal movement of the limb | | 1 (10.00%) |
| Limb length discrepancy | | 1 (10.00%) |
| Decreased movement of the joints | | 1 (10.00%) |
| Crepitation with limited movement | 7 (70.00%) | |
| Deformities of the extremities | | 1 (10.00%) |
| Amputation of the limb | | 1 (10.00%) |

Clinical indications for limb/extremities Lodox imaging were:

- ✓ Tenderness and deep lacerations. One (10.00%) of the 10 participants indicated that tenderness and deep laceration may be referred for Lodox imaging of the extremities.

- ✓ Deep penetrating wounds. One (10.00%) of the 10 participants indicated that deep penetrating wounds may be referred for Lodox imaging of the extremities.
- ✓ Abnormal movement of the limb. One (10.00%) of the 10 participants indicated that tenderness and deep laceration may be referred for Lodox imaging of the extremities.
- ✓ Limb length discrepancy. One (10.00%) of the 10 participants indicated that limb length discrepancy may be referred for Lodox imaging of the extremities.
- ✓ Decreased movement of the joints. One (10.00%) of the 10 participants indicated that. Decreased movement of the joints may be referred for Lodox imaging of the extremities.
- ✓ Crepitation with limited movement. Seven (70.00%) of the 10 participants indicated that crepitation with limited movement may be referred for Lodox imaging of the extremities.
- ✓ Deformities of the extremities. One (10.00%) of the 10 participants indicated that deformities of the extremities may be referred for Lodox imaging of the extremities.
- ✓ Amputation of the limb. One (10.00%) of the 10 participants indicated that amputation of the limb may be referred for Lodox imaging of the extremities.

This question was sent in the second round of e-Delphi because only one of the responses had reached consensus a consensus of above 50.00%.

E-Delphi round one, Section B. Question 25 (n=10)

Table 5.12 presents participants' suggestions on what may be used as a clinical indication for a spine (cervical, thoracic, lumbar, and sacral) Lodox imaging.

Table 5.12: Clinical indications for Lodox imaging the spine

| Clinical indications for Lodox imaging the spine (cervical, thoracic, lumbar, and sacral) | Consensus | |
|---|-----------|------------|
| | Yes | No |
| Prevertebral tenderness or swelling | | 1 (10.00%) |
| Penetrating midline back injuries | | 1 (10.00%) |
| Distracting injuries of the spine | | 1 (10.00%) |
| Midline and paraspinal tenderness and swelling | | 1 (10.00%) |
| Deformity Bogginess Splaying Sensory function fallout | | 3 (30.00%) |
| Loss of motor function | | 1 (10.00%) |
| Spinal tenderness and associated neurological shock | | 1 (10.00%) |
| Spinal swelling with a limited range of movement | | 4 (40.00%) |

Clinical indications for Lodox imaging the spine were:

- ✓ Prevertebral tenderness or swelling: One (10.00%) of the 10 participants indicated that prevertebral tenderness or swelling may be referred for Lodox imaging of the extremities.
- ✓ Penetrating midline back injuries. One (10.00%) of the 10 participants indicated that Penetrating midline back injuries may be referred for Lodox imaging of the extremities.
- ✓ Distracting injuries of the spine. One (10.00%) of the 10 participants indicated that. Distracting injuries of the spine may be referred for Lodox imaging of the extremities.
- ✓ Midline and paraspinal tenderness and swelling. One (10.00%) of the 10 participants indicated that Midline and paraspinal tenderness and swelling may be referred for Lodox imaging of the extremities.
- ✓ Deformity Bogginess Splaying Sensory function fallout. Three (30.00%) of the 10 participants indicated that deformity Bogginess Splaying Sensory function fallout may be referred for Lodox imaging of the extremities.
- ✓ Loss of motor function. One (10.00%) of the 10 participants indicated that loss of motor function may be referred for Lodox imaging of the extremities.
- ✓ Spinal tenderness and associated neurological shock. One (10.00%) of the 10 participants indicated that Spinal tenderness and associated neurological shock may be referred for Lodox imaging of the extremities.
- ✓ Spinal swelling with a limited range of movement. Four (40.00%) of the 10 participants indicated spinal swelling may be referred for Lodox imaging of the extremities.

This question was sent in the second round of e-Delphi because none of the suggestions given by the participants reached a consensus of above 50.00%.

5.3.3 Referral of patient for additional imaging after Lodox imaging

In this section, the researcher inquired if it was necessary to obtain an additional image after obtaining a quality image with the Lodox x-ray system. In other words, why participants would refer a patient for conventional x-ray imaging after Lodox imaging has been performed and when the participants would refer a patient for additional imaging after Lodox imaging has been performed. The responses to these questions are presented in the following section.

E-Delphi Round 1, Section B. Question 26 – 29 (n=10)

Table 5.13 represents participants' responses on the referral of patients for conventional imaging after Lodox imaging and to other imaging modalities, e.g. CT and Ultrasonography.

Table 5.13: Referral of patients for conventional imaging and other imaging modalities

| Questions | Referral of patients to other imaging modalities | Consensus | |
|-----------|---|------------|------------|
| | | Yes | No |
| 26 | If you obtain images of a diagnostic quality/value from Lodox imaging, would you still refer a patient for conventional CXR images | 7 (70.00%) | |
| 27 | If you obtain images of a diagnostic quality/value from Lodox imaging, why would you still refer a patient for conventional CXR images | | 1 (10.00%) |
| 28 | Why there will be a referral for conventional x-rays after obtaining Lodox images of diagnostic value. | | |
| | • Lodox images are refused by trauma specialists | | 1 (10.00%) |
| | • Lodox x-ray system images are not recognised as for legal representation | | 1 (10.00%) |
| | • Yes, I will still refer | | 1 (10.00%) |
| 29 | When would you refer a patient for Ultrasound imaging without requesting full-body Lodox imaging? | | |
| | • Isolated injuries of abdomen, chest, or pelvis | | 2 (20.00%) |
| | • Suspected vascular injuries and no CT imaging is available | 2 (20.00%) | 2 (20.00%) |
| | • After a clinical examination that shows likely hypovolemia, but no obvious external source for the loss of volume | | 1 (10.00%) |
| | • Suspicion of free fluid in the abdomen | | 3 (30.00%) |
| | • Medical indication | | 1 (10.00%) |
| | • Yes | | 1 (10.00%) |

E-Delphi Round 1, Section B. Question 26

If you obtain images of diagnostic quality/value with Lodox imaging, would you still refer the patient for conventional CXR imaging? (Yes/ No)

Seven (70.00%) of the 10 participants indicated that if they obtained images of a diagnostic quality/value they will not refer patients for CXR with a conventional x-ray system after the patient has undergone Lodox imaging. Three participants (30.00%) indicated that they will still refer patients for conventional imaging after obtaining images of a diagnostic quality/value with the Lodox x-ray system.

E-Delphi Round 1, Section B. Question 27

If you obtain images of diagnostic quality/value with Lodox imaging, why would you still refer a patient for conventional CXR imaging?

One (33.33%) participant indicated that Lodox imaging is usually refused by the trauma specialists. Legal evidence: One (33.33%) indicated that the Lodox x-ray system is not recognised for legal representation. One (33.33%) participant indicated yes; they can still refer.

Although the validation question in Table 5.2.3 scored 70.00%, none of the responses that were given in support of the validation question scored above 50.00%. Therefore, the researcher sent this question in the second round of e-Delphi because there was no consensus reached.

The questions on why there will be a referral for conventional imaging after diagnostic Lodox imaging and when would a patient be referred for Ultrasound imaging did not reach consensus.

e-Delphi, Section B. Question 29 (n=10).

Table 5.14 represents responses from the participants on when the referral of a patient for Ultrasound imaging may be done without the patient undergoing full-body Lodox imaging.

Table 5.14: Referral of a patient for Ultrasound imaging without requesting full-body Lodox imaging

This table shows a clinical indications that may be identified to suggest a referral for a patient for a ultrasound imaging without having to undergo a Lodox imaging.

| Referral of a patient for Ultrasound imaging without requesting full-body Lodox Imaging | | Consensus | |
|---|--|-----------|---------------|
| | | Yes | No |
| 24 | Isolated injuries of abdomen, chest, or pelvis | | 2/10 (20.00%) |
| | Suspected vascular injuries and no CT imaging is available | | 2/10 (20.00%) |

| Referral of a patient for Ultrasound imaging without requesting full-body Lodox Imaging | Consensus | |
|---|-----------|---------------|
| | Yes | No |
| After a clinical examination that shows likely hypovolemia, but no obvious external source for the loss of volume | | 1/10 (10.00%) |
| Suspicion of free fluid in the abdomen | | 3/10 (30.00%) |
| Medical indication | | 1/10 (10.00%) |
| Yes | | 1/10 (10.00%) |

Clinical indications for referral of a patient for Ultrasound imaging without requesting full-body Lodox imaging

- ✓ Isolated injuries of abdomen, chest, or pelvis. Two (20.00%) of the 10 participants indicated that suspected free fluid in the abdomen may suggest a referral for ultrasound without a need for Lodox imaging.
- ✓ Suspected vascular injuries and no CT imaging is available. Two (20.00%) of the 10 participants indicated that suspected free fluid in the abdomen may suggest a referral for ultrasound without a need for Lodox imaging.
- ✓ After a clinical examination that shows likely hypovolemia, but no obvious external source for the loss of volume. One (10.00%) of the 10 participants indicated that suspected free fluid in the abdomen may suggest a referral for ultrasound without a need for Lodox imaging.
- ✓ Suspicion of free fluid in the abdomen. Three (30.00%) of the 10 participants indicated that suspected free fluid in the abdomen may suggest a referral for ultrasound without a need for Lodox imaging.
- ✓ Medical indication: One (10.00%) of the 10 participants indicated that the referral for ultrasound may be performed upon medical request from the specialists.
- ✓ Yes: One (10.00%) of the 10 participants indicated that he/she may refer the patient for Ultrasound imaging without requesting full-body imaging. On this response, the respondent seems not to have understood the question.

This question was sent to participants in the second round of e-Delphi because none of the suggestions given by the participants had reached a consensus of 75.00% and above in the first round of the e-Delphi technique. This means that no consensus had been reached. The sending of these responses to the participants in the second round was aimed at the participants identifying

clinical conditions for which a patient may be referred for Ultrasound imaging without having to request full-body Lodox imaging.

E-Delphi Round 1, Section B. Question 30 (n=10)

Table 5.15 represents respondents’ suggestions on when a patient may be referred for CT imaging without undergoing Lodox imaging.

Table 5.15: Referral of a patient for CT imaging without undergoing Lodox imaging

| Refer a patient for CT imaging without undergoing Lodox imaging? | Consensus | |
|---|------------|----|
| | Yes | No |
| • Suspected isolated injury | 4 (40.00%) | No |
| • Suspected multiple injuries of internal structures that require rapid/urgent interventions | 2 (20.00%) | No |
| • When multiple systems are involved e.g., cardiovascular, urinary system Gastral intestinal tract and nervous system | 1 (10.00%) | No |
| • Midline and paraspinal tenderness and swelling | 1 (10.00%) | No |
| • I would never refer | 2 (20.00%) | No |

Clinical indications for referral of a patient for CT imaging without requesting full-body Lodox imaging

- ✓ Suspected isolated injury. Four (40.00%) of the 10 participants indicated that patients with multiple injuries may be referred for CT imaging without having to go through a Lodox x-ray system.
- ✓ Suspected multiple injuries of internal structures that require rapid/urgent interventions. Two (20.00%) of the 10 participants indicated that they could refer a patient for CT imaging without having undergone full-body Lodox imaging if the patient is suspected to have internal injuries that may require urgent intervention.
- ✓ When multiple systems are involved, e.g., Cardiovascular, urinary system Gastral intestinal tract and nervous system. One (10.00%) of the 10 participants indicated that they may refer a patient for CT imaging without requesting full-body Lodox imaging if multiple systems have injuries.
- ✓ I can never refer: Two (20.00%) participants indicated that they would never refer a patient for Lodox imaging.

This question was sent in the second round of e-Delphi because none of the suggestions given by the participants had reached consensus of above 50.00%. The responses that were given by the participants had a rating between 10.00% and 40.00%. Therefore, the researcher opted to send this question in the second round of e-Delphi to seek consensus.

E-Delphi round one, Section B. Question 31 (n=10).

Table 5.16 represents the respondent's suggestions on what radiological features could be expected on CT images for patients who had undergone Lodox imaging.

Table 5.16: Features on CT images of patients who had undergone a Lodox imaging

| Features on CT images of a patient who had undergone a Lodox imaging | Consensus | |
|--|-----------|------------|
| | Yes | No |
| Great vessels (angiography) | | 1 (10.00%) |
| Detailed spine analysis if suspicious of spinal injury | | 1 (10.00%) |
| Fractures of bones of the thoracic cage | | 1 (10.00%) |
| Pulmonary contusions | | 1 (10.00%) |
| Aortic dissection | | 1 (10.00%) |
| Oesophageal rupture | | 1 (10.00%) |
| Pericardial injuries | | 1 (10.00%) |
| Herniation | | 1 (10.00%) |
| The extent of the injuries | | 1 (10.00%) |
| Hemopneumothorax | | 1 (10.00%) |
| Condition of the tracheobronchial tree | | 1 (10.00%) |
| Vascular injuries like. Aortic rupture | | 1 (10.00%) |
| Better soft tissue injury evaluation | | 1 (10.00%) |
| Mediastinal structures | | 2 (20.00%) |
| Pericardial effusion | | 2 (20.00%) |
| Mediastinal injury delineation | | 1 (10.00%) |
| Bronchopleural fistula | | 1 (10.00%) |
| Atelectasis /lung collapse | | 2 (20.00%) |
| Fractures of ribcage | | 1 (10.00%) |
| Diaphragm injuries | | 1 (10.00%) |
| Tracheobronchial injury | | 1 (10.00%) |
| Diaphragm injuries | | 2 (20.00%) |

| Features on CT images of a patient who had undergone a Lodox imaging | Consensus | |
|---|-----------|------------|
| | Yes | No |
| Trachea and bronchial tree | | 1 (10.00%) |
| Lung parenchymal injuries | | 2 (20.00%) |

The respondents indicated that after Lodox chest imaging has been performed, CT imaging of the chest may be performed to show the following clinical conditions.

- ✓ Great vessels (angiography). One of the 10 (10.00%) participants indicated that they would like to see great vessels (angiography).
- ✓ Detailed spine analysis if suspicious of spinal injury. One of the 10 (10.00%) participants indicated that they would like to see. Detailed spinal analysis if suspicious of spinal injury.
- ✓ Fractures of bones of the thoracic cage. One of the 10 (10.00%) participants indicated that they would like to see fractures of bones of the thoracic cage.
- ✓ Pulmonary contusions. One of the 10 (10.00%) participants indicated that they would like to see pulmonary contusions.
- ✓ Aortic dissection. One of the 10 (10.00%) participants indicated that they would like to see aortic dissection.
- ✓ Oesophageal rupture. One of the 10 (10.00%) participants indicated that they would like to see an oesophageal rupture.
- ✓ Pericardial injuries. One of the 10 (10.00%) participants indicated that they would like to see pericardial injuries.
- ✓ Herniation. One of the 10 (10.00%) participants indicated that they would like to see herniation.
- ✓ The extent of the injuries. One of the 10 (10.00%) participants indicated that they would like to see the extent of the injuries.
- ✓ Hemopneumothorax that might be missed on x-rays. One of the 10 (10.00%) participants indicated that they would like to see hemopneumothorax.
- ✓ Condition of the tracheobronchial tree. One of the 10 (10.00%) participants indicated that they would like to see the tracheobronchial tree.

- ✓ Vascular injuries like an aortic rupture. One of the 10 (10.00%) participants indicated that they would like to see an aortic rupture.
- ✓ Better soft tissue injury evaluation. One of the 10 (10.00%) participants indicated that they would like to see soft tissue injury.
- ✓ Mediastinal structures. One of the 10 (20.00%) participants indicated that they would like to see mediastinal structures.
- ✓ Pericardial effusion. Two of the 10 (20.00%) participants indicated that they would like to see pericardial effusion.
- ✓ Mediastinal injury delineation. One of the 10 (10.00%) participants indicated that they would like to see a mediastinal injury.
- ✓ Bronchopleural fistula. One of the 10 (10.00%) participants indicated that they would like to see a bronchopleural fistula.
- ✓ Atelectasis /lung collapse. One of the two (20.00%) participants indicated that they would like to see atelectasis /lung collapse.
- ✓ Fractures of the ribcage. One of the 10 (10.00%) participants indicated that they would like to see fractures of the ribcage.
- ✓ Diaphragm injuries. One of the 10 (10.00%) participants indicated that they would like to see diaphragm injuries.
- ✓ Tracheobronchial injury, one of the 10 (10.00%) participants indicated that they would like to see the tracheobronchial injury.
- ✓ Diaphragm injuries. One of the two (20.00%) participants indicated that they would like to see diaphragm injuries.
- ✓ Trachea and bronchial tree. One of the 10 (10.00%) participants indicated that they would like to see the trachea and bronchial tree.
- ✓ Lung parenchymal injuries. One of the two (20.00%) participants indicated that they would like to see lung parenchymal injuries.

This question was sent in the second round of e-Delphi because none of the suggestions given by the participants had reached a consensus of above 50.00%. The responses that were given by the participants ranged between 10.00% and 20.00%. Therefore, the researcher sent this question in the second round of the e-Delphi technique to achieve a consensus on the statements given.

E-Delphi round one, Section B. Question 32 (n=12).

Table 5.17 presents the participants' suggestions on when contrast-enhanced full-body CT imaging may be requested after full-body Lodox imaging has been performed.

Table 5.17: Reasons for requesting contrast-enhanced full-body CT imaging after Lodox full-body imaging

| After obtaining full-body Lodox imaging, a contrast-enhanced full-body CT imaging may be requested on the following occasions: | Consensus | |
|--|-----------|------------|
| | Yes | No |
| <ul style="list-style-type: none"> When injuries of multiple systems are involved e.g., cardiovascular, urinary system gastral intestinal tract (GIT) and nervous system | | 6 (60.00%) |
| <ul style="list-style-type: none"> To identify injuries of internal structure that cannot be seen on Lodox images. Suspected head injury with altered mental status, comminuted fractures, chest, abdominal and pelvic viscera injuries | | 3 (30.00%) |
| <ul style="list-style-type: none"> After identification of multiple projectiles on Lodox images suggestive of vascular injury, or intra-abdominal injury | | 3 (30.00%) |

The respondents indicated that after full-body Lodox imaging has been performed, contrast-enhanced full-body CT imaging may be requested on the following occasions.

- ✓ When injuries of multiple systems are involved e.g., Cardiovascular, urinary system GIT and nervous system. Six (60%) of the 12 participants indicated that contrast-enhanced CT imaging may be indicated when injuries of multiple organs are involved.
- ✓ To identify injuries of internal structures that cannot be seen on Lodox images. Suspected head injury with altered mental status, comminuted fractures, chest, abdominal and pelvic viscera injuries. 3 (30.00%) of the 12 participants indicated that contrast-enhanced CT imaging may be requested to identify internal structures.
- ✓ After identification of multiple projectiles on Lodox images suggestive of vascular injury, or intra-abdominal injury. Three (30.00%) of the 12 participants indicated that contrast-enhanced CT imaging may be requested after suspicion of vascular injuries.

Although the first response above scored a rating of 60.00% meaning that patients with suspected multiple systemic injuries could be referred for a contrast-enhanced CT imaging, the other two responses did not have a rating of above 50%. Therefore, this question was sent to the participants in the second round of the e-Delphi for participants to reconsider their input or rate the suggested inputs to obtain a consensus.

E-Delphi round one, Section B. Question 33 (n=15)

Table 5.18 presents participants’ suggestions on what indications may lead to a patient referral for chest Ultrasound in case CT imaging is not available but Lodox full-body imaging was performed.

Table 5.18: Clinical indications for requesting chest Ultrasound imaging when CT imaging is unavailable

| In case there is no CT imaging that has been performed, but the patient has undergone Lodox chest imaging, what clinical indications can lead you to refer a patient for a chest Ultrasound? | Consensus | |
|--|-----------|------------|
| | Yes | No |
| Pleural effusion | | 3 (30.00%) |
| Pulmonary lesion | | 2 (12.50%) |
| Suspected vascular injuries | | 3 (30.00%) |
| Suspected pericardial effusion | | 3 (30.00%) |
| White-out of a lung to decide if collapse or effusion or consolidation | | 3 (30.00%) |
| Sternal fracture | | 4 (26.67%) |
| Lung sliding as evidence of pneumothorax has been described as a shimmering appearance of the pleura, or like tiny ants marching on a string | | 2 (13.33%) |
| Hepatisation (conversion into a substance resembling the liver/ a state of the lungs when gorged with effusion matter, so that they are no longer pervious to air) | | 2 (13.33%) |
| B-line is a kind of comet-tail artefact indicating subpleural interstitial oedema | | 2 (13.33%) |
| Suspected pneumothorax or effusion not evident on supine x-rays | | 4 (26.67%) |
| Suspected cardiac tamponade | | 3 (30.00%) |
| Hemopneumothorax | | 2 (12.5%) |

The respondents indicated that in case there is no CT imaging available, but the patient has undergone Lodox chest imaging, a referral for chest Ultrasound imaging for the following clinical indications is needed.

- ✓ Pleural effusion. Three (30.00%) of the 15 respondents indicated that they would refer a patient to ultrasound to investigate a pleural effusion.
- ✓ Pulmonary lesion. Two (12.50%) of the 15 respondents indicated that they would refer a patient to ultrasound to investigate a pulmonary lesion.
- ✓ Suspected vascular injuries. Three (30.00%) of the 15 respondents indicated that they would refer a patient for Ultrasound imaging to investigate suspected vascular injuries.
- ✓ Suspected pericardial effusion. Three (30.00%) of the 15 respondents indicated that they would refer a patient to ultrasound to investigate a Suspected pericardial effusion.
- ✓ White-out of a lung to decide if collapse or effusion or consolidation. Three (30.00%) of the 15 respondents indicated that they would refer a patient to ultrasound to investigate a white-out of a lung to decide if collapse or effusion or consolidation.
- ✓ Sternal fracture. Four (26.67%) of the 15 respondents indicated that they would refer a patient to ultrasound to investigate a sternal fracture.
- ✓ Lung sliding as evidence of pneumothorax has been described as a shimmering appearance of the pleura, or like tiny ants marching on a string. Two (13.33%) of the 15 respondents indicated that they would refer a patient to ultrasound to investigate a lung sliding as evidence of pneumothorax.
- ✓ Hepatisation (A conversion into a substance resembling the liver/ a state of the lungs when gorged with effusion matter, so that they are no longer pervious to the air). Two (13.33%) of the 15 respondents indicated that they would refer a patient to ultrasound to investigate hepatisation.
- ✓ B-line is a kind of comet-tail artefact indicating subpleural interstitial oedema. Four (26.67%) of the 15 respondents indicated that they would refer a patient to ultrasound to investigate subpleural interstitial oedema.
- ✓ Suspected pneumothorax or effusion not evident on supine x-rays. Three (30.00%) of the 15 respondents indicated that they would refer a patient to ultrasound to investigate a pleural effusion.
- ✓ Suspected cardiac tamponade. Two (12.50%) of the 15 respondents indicated that they would refer a patient to ultrasound to investigate a suspected cardiac tamponade.

- ✓ Hemopneumothorax. Two (12.50%) of the 15 respondents indicated that they would refer a patient to ultrasound to investigate a hemopneumothorax.

This question was sent in the second round of e-Delphi because none of the suggestions given by the participants reached a consensus of above 50.00%. The responses on the suggested clinical indications for requesting Ultrasound imaging when CT imaging is unavailable ranged from 12.00% to 30.00%. This is what motivated the researcher to resend these suggestions to the participants to seek a rating to obtain a consensus on these suggestions.

5.4 Results for verification of the referral pathway (imaging protocol) guidelines in Delphi Round 2

The objective on the verification of referral pathway (imaging protocol) guidelines for a patient undergoing imaging with the Lodox x-ray system was performed in e-Delphi Round 2.

5.4.1 e-Delphi Round 2

In this phase, the experts that worked on the referral pathway (imaging protocol) guidelines in Round 1 were sent the guidelines summarised by the researcher based on the comments and recommendations made by the same expert panel in the previous round (Round 1). A cover letter presented a summary of the findings of Round 1, the objectives of Round 2, and the deadlines for participating in this Round 2. The expert panel was again given one month to respond to the questions by ranking the responses, arranging the events in order of priority, agreeing, or disagreeing with statements presented and identifying clinical indications. The expert panel had the opportunity to alter the summarised responses or maintain the suggested opinions or even add a comment. A reminder email bearing a link to the questionnaire was sent to all the participants every Monday, Wednesday, and Friday at 12h00. However, only 12 participants (trauma specialists) (66.67%) responded. Six of the participants who were involved in the development of the referral pathway (imaging protocol) guidelines in Round 1 of e-Delphi did not respond despite several reminders sent to them by email. Their reasons for not participating are not known to the researcher.

5.4.2 Results the verification of referral pathway (imaging protocol) guidelines

Round 2 of the e-Delphi technique included a questionnaire that was more specific and sought the rating or ranking of various statements. . This questionnaire sought agreement or disagreement on statements that were presented. This round also sought to obtain a consensus opinion from the experts' inputs in the first e-Delphi round. The results for the questions in Round 2 are presented below.

5.4.2.1 Triage and clinical indication for patients undergoing Lodox imaging

In this section, the researcher has presented the findings in the second round of e-Delphi on the triage of the patient before referral for Lodox imaging and the clinical indication for patients undergoing Lodox imaging.

e-Delphi Round 2, Question 1 (n=7).

Table 5.19 presents the participants' responses on the activities that are performed at the prehospital setting before referring a patient for imaging with a Lodox x-ray system and the clinical indications for Lodox imaging.

In the previous round of this research where you have participated, it was suggested that the below activities be performed during the management of a trauma patient *at a prehospital setting or within a hospital setting before sending patients for Lodox imaging*. These activities have been arranged so that they are performed. **(Arrange the following statements such that the first action to be performed will be number one).**

Table 5.19: Activities that are performed at prehospital setting before Lodox imaging

| Activities that are performed at prehospital setting before referring a patient for Lodox imaging and so that these activities are performed | Consensus | |
|---|--------------|----|
| | Yes | No |
| • Assess the patient's airway | 6/7 (85.71%) | |
| • Assess the patient's breathing | 5/7 (71.43%) | |
| • Assess the patient's circulation (pulse and bleeding) | 5/7 (71.43%) | |
| • Perform rapid physical examination-Rapid physical examination/assessment (Head to toe) | 4/7 (57.14%) | |
| • Immobilisation on a spine board and apply a cervical spine protection/collar neck if necessary. | 2/7 (42.86%) | |
| • Transfer seriously injured patients to higher levels of care for radiological investigation and further intervention | 3/7 (42.86%) | |
| • Connection patient to a monitor for vital sign surveillance | 5/7 (71.43%) | |
| • Detailed clinical history informing mechanism of injury, observable injuries, and deaths on sites or on the way to the hospital to be handed over with the patient at the hospital. | 5/7 (71.43%) | |

The participants rated the activities to be performed in a prehospital setting before Lodox imaging in the order presented below.

- i. Assess the patient's **airway**: Ensure the patient's airway is open by the maintenance of **airway** patency and remove a possible obstruction, do C-spine immobilisation, do simple airway manoeuvre and sanctioning if necessary. Six of the seven (6/7, 85.71%) participants indicated that assessing the airway was the first activity to be performed.
- ii. Assess the patient's **breathing**: Ensure the patient is breathing adequately. Check if there is adequate ventilation. Consider oxygen supply if necessary. Five of the seven (5/7, 71.43%) participants indicated that assessing the patient breathing was second in priority.
- iii. Assess the patient's **circulation** (pulse and bleeding): Does the patient have an adequate pulse? Is there serious bleeding/loss of a large amount of blood? Perform haemorrhagic control and sustain blood circulation. Five of the seven participants (5/7, 71.43%) indicated that circulation was the third activity to be performed after the assessment of airway and circulation on a polytrauma patient.
- iv. Perform rapid physical examination-Rapid physical examination/assessment (Head to toe). Examine the head, neck, chest, abdomen, pelvis, extremities of the entire body. Four of the seven participants (4/7, 57.14%) indicated that rapid physical examination was to be performed after assessing and correcting the circulation.
- v. Immobilisation on a spine board and apply a cervical spine protection/collar neck if necessary. Two of the seven (2/7, 42.86%) participants suggested that immobilising a polytrauma patient was important and may be performed after performing a rapid physical examination.
- vi. Transfer seriously injured patients to higher levels of care for radiological investigation and further intervention. Three of seven (3/7, 42.86%) participants indicated that transferring patients that were seriously injured to a higher level of care for further management was significant.
- vii. Connect the patient to a monitor for vital sign surveillance while on the way to the hospital. Five of seven (5/7, 71.43%) participants indicated that connecting the patient to a vital signs monitor was important and may be performed while the patient is on the way to a healthcare facility.
- viii. Detailed clinical history informing mechanism of injury, observable injuries, and deaths on sites or on the way to the hospital to be handed over with the patient at the hospital. Five of

seven participants (5/7, 71.43%) indicated that detailed history was important and may be performed while the patient is on the way to advanced care or to a high level of care.

For the arranged activities, assessment of the airway was selected as the top priority by six of the seven participants (6/7, 85.71%) and the taking of a detailed clinical history was selected by five of the seven participants as the top priority. The suggested activities were ‘gaining access to assess the patient's airway’ and ‘connecting the patient to a monitor for vital sign surveillance while on the way to the hospital’ which were selected by six of the seven participants with a consensus of 85.71%. ‘Assess the patient’s breathing’, ‘assess the patient's circulation’, ‘take a detailed clinical history on the mechanism of injury and observable injuries’, ‘deaths on sites on the way to the hospital to be handed over with the patient at the hospital’ were selected by five of the seven participants earning a consensus of 71.43%. ‘Perform rapid physical examination-Rapid physical examination/assessment (Head to toe)’ was selected by four of the five participants and earned a consensus of 57.14% while ‘transfer seriously injured patients to higher levels of care for radiological investigation and further intervention’ was selected by two of the seven participants thus reaching a consensus of 42.86%. Overall, this question had more than half of the responses with a consensus of more than 50.00% therefore the ranking for this question was adopted.

e-Delphi Round 2, Question 2 (n=7).

Table 5.20 presents the clinical indications for full-body Lodox imaging or regional dedicated Lodox imaging (**Drag and drop into the box on the right side the appropriate clinical indications for Lodyx imaging**).

Table 5.20: Clinical indications for Lodox imaging

| Clinical indications for Lodox imaging | Consensus | |
|---|---------------|--------------|
| | Yes | No |
| Polytrauma patients with suspected injuries at chest, abdomen pelvis and multiple fractures of the extremities. | 7/7 (100.00%) | |
| Ballistic injuries: Injuries caused on a body by the impact of a projectile object. This can be accelerated object or patient e.g., fell off a height, gunshot injuries, pellets, shrapnel, and arrowheads. | 7/7 (100.00%) | |
| Mechanism of injury; Motor vehicle. Accident (MVA), Motorcycle. Accident (MCA), Pedestrian Vehicle. Accident (PVA), mob assault, with multiple injuries and a death/s on the scene, collapsed building. | 7/7 (100.00%) | |
| Traumatic amputations of a limb, where an extremity or a section of the | | 4/7 (57.14%) |

| Clinical indications for Lodox imaging | Consensus | |
|---|--------------|--------------|
| | Yes | No |
| body has been cut off because of the accident or explosion. | | |
| Forensic investigations; Suspected multiple non-accidental injuries with possible fractures. For example, assault, torture, custodian injuries, suicide attempt and ingested materials (drug smuggling). | 6/7 (85.71%) | |
| Mass fatalities where conventional x-ray systems are in use/ x-rays machines are not available. | | 3/7 (42.86%) |
| Contrast-enhanced radiological examinations, Intravascular administration of contrast media for evaluation of patency and vascular pathology where single imaging will show many regions at once. | | 1/7 (9.09%) |
| Routine follow-up of pulmonary diseases like Pulmonary. Tuberculosis, metastasis, screening of occupational disease and disorders. | | 3/7 (42.86%) |
| Routine follow-up of prosthesis patency. E.g., breast implant, hip replacements, and knee replacement. | | 3/7 (42.86%) |
| Evaluation of stent, e.g., ventriculoperitoneal shunt dysfunction. Lodox would take a single image for multiple regions than a separate image taken using conventional x-ray systems. | | 2/7 (28.57%) |
| Radiological skeletal survey; for detection of focal or widespread abnormalities of the skeleton e.g., multiple myeloma, metastasis, congenital skeletal abnormalities in children, babygram on stillbirth. The Lodox uses a low radiation dose and therefore it is appropriate for the use in taking these images. | 5/7 (71.43%) | |
| Congenital abnormalities of the spine e.g., spinal deformity e.g., Kyphoscoliosis and lordosis, and scoliosis and limb length. | 5/7 (71.43%) | |
| Radiological examinations of pregnant patients. Due to low radiations, pregnant patients can undergo Lodox imaging for the safety of the foetus or embryo. The irradiation during pregnancy is limited to 1mSv only. | 6/7 (85.71%) | |

The following represents the ranking of the participants for clinical indications for Lodox imaging

- ✓ Polytrauma patients with suspected injuries at chest, abdomen pelvis and multiple fractures of the extremities. This was selected by all the participants (7/7, 100%).
- ✓ Ballistic injuries: Injuries caused on a body by the impact of a projectile object. This can be accelerated object or patient e.g., fell off a height, gunshot injuries, pellets, shrapnel, and arrowheads. This clinical indication was also selected by all the participants (7/7, 100%).

- ✓ Mechanism of injury; MVA, Motorcycle. Accident (MCA), PVA, mob assault, with multiple injuries and a death/s on the scene, collapsed building. All participants agreed that PVA, mob assault MCA multiple injuries (7/7, 100%) and pedestrian-vehicle accidents were an indication for full-body Lodox imaging.
- ✓ Traumatic amputations of a limb, where an extremity or a section of the body has been cut off because of the accident or explosion. Four of the seven participants (4/7, 57.14%) indicated that traumatic amputation was an indication of full-body Lodox imaging. This generated a consensus of 57.14%.
- ✓ Forensic investigations; Suspected multiple non-accidental injuries with possible fractures. For example, assault, torture, custodian injuries, suicide attempt and ingested materials (drug smuggling). The forensic investigation was suggested by six of the seven (6/7, 85.71%) participants to be a clinical indicator for full-body Lodox imaging. This created a consensus of 85.71%.
- ✓ Mass fatalities where conventional x-ray systems are in use/ x-rays machines are not available. Three of the seven participants (3/7, 42.86%) indicated that mass fatality from a common injury was a clinical indicator for full-body imaging.
- ✓ Contrast-enhanced radiological examinations, intravascular administration of contrast media for evaluation of patency and vascular pathology where single imaging will show many regions at once. Two of the seven participants (2/7, 28.57%) indicated that contrast-enhanced radiological studies could be performed under a Lodox x-ray system.
- ✓ Routine follow-up of pulmonary diseases like pulmonary tuberculosis, metastasis, screening of occupational diseases and disorders, Three of the seven (3/7, 42.86%) participants indicated that Lodox imaging may be used for a routine follow up.
- ✓ Routine follow-up of prosthesis patency, e.g., breast implant, hip replacements, and knee replacement. Three of seven participants selected this statement generating a consensus of 42.86%.
- ✓ Evaluation of stent, e.g., ventriculoperitoneal shunt dysfunction. Lodox would take a single image for multiple regions than a separate image taken using conventional x-ray systems. This statement was selected by two of the seven participants, yielding a consensus of 28.57%.
- ✓ Radiological skeletal survey; for detection of focal or widespread abnormalities of the skeleton e.g., multiple myeloma, metastasis, congenital skeletal abnormalities in children,

babygram on stillbirth. The Lodox uses a low radiation dose and therefore it is appropriate for the use in taking these images. Five of seven participants agreed with this statement, yielding a consensus of 71.43%.

- ✓ Congenital abnormalities of the spine e.g., spinal deformity e.g., Kyphoscoliosis and lordosis, and scoliosis and limb length. Five of seven participants agreed with this statement, yielding a consensus of 71.43%.
- ✓ Radiological examinations of pregnant patients. Due to low radiations, pregnant patients can undergo Lodox imaging for the safety of the foetus or embryo. The irradiation during pregnancy is limited to 1mSv only. Six of seven participants agreed with this statement yielding a consensus of 85.71%.

The rating of the suggested clinical indications for Lodox imaging ranged from 9.09% to 100.00%. Among the 13 proposed clinical indications sent in the second e-Delphi, seven reached consensus of over 70.00%, one reached consensus of 57.14%, three reached consensus of 42.86%, and two reached consensus of 28.57% and 9.09% respectively. The researcher adopted all the suggested clinical indications although three did not have an agreement of above 75%. The motivation for this was that the referral pathway (imaging protocol) guidelines that were developed using this process were subjected to review and validation by the experts and therefore any proposed guidelines that were supported without a 75.00% consensus but had no clinical value on the use of Lodox imaging, were omitted.

5.4.2.2 Referral, triage, and clinical indication for patients undergoing Lodox imaging

In this section, the researcher presents participants' responses on the referral of patients for Lodox imaging, triage of the patients before referral of a patient for Lodox imaging, clinical indication for abdominopelvic Lodox imaging, limb/extremities (lower and upper limb images), spine (cervical, thoracic, lumbar, and sacral) Lodox imaging, and chest Lodox imaging. These phrases have been used below with the responses from the participants.

E-Delphi, round two, Question 3, 4 and 5 (n=8)

Table 5.21 presents the findings on the referral of a patient for Lodox imaging. The researcher inquired about the appropriate healthcare personnel to refer a patient for Lodox imaging at the trauma unit.

Table 5.21: Referral of a patient for Lodox imaging

| Referral of a patient for Lodox imaging | | Consensus | |
|---|--|---------------|------------|
| | | Yes | No |
| Question 3 | A medical practitioner (either a doctor or a nurse) that has examined the patient may refer a patient for a full-body Lodox imaging or a regional dedicated Lodox imaging if only the decision is supported by the rapid physical examination and after evaluation of Airway, Breathing, and Circulation (A, B Cs) of a patient. Do you agree or disagree? | 6/8 (75.00%) | Yes |
| Question 4 | Priority one (P1) and priority two (P2) trauma patients may undergo full-body Lodox imaging if only this decision is supported by the rapid physical examination and after evaluation of Airway, Breathing, and Circulation (A, B Cs) of a patient. Do you agree or disagree? | 4/5 (80.00%) | Yes |
| Question 5 | Priority three (P3) trauma patients may undergo a regional dedicated Lodox imaging of the injured regions or parts only if the decision is supported by the focused physical examination. The request can be described as that of a conventional x-ray. Do you agree or disagree? | 6/8 (75.00%). | Yes |

Six of the eight participants (75.00%) agreed that a medical practitioner (either a doctor or a nurse) that had examined a patient may refer a patient for full-body Lodox imaging or regional dedicated Lodox imaging. The referral should be supported by a rapid physical examination and after evaluation of the Airway, Breathing, and Circulation (ABCs) of the patient. Two of the eight participants did not agree with this statement. A consensus of 75.00% was achieved indicating that all medical practitioners that participated in the evaluation of patients at trauma units may refer patients for Lodox imaging.

e-Delphi, round 2, Question 4

Four of five participants (80.00%) agreed that Priority 1 (P1) and Priority 2 (P2) trauma patients may undergo full-body Lodox imaging if the referral is supported by a rapid physical examination and after the evaluation of the Airway, Breathing, and Circulation (ABCs) of a patient. One (20.00%) of the five participants disagreed with this statement. An overall consensus of 80.00% was attained on this question.

E-Delphi, Round two, Question 5

Six of eight participants (75.00%) agreed that Priority 3 (P3) trauma patients may undergo regional dedicated Lodox imaging of the injured regions or parts of the referral is supported by a focused physical examination. The request can be described as for conventional imaging. Two of the eight participants disagreed with this statement. An overall consensus of 75.00% was attained on this question.

E-Delphi, Round 2, Question 6 (n=8).

Table 5.22 presents the findings on the clinical indications for abdominopelvic Lodox imaging. The researcher asked the participants to select the clinical indications for abdominopelvic Lodox imaging on the list that was provided.

Table 5.22: Clinical indications for abdominal-pelvic Lodox imaging

| Clinical indications for abdominal-pelvic Lodox imaging | Consensus | |
|---|---------------|--------------|
| | Yes | No |
| Blunt or penetrating trauma injury at the abdominopelvic region | 7/8 (87.50%) | |
| Suspected fracture of the pelvis with associated abdominal tenderness | 8/8 (100.00%) | |
| Unstable pelvis, haematuria, and abdominal tenderness | 7/8 (87.50%) | |
| Tenderness on the abdominal and pelvis, unexplained blood loss, bruising or swelling of abdomen and pelvis regions. | 7/8 (87.50%) | |
| Painful abdomen and pelvis, deformity limb length discrepancy, decreased range of movement at hips | 8/8 (100%) | |
| Abdominal distension, vomiting, constipation, or obstipation after a trauma | | 5/8 (62.50%) |
| Blunt or penetrating trauma injury at the abdominopelvic region. | 7/8 (87.50%) | |
| Suspected fracture of the pelvis with associated abdominal tenderness | 8/8 (100.00%) | |
| Unstable pelvis, haematuria, and abdominal tenderness | 7/8 (87.50%) | |
| Tenderness on the abdominal and pelvis, unexplained blood loss, bruising or swelling of abdomen and pelvis regions | 7/8 (87.50%) | |
| Painful abdomen and pelvis, deformity Limb length discrepancy, decreased range of movement at hips, | 8/8 (100.00%) | |

The clinical indications for abdominal-pelvic Lodox imaging were rated as presented below by the participants.

- ✓ Blunt or penetrating trauma injury at the abdominopelvic region. Seven of the eight participants selected this clinical indication with a consensus of 87.50%.
- ✓ Suspected fracture of the pelvis with associated abdominal tenderness, all the participants selected this clinical indication with a consensus of 100.00%.
- ✓ Unstable pelvis, haematuria, and abdominal tenderness. Seven of the eight participants selected this clinical indication with a consensus of 87.50%.
- ✓ Tenderness on the abdominal and pelvis, unexplained blood loss, bruising or swelling of abdomen and pelvis regions. Seven of the eight participants selected this clinical indication with a consensus of 87.50%.
- ✓ Painful abdomen and pelvis, deformity limb length discrepancy, decreased range of movement at hips, all the participants selected this clinical indication with a consensus of 100%.
- ✓ Abdominal distension, vomiting, constipation, or obstipation after a trauma. Five of the eight participants selected this clinical indication with a consensus of 62.50%.
- ✓ Blunt or penetrating trauma injury at the abdominopelvic region. Seven of the eight participants selected this clinical indication with a consensus of 87.50%.
- ✓ Suspected fracture of the pelvis with associated abdominal tenderness. All the participants selected this clinical indication with a consensus of 100.00%.
- ✓ Unstable pelvis, haematuria, and abdominal tenderness. Seven of the eight participants selected this clinical indication with a consensus of 87.50%.
- ✓ Tenderness on the abdominal and pelvis, unexplained blood loss, bruising or swelling of abdomen and pelvis regions. Seven of the eight participants selected this clinical indication with a consensus of 87.50%.
- ✓ Painful abdomen and pelvis, deformity limb length discrepancy, decreased range of movement at hips, all the participants selected this clinical indication with a consensus of 100.00%.

All the suggested clinical indications for abdominal-pelvic Lodox imaging reached consensus of 75.00% except the rating for abdominal distension, vomiting, constipation, or obstipation after

trauma which reached consensus of 62.50%. The researcher opted not to subject this clinical indication to a third round of e-Delphi but rather have the guidelines reviewed during the validation phase due to the attrition of the participants.

e-Delphi, Round 2, Question 7 (n=8)

Table 5.23 presents the clinical indications for the imaging of extremities. The researcher asked the participants to rate the clinical indications for lower- and upper extremities that will be used to refer a patient for Lodox imaging.

Table 5.23: Clinical indications for limb/extremities Lodox imaging (n=10)

| Clinical indications for limb/extremities (lower and upper limb images) Lodox imaging | Consensus | |
|---|---------------|--------------|
| | Yes | No |
| Tenderness and deep lacerations | | 5/8 (62.50%) |
| Deep penetrating wounds | 6/8 (75.00%) | |
| Abnormal movement of the limb | | 4/8 (50.00%) |
| Limb length discrepancy | 8/8 (100.00%) | |
| Decreased movement of the joints | | 4/8 (50.00%) |
| Crepitation with limited movement | 6/8 (75.00%) | |
| Deformities of the extremities | 6/8 (75.00%) | |
| Amputation of the limb. | 7/8 (87.50%) | |

The participants' ratings for the imaging of limb/extremity (lower and upper limb images) Lodox imaging are presented below.

- ✓ Tenderness and deep lacerations. Five of the eight participants selected this clinical indication with a consensus of 62.50%.
- ✓ Deep penetrating wounds. Six of the eight participants selected this clinical indication with a consensus of 75.00%.
- ✓ Abnormal movement of the limb. Four out of eight participants selected this clinical indication with a consensus of 50.00%.
- ✓ Limb length discrepancy. All participants selected this clinical indication with a consensus of 100.00%.
- ✓ Decreased movement of the joints four of the eight participants selected this clinical indication with a consensus of 50.00%.

- ✓ Crepitation with limited movement. Six of the eight participants selected this clinical indication with a consensus of 75.00%.
- ✓ Deformities of the extremities. Six of the eight participants selected this clinical indication with a consensus of 75.00%.
- ✓ Amputation of the limb. Seven of the eight participants selected this clinical indication with a consensus of 87.50%.

Although the rating of the clinical indications that did not reach consensus was between 50.00% and 62.50%, the researcher did not subject these to a third round of e-Delphi. The researcher opted to have these reviewed and subjected to critique validating the guidelines.

e-Delphi, Round 2, Question 8

In Table 5.24 below, the researcher presents the clinical indications for the spine (cervical, thoracic, lumbar, and sacral) Lodox imaging. The researcher asked the participants to rate the clinical indications for Lodox spine imaging.

Table 5.24: Clinical indications for Lodox spine imaging(n=10)

| Clinical indications for Lodox spine imaging (cervical, thoracic, lumbar, and sacral) | Consensus | |
|--|------------------|--------------|
| | Yes | No |
| The fallout of Vertebral, and intervertebral disc spaces | 5/6 (83.33%) | |
| Prevertebral tenderness or swelling | 5/6 (83.33%) | |
| Penetrating midline back injuries | | 4/6 (66.67%) |
| Distracting injuries of the spine | 5/6 (83.33%) | |
| Midline and paraspinal tenderness and swelling | | 4/6 (66.67%) |
| Deformity Bogginess Splaying Sensory function fallout | | 4/6 (66.67%) |
| Loss of motor function | | 3/6 (50.00%) |
| Spinal tenderness and associated neurological shock | 5/6 (83.33%) | |
| Spinal swelling with a limited range of movement | | 3/6 (50.00%) |

The rated clinical indications for spine imaging (cervical, thoracic, lumbar, and sacral) Lodox imaging are below.

- ✓ The fallout of vertebral, and intervertebral disc spaces. Five of the six participants selected this clinical indication, the consensus was 83.33%.

- ✓ Prevertebral tenderness or swelling. Five of the six participants selected this clinical indication, the consensus was 83.33%.
- ✓ Penetrating midline back injuries. Four of the six participants selected this clinical indication. The consensus was 66.67%.
- ✓ Distracting injuries of the spine. Five of the six participants selected this clinical indication, the consensus was 83.33%.
- ✓ Midline and paraspinal tenderness and swelling. Four of the six participants selected this clinical indication. The consensus was 66.67%.
- ✓ Deformity bogginess splaying sensory function fallout. Four of the six participants selected this clinical indication. The consensus was 66.67%.
- ✓ Loss of motor function. Three of the six participants selected this clinical indication. The consensus was 50.00%.
- ✓ Spinal tenderness and associated neurological shock. Five of the six participants selected this clinical indication, the consensus was 83.33%.
- ✓ Spinal swelling with a limited range of movement. Three of the six participants selected this clinical indication. The consensus was 50.00%.

The following clinical indications reached consensus above 75.00%: the fallout of vertebral and intervertebral disc spaces; prevertebral tenderness or swelling, distracting injuries of the spine; spinal tenderness and associated neurological shock. Although the other clinical indications did not reach consensus, the rating was between 50.00% and 66.00%. The researcher opted to subject the guidelines that were developed to review and rather amend and critique them at the validation stage rather than sending them for another round of e-Delphi.

E-Delphi, Round 2, Question 09 (n=8)

Table 5.24 below presents the findings on clinical indications for chest Lodox imaging. The participants were asked to rate the clinical indications for chest Lodox imaging. The clinical indications provided were previously suggested in e-Delphi Round 1.

Table 5.24: Clinical indications for a chest Lodox imaging

| Clinical indications for a chest Lodox imaging | Consensus | |
|--|---------------|----|
| | Yes | No |
| Any post-traumatic wounds on a chest | 8/8 (100.00%) | |

| Clinical indications for a chest Lodox imaging | Consensus | |
|---|--------------|--------------|
| | Yes | No |
| Blunt and penetrating injury | 7/8 (87.50%) | |
| Any abnormal findings on cardiovascular or respiratory examination examinations | | 4/8 (50.00%) |
| Chest pain, Dyspnoea, Tachypnoea | | 3/8 (37.50%) |
| Use of accessory muscles in breathing | | 3/8 (37.50%) |
| Paradoxical chest movement | | 4/8 (50.00%) |
| Suspected aspiration | | 3/8 (37.50%) |
| Blunt chest trauma, hypoxia, penetrating chest trauma | 7/8 (87.50%) | |
| Clinical features of lower respiratory tract infection | | 3/8 (37.50%) |
| Suspected metastasis | | 3/8 (37.50%) |
| Frail chest, swelling and tenderness | 7/8 (87.50%) | |

The participants' rating of the clinical indication for referral for chest Lodox imaging is presented below.

- ✓ Any post-traumatic wounds on a chest. All participants (8/8) selected this clinical indication with a consensus of 100.00%.
- ✓ Blunt and penetrating injury. Seven of the eight participants selected this clinical indication with a consensus of 87.50%.
- ✓ Any abnormal findings on cardiovascular or respiratory examination examinations. Four of the participants selected this clinical indication with a consensus of 50.00%.
- ✓ Chest pain, dyspnoea, and tachypnoea. Three of the eight participants selected this clinical indication the consensus was 37.50%.
- ✓ Use of accessory muscles in breathing. Three of the eight participants selected this clinical indication the consensus was 37.50%.
- ✓ Paradoxical chest movement. Four of the eight participants selected this clinical indication. The consensus was 50.00%.
- ✓ Suspected aspiration. Three of the eight participants selected this clinical indication the consensus was 37.50%.
- ✓ Blunt chest trauma, hypoxia, and penetrating chest trauma. Five of the eight participants selected this clinical indication with a consensus of 87.50%.

- ✓ Clinical features of lower respiratory tract infection. Three of the eight participants selected this clinical indication. The consensus was 37.50%.
- ✓ Suspected metastasis. Three of the eight participants selected this clinical indication the consensus was 37.50%.
- ✓ Frail chest, swelling and tenderness. Seven of the eight participants selected this clinical indication with a consensus of 87.50%.

The following clinical indications reached a consensus of 75.00% and above: any post-traumatic wounds on a chest, blunt and penetrating injury, blunt chest trauma, hypoxia, penetrating chest trauma, frail chest, swelling and tenderness. Although other clinical indications reached more than 50.00% consensus, the researcher opted not to return these guidelines in another round of e-Delphi due to attrition of the participants but rather have the guidelines verified during the validation of the guidelines.

5.4.2.3 Referral of the patient for additional imaging after Lodox imaging

The outcomes for when to refer a patient for CT imaging without requesting full-body Lodox imaging include the following: conditions in which a contrast-enhanced CT imaging may be requested after Lodox imaging; clinical indications that would suggest a request for a CT imaging of the chest after Lodox imaging of a chest. The outcomes are presented in the table below.

E-Delphi, Round 2, Question 10 (n=4)

Table 5.25 presents the results on when a patient may be referred for CT imaging without undergoing Lodox imaging.

Table 5.25: Patient referral for CT imaging without undergoing Lodox imaging

| When would you refer a patient for CT imaging without requesting full-body Lodox imaging? | Consensus | |
|---|------------------|-----------|
| | Yes | No |
| Suspected isolated injury | 4/4 (100.00%) | |
| Suspected multiple injuries of internal structures that require rapid/urgent interventions | 3/4 (75.00%) | |
| When multiple systems are involved e.g., cardiovascular, urinary system Gastral intestinal tract and nervous system | 3/4 (75.00%) | |

Participants rated the referral of a patient for CT imaging without undergoing Lodox imaging as presented below.

All the suggested clinical indications on when a patient may be referred for CT imaging without undergoing Lodox imaging reached consensus of 75.00% and above. Suspected isolated injury. Four of the four participants selected this clinical indication. There was 100% consensus on this clinical indication.

- ✓ Suspected multiple injuries of internal structures that require rapid/urgent interventions
Three of the four (75.00%) participants selected this clinical indication. There was 75.00% consensus on this clinical indication.
- ✓ When multiple systems are involved e.g., Cardiovascular, urinary system GIT and nervous system. Three of the four (75.00%) participants selected this clinical indication. The consensus was 75.00%.

e-Delphi, Round 2, Question 11 (n=8)

Table 5.26 presents the rating of clinical indications for contrast-enhanced full-body CT imaging after Lodox imaging.

Table 5.26: Referral of patient for full-body contrast-enhanced CT imaging after Lodox imaging

| After obtaining full-body Lodox imaging, contrast-enhanced full-body CT imaging may be requested on the following occasions | Consensus | |
|---|---------------|----|
| | Yes | No |
| When injuries of multiple systems are involved e.g., cardiovascular, urinary system GIT and nervous system | 7/8 (87.50%) | |
| To identify injuries of internal structures that cannot be seen on Lodox images. Suspected head injury with altered mental status, comminuted fractures, chest, abdominal and pelvic viscera injuries | 8/8 (100.00%) | |
| After identification of multiple projectiles on Lodox images suggestive of vascular injury, or intra-abdominal injury | 7/8 (87.50%) | |

All the suggested clinical indications for referral of a patient for contrast-enhanced CT imaging after full-body Lodox imaging has reached consensus.

- ✓ When multiple systems are involved e.g., Cardiovascular, urinary system GIT and nervous system. Seven of the eight participants selected this clinical indication with a consensus of 87.50%.

- ✓ To identify internal structure injuries that cannot be seen on a Lodox Suspected head injury with altered mental status, comminuted fractures, chest, abdominal and pelvic viscera injuries. All eight participants selected this clinical indication. The consensus was 100.00%.
- ✓ After identification of multiple projectiles on Lodox images suggestive of vascular injury, or intra-abdominal injury. Seven of the eight participants selected this clinical indication with a consensus of 87.50%.

e-Delphi, round two, Question 12 (n=8).

Table 5.27 presents the rating on the clinical indications to guide the referral for CT imaging after Lodox imaging of the chest has been performed.

Table 5.27: Clinical indications for CT imaging of the chest after Lodox imaging of the chest

| Clinical indications for CT imaging of the chest after Lodox imaging of the chest | Consensus | |
|---|---------------|--------------|
| | Yes | No |
| Great vessels (angiography) | 7/8 (87.50%) | |
| Detailed spine analysis if suspicious of spinal injury | 7/8 (87.50%) | |
| Fractures of bones of the thoracic cage | 3/8 (37.50%) | |
| Pulmonary contusions | 4/8 (50.00%) | |
| Aortic dissection | (8/8 100.00%) | |
| Oesophageal rupture | | 4/8 (50.00%) |
| Pericardial injuries. | | 5/8 (62.50%) |
| Herniation | | 4/8 (50.00%) |
| The extent of the injuries | | 4/8 (50.00%) |
| Hemopneumothorax | | 3/8 (37.50%) |
| Condition of the tracheobronchial tree | | 5/8 (62.50%) |
| Vascular injuries like aortic rupture | 6/8 (75.00%) | |
| Better soft tissue injury evaluation | | 2/8 (25.00%) |
| Mediastinal structures | | 4/8 (50.00%) |
| Pericardial effusion | | 4/8 (50.00%) |
| Mediastinal injury delineation | | 4/8 (50.00%) |
| Bronchopleural fistula | | 4/8 (50.00%) |
| Atelectasis /lung collapse | | 1/8 (12.50%) |
| Fractures of ribcage | | 1/8 (12.50%) |
| Diaphragm injuries | | 5/8 (62.50%) |
| Tracheobronchial injury | | 5/8 (62.50%) |
| Lung parenchymal injuries | | 3/8 (37.50%) |

Participants rated the following indications for referral for CT imaging of the chest after Lodox imaging of the chest.

- ✓ Great vessels (angiography). Seven of the eight participants selected this clinical indication with a consensus of 87.50%.
- ✓ Detailed spine analysis if suspicious of spinal injury on CXR. Seven of the eight participants selected this clinical indication with a consensus of 87.50%.
- ✓ Fractures of bones of the thoracic cage. Three of the eight participants selected this clinical indication the consensus was 37.50%.
- ✓ Pulmonary contusions. Four of the eight participants selected this clinical indication. The consensus was 50.00%.
- ✓ Aortic dissection. All participants selected this clinical indication with a consensus of 100.00%.
- ✓ Oesophageal rupture. Four of the eight participants selected this clinical indication. The consensus was 50.00%.
- ✓ Pericardial injuries. Five of the eight participants selected this clinical indication with a consensus of 62.50%.
- ✓ Herniation. Four of the eight participants selected this clinical indication. The consensus was 50.00%.
- ✓ The extent of the injuries was noted. Four of the eight participants selected this clinical indication. The consensus was 50.00%.
- ✓ Hemopneumothorax that might be missed on x-rays. Three of the eight participants indicated Hemopneumothorax as an indicator of referral of chest for CT imaging after Lodox x-ray has been performed (3/8, 37.50%).
- ✓ Condition of the tracheobronchial tree. Five of the eight participants selected this clinical indication with a consensus of 62.50%.
- ✓ Vascular injuries like an aortic rupture. Six of the eight participants selected this clinical indication with a consensus of 75.00%.
- ✓ Better soft tissue injury evaluation. Two of the eight participants selected this clinical indication with consensus of 25.00%.

- ✓ Mediastinal structures. Four of the eight participants selected this clinical indication. The consensus was 50.00%.
- ✓ Pericardial effusion. Four of the eight participants selected this clinical indication. The consensus was 50.00%.
- ✓ Mediastinal injury delineation. Four of the eight participants selected this clinical indication. The consensus was 50.00%.
- ✓ Bronchopleural fistula. Four of the eight participants selected this clinical indication. The consensus was 50.00%.
- ✓ Atelectasis /lung collapse. One of the eight participants selected this clinical indication with a consensus of 12.50%.
- ✓ Fractures of the ribcage. One of the eight participants selected this clinical indication with a consensus of 12.50%.
- ✓ Diaphragm injuries. Five of the eight participants selected this clinical indication with a consensus of 62.50%.
- ✓ Tracheobronchial injury five of the eight participants selected this clinical indication with a consensus of 62.50%.
- ✓ Lung parenchymal injuries. Three of eight participants selected this clinical indication the consensus was 37.50%.

The following clinical indication was suggested for requesting CT imaging of the chest after Lodox imaging of a chest has been performed: When there is a need to visualise the great vessels (angiography); when detailed spine analysis if suspicious of spinal injuries is needed; when fractures of bones of the thoracic cage are needed, when there is suspected pulmonary contusions or aortic dissection or vascular injuries like an aortic rupture. These clinical indications reached 75.00% consensus. Although most of the other clinical indications reached more than 50.00% consensus, the level of agreement acceptable for a consensus was set by the researcher to be 75.00%. Therefore, these indications were submitted for critique, amendments, and rating during the validation of the developed guidelines.

5.5 Adjustment of the guidelines by the researcher

During this step, the researcher critically reviewed the comments, inputs and responses that were given by the participants. These comments were used to develop the referral pathway (imaging protocol) guidelines that were sent for validation.

5.6 Review of data analysis by the researcher

The researcher reviewed the referral pathway (imaging protocol) guidelines and ensured that all the data was analysed. All the referral pathway (imaging protocol) guidelines were written in line with the comments made by the participants in all the rounds. The researcher made changes that were suggested to accommodate the opinions of the participants. Each of the draft guidelines was outlined and supported by the rationale for its inclusion (Section 6.5.6). The specific actions required to facilitate the realisation of the proposed guideline was also outlined.

5.7 Validation of the process used in the development of the referral pathway (imaging protocol) guidelines

During this step, draft referral pathway (imaging protocol) guidelines were presented to trauma specialists working with the Lodox x-ray system who were the participants in this research. In this research, these participants were experts involved in teaching and research and practising at various trauma units. These experts reviewed and rated the referral (imaging protocol) guidelines to ascertain that they met the criteria suggested by the AGREE collaboration. The drafted referral (imaging protocol) guidelines were e-mailed to three trauma specialists who rated the referral (imaging protocol) guidelines and the process used in developing those using the criteria in Table 5.27, Table 5.28 and Table 5.29. A score of 1 indicates 'strongly disagree' and a score of 6 indicates 'strongly agree' with the stipulated criteria on the rating scale below:

| <i>Criteria</i> | <i>Score</i> |
|--------------------------|--------------|
| <i>Strongly disagree</i> | <i>1</i> |
| <i>Disagree</i> | <i>2</i> |
| <i>Disagree somewhat</i> | <i>3</i> |
| <i>Undecided</i> | <i>4</i> |
| <i>Agree somewhat</i> | <i>5</i> |
| <i>Agree</i> | <i>6</i> |
| <i>Strongly agree</i> | <i>7</i> |

The higher the score the higher the quality of the referral pathway (imaging protocol) guidelines. These experts recommended some minor changes in the phrasing of the sentences and suggested minor additions to the referral (imaging protocol) guidelines with their suggested input. Hence, the suggestions were mostly editorial and about the phrasing of the developed guidelines. The evaluation criteria presented in Table 5.2.7, Table 5.2.8 and Table 5.2.8 were developed according

to guidelines proposed by an international team of guideline developers and researchers known as the AGREE Collaboration.⁹¹ which were used for the validation process.

The developed referral pathway (imaging protocol) guidelines were sent to the experts to rate the outcomes of the protocol guidelines. Table 5.28, Table 5.29, and Table 5.30 represent the results of the validation process.

Table 5.28: Rating by appraiser 1

| Domains | Scope and purpose | | | | | | | Expert involvement | | | | | | | Rigour of the development | | | | | | | Clarity of the presentation | | | | | | | Applicability | | | | | | | Editorial independence | | | | | | | | |
|--------------------|-------------------|---|---|---|---|---|---|--------------------|---|---|---|---|---|---|---------------------------|---|---|---|---|---|---|-----------------------------|---|---|---|---|---|---|---------------|---|---|---|---|---|---|------------------------|---|---|---|---|---|---|--|---|
| | 1 | 2 | 3 | 4 | 5 | 6 | 7 | 1 | 2 | 3 | 4 | 5 | 6 | 7 | 1 | 2 | 3 | 4 | 5 | 6 | 7 | 1 | 2 | 3 | 4 | 5 | 6 | 7 | 1 | 2 | 3 | 4 | 5 | 6 | 7 | 1 | 2 | 3 | 4 | 5 | 6 | 7 | | |
| Guideline 1 | | | | | | | x | | | | | | | x | | | | | | | x | | | | | | | x | | | | | | | | x | | | | | | | | x |
| Guideline 2 | | | | | | x | | | | | | | | x | | | | | | | x | | | | | | | x | | | | | | | | x | | | | | | | | x |
| Guideline 3 | | | | | | x | | | | | | | | x | | | | | | | x | | | | | | | x | | | | | | | | x | | | | | | | | x |
| Guideline 4 | | | | | | | x | | | | | | | x | | | | | | | x | | | | | | | x | | | | | | | | x | | | | | | | | x |
| Guideline 5 | | | | | | | x | | | | | | | x | | | | | | | x | | | | | | | x | | | | | | | | x | | | | | | | | x |
| Guideline 6 | | | | | | | x | | | | | | | x | | | | | | | x | | | | | | | x | | | | | | | | x | | | | | | | | x |
| Guideline 7 | | | | | | | x | | | | | | | x | | | | | | | x | | | | | | | x | | | | | | | | x | | | | | | | | x |
| Guideline 8 | | | | | | x | | | | | | | | x | | | | | | | x | | | | | | | x | | | | | | | | x | | | | | | | | x |
| Guideline 9 | | | | | | x | | | | | | | | x | | | | | | | x | | | | | | | x | | | | | | | | x | | | | | | | | x |
| Guideline 10 | | | | | | x | | | | | | | | x | | | | | | | x | | | | | | | x | | | | | | | | x | | | | | | | | x |
| Guideline 11 | | | | | | | x | | | | | | | x | | | | | | | x | | | | | | | x | | | | | | | | x | | | | | | | | x |
| Guideline 12 | | | | | | x | | | | | | | | x | | | | | | | x | | | | | | | x | | | | | | | | x | | | | | | | | x |
| Guideline 13 | | | | | | x | | | | | | | | x | | | | | | | x | | | | | | | x | | | | | | | | x | | | | | | | | x |
| Total score | 84/91 | | | | | | | 78/91 | | | | | | | 82/91 | | | | | | | 70/91 | | | | | | | 84/91 | | | | | | | 84/91 | | | | | | | | |

Table 5.29: Rating by appraiser 2

| Domains | Scope and purpose | | | | | | | Expert involvement | | | | | | | Rigour of the development | | | | | | | Clarity of the presentation | | | | | | | Applicability | | | | | | | Editorial independence | | | | | | | | |
|--------------------|-------------------|---|---|---|---|---|---|--------------------|---|---|---|---|---|---|---------------------------|---|---|---|---|---|---|-----------------------------|---|---|---|---|---|---|---------------|---|---|---|---|---|---|------------------------|---|---|---|---|---|---|--|---|
| Scale | 1 | 2 | 3 | 4 | 5 | 6 | 7 | 1 | 2 | 3 | 4 | 5 | 6 | 7 | 1 | 2 | 3 | 4 | 5 | 6 | 7 | 1 | 2 | 3 | 4 | 5 | 6 | 7 | 1 | 2 | 3 | 4 | 5 | 6 | 7 | 1 | 2 | 3 | 4 | 5 | 6 | 7 | | |
| Guideline 1 | | | | | | x | | | | | | | x | | | | | | | x | | | | | | | | x | | | | | | | x | | | | | | | | | x |
| Guideline 2 | | | | | | | x | | | | | | x | | | | | | | x | | | | | | | | x | | | | | | | | | x | | | | | | | |
| Guideline 3 | | | | | | | x | | | | | | x | | | | | | | x | | | | | | | | x | | | | | | | | | x | | | | | | | |
| Guideline 4 | | | | | | | x | | | | | | x | | | | | | | x | | | | | | | | x | | | | | | | | | x | | | | | | | |
| Guideline 5 | | | | | | x | | | | | | | x | | | | | | | x | | | | | | | | x | | | | | | | | | x | | | | | | | |
| Guideline 6 | | | | | | x | | | | | | | x | | | | | | | x | | | | | | | | x | | | | | | | | | x | | | | | | | |
| Guideline 7 | | | | | | | x | | | | | | x | | | | | | | x | | | | | | | | x | | | | | | | | | x | | | | | | | |
| Guideline 8 | | | | | | | x | | | | | | x | | | | | | | x | | | | | | | | x | | | | | | | | | x | | | | | | | |
| Guideline 9 | | | | | | | x | | | | | | x | | | | | | | x | | | | | | | | x | | | | | | | | | x | | | | | | | |
| Guideline 10 | | | | | | x | | | | | | | x | | | | | | | x | | | | | | | | x | | | | | | | | | x | | | | | | | |
| Guideline 11 | | | | | | x | | | | | | | x | | | | | | | x | | | | | | | | x | | | | | | | | | x | | | | | | | |
| Guideline 12 | | | | | | x | | | | | | | x | | | | | | | x | | | | | | | | x | | | | | | | | | x | | | | | | | |
| Guideline 13 | | | | | | | x | | | | | | x | | | | | | | x | | | | | | | | x | | | | | | | | | x | | | | | | | |
| Total score | 78/91 | | | | | | | 84/91 | | | | | | | 84/91 | | | | | | | 82/91 | | | | | | | 85/91 | | | | | | | 84/91 | | | | | | | | |

Table 5.30: Rating by appraiser 3

| Domains | Scope and purpose | | | | | | | Expert involvement | | | | | | | Rigour of the development | | | | | | | Clarity of the presentation | | | | | | | Applicability | | | | | | | Editorial independence | | | | | | | | | | | | |
|--------------------|-------------------|---|---|---|---|---|---|--------------------|---|---|---|---|---|---|---------------------------|---|---|---|---|---|---|-----------------------------|---|---|---|---|---|---|---------------|---|---|---|---|---|---|------------------------|---|---|---|---|---|---|--|--|--|--|--|--|
| | 1 | 2 | 3 | 4 | 5 | 6 | 7 | 1 | 2 | 3 | 4 | 5 | 6 | 7 | 1 | 2 | 3 | 4 | 5 | 6 | 7 | 1 | 2 | 3 | 4 | 5 | 6 | 7 | 1 | 2 | 3 | 4 | 5 | 6 | 7 | 1 | 2 | 3 | 4 | 5 | 6 | 7 | | | | | | |
| <i>Scale</i> | | | | | | | | | | | | | | | | | | | | | | | | | | | | | | | | | | | | | | | | | | | | | | | | |
| Guideline 1 | | | | | | | x | | | | | | x | | | | | | | x | | | | | | | x | | | | | | | | | | | | | | x | | | | | | | |
| Guideline 2 | | | | | | | x | | | | | | x | | | | | | | x | | | | | | | x | | | | | | | | | | | | | | x | | | | | | | |
| Guideline 3 | | | | | | | x | | | | | | x | | | | | | | x | | | | | | | x | | | | | | | | | | | | | | x | | | | | | | |
| Guideline 4 | | | | | | | x | | | | | | x | | | | | | | x | | | | | | | x | | | | | | | | | | | | | | x | | | | | | | |
| Guideline 5 | | | | | | x | | | | | | | x | | | | | | | x | | | | | | | x | | | | | | | | | | | | | | x | | | | | | | |
| Guideline 6 | | | | | | x | | | | | | | x | | | | | | | x | | | | | | | x | | | | | | | | | | | | | | x | | | | | | | |
| Guideline 7 | | | | | | x | | | | | | | x | | | | | | | x | | | | | | | x | | | | | | | | | | | | | | x | | | | | | | |
| Guideline 8 | | | | | | | x | | | | | | x | | | | | | | x | | | | | | | x | | | | | | | | | | | | | | x | | | | | | | |
| Guideline 9 | | | | | | | x | | | | | | x | | | | | | | x | | | | | | | x | | | | | | | | | | | | | | x | | | | | | | |
| Guideline 10 | | | | | | | x | | | | | | x | | | | | | | x | | | | | | | x | | | | | | | | | | | | | | x | | | | | | | |
| Guideline 11 | | | | | | x | | | | | | | x | | | | | | | x | | | | | | | x | | | | | | | | | | | | | | x | | | | | | | |
| Guideline 12 | | | | | | x | | | | | | | x | | | | | | | x | | | | | | | x | | | | | | | | | | | | | | x | | | | | | | |
| Guideline 13 | | | | | | | x | | | | | | x | | | | | | | x | | | | | | | x | | | | | | | | | | | | | | x | | | | | | | |
| Total score | 82/91 | | | | | | | 85/91 | | | | | | | 87/91 | | | | | | | 84/91 | | | | | | | 85/91 | | | | | | | 85/91 | | | | | | | | | | | | |

5.7.1 Calculating the domain score

It is recommended that a quality score be calculated for each of the six AGREE II domains (see Table 5.31)⁹¹. The six domain scores are independent and should not be aggregated into a single quality score. Domain scores are calculated by summing up all the scores of the individual items in a domain and by scaling the total as a percentage of the maximum possible score for that domain.⁹¹ AGREE collaborators recommended that each referral pathway (imaging protocol) guideline be assessed by at least two appraisers and preferably four because this increases the reliability of the assessment outcome. The researcher used three appraisers to validate the referral pathway (imaging protocol) guidelines developed in this study.

Table 5.31: Calculation of the domains

| Domains | Scope and purpose | Expert involvement | Rigour of the development | Clarity of the presentation | Applicability | Editorial independence |
|-------------------------------|-------------------|--------------------|---------------------------|-----------------------------|---------------|------------------------|
| Appraiser 1 | 84 | 78 | 82 | 70 | 84 | 84 |
| Appraiser 2 | 78 | 84 | 84 | 82 | 85 | 84 |
| Appraiser 3 | 82 | 85 | 87 | 84 | 85 | 85 |
| Obtained score | 244 | 247 | 253 | 236 | 254 | 253 |
| Maximum possible score | 273 | 273 | 273 | 273 | 273 | 273 |

Source:⁹¹

Since there is no suggested value to be used as a reference, the researcher used a score of above 50.00% as a reference for approving the referral pathway (imaging protocol) guidelines. The information obtained from the domain scores informed the total score and the performance of the individual domain score.

(total of obtained scores divided by a total of maximum score) x 100 = domain score.

$$(1487/ 1638) \times 100 = \mathbf{90.78\%}.$$

The aggregate score obtained was **90.78%**.

5.8 Summary

Objective 1 in this chapter was to formulate referral pathway (imaging protocol) guidelines for a patient undergoing Lodox imaging and Objective 2 was to verify referral pathway (imaging protocol) guidelines for a patient undergoing Lodox imaging. The researcher used an e-Delphi

method to engage the participants in two rounds of participation. Round 1 formulated the referral pathway (imaging protocol) guidelines and Round 2 verified the referral pathway (imaging protocol) guidelines that were developed in Round 1 of the e-Delphi. In Round 1, participants indicated that there was a need for universal referral pathway (imaging protocol) guidelines. Participants also indicated that they would not request additional imaging with a conventional x-ray system if they were able to obtain images of diagnostic value using a Lodox x-ray system. The chest was indicated as priority imaging by the participants followed by the spine, abdomen, and extremities. The skull was last in order of priority for imaging. Participants also indicated various clinical indications for specific regions of the body that should be used to refer patients for Lodox imaging.

During the verification of the referral pathway (imaging protocol) guidelines that were developed in Round 1, the following were verified by the participants: activities to be performed during the management of a polytrauma patient at prehospital setting or within hospital setting before sending patients for Lodox imaging; clinical indications for a full-body Lodox imaging or regional dedicated Lodox imaging and clinical indication for chest, spine, abdominopelvic, extremities and skull. Chapter 6 presents a discussion of these results in detail.

CHAPTER 6: DISCUSSION OF THE RESULTS

6.1 Introduction

This chapter presents a discussion of the results of the data that was analysed for the development of a referral pathway (imaging protocol) for chest imaging with Lodox x-ray systems at trauma units in South Africa. The four objectives that were pursued in the study were:

- i. To assess the diagnostic similarity of chest images of adult trauma patients acquired using a Lodox x-ray system compared to those acquired using a conventional x-ray system.
- ii. To assess the diagnostic quality of adult chest images acquired using a Lodox x-ray system compared to those acquired using a conventional x-ray system in terms of the level of size distortion, spatial resolution, contrast resolution, and image noise.
- iii. To formulate referral pathway (imaging protocol) guidelines for an adult patient undergoing chest imaging with a Lodox x-ray system.
- iv. To verify the referral pathway (imaging protocol) guidelines for an adult patient undergoing chest imaging with the Lodox x-ray system.

6.2 Diagnostic similarities of adult chest images

A total of 278 images were used in this study. These images constituted 139 conventional chest images and 139 Lodox chest images. The chest images obtained from the Lodox x-ray system were cropped from the full body scan. Each pair of the images was taken with the body in a supine position. The two image sets were obtained from the same patients within 24-hours to minimise any variations in the image due to pathology. The cropped chest images obtained from Lodox x-ray system did not show any variation from the quality of the initial image of the full body Lodox scan.

6.2.1 Artefacts and beam penetration

The x-ray beam penetration is the ability of the x-ray photon to pass through an object under examination and reach the image receptor with the details of that object.^{43,48} The remnant x-ray beam has various intensities based on the variation of the density of the object.⁶⁸ Lodox x-ray images that were retrospectively obtained (138, 99.29%) displayed good beam penetration; 102 (73.38%) of conventional x-ray systems images had the same quality (Table 4.1). Using prospective research, the conventional x-ray systems had almost the same level of penetration as the Lodox x-ray system with 37(97.37%) and 38(97.44%) respectively (see Table 4.8). According to

this outcome, the Lodox x-ray system seems to have a higher x-ray beam penetration than conventional x-ray systems.

The x-ray beam penetration on a chest radiographic image is indicated by the vertebral body just being visible at the lower part of the cardiac shadow.⁶¹ When vertebral bodies are visible throughout the chest, the image is over-penetrated and low-density lesions may be missed on a chest image.^{57,61} On the contrary, when the vertebral bodies are not visible, there is inadequate penetration and images are lighter in density than a diagnostic image.¹³⁴ The lung markings significant for the diagnosis of interstitial disease and air spaces may be exaggerated by underexposure leading to misdiagnosis.⁵⁷ If the image is under-penetrated, lung fields will appear falsely white causing missed diagnosis.⁶¹ Under-penetration may also result in poor visibility of the left hemidiaphragm, lung vasculature and lung air spaces resulting in lung appearing opaque, mimicking or hiding a disease of the left lower lobe for example pneumonia and pleural effusion.⁵⁷ Under-penetration may also result in blood vessels in the lung appearing more prominent than they are.⁵⁷ Similarly correct selection of technical factors such as kVp and mAs and correct centering of the beam when using automatic exposure control (AEC) is important in radiographic imaging.^{2,43} Kilovoltage peak (kVp), milliampere per second (mAs) and AEC determine the level of penetration of the x-ray beam.^{67,74} Under-penetrating and faulty centering of the central x-ray beam may also hide disease or mimic a pathology.⁵⁸

On the images that were obtained retrospectively, exposure artefacts were seen on 29 (20.86%) of the images, rated to have good visibility while 4 (2.88%) of images showed artefacts as partially visible (Table 4.1). There were no exposure artefacts seen on the images from the Lodox x-ray system (Table 4.1). In the prospective study, the researcher positioned the patient, observed the motion of the patient, and gave the respiratory command to the patient.⁴⁷ Additionally, the participants were conscious and able to respond to the radiologist's instructions during the radiographic examination. This may have reduced the artefacts to 4(10.53%) on conventional x-ray systems (Table 4.8). Overall, the presence of artefacts could be contributed by the patient's condition, as well as the radiographic technique used in the positioning of the patient.^{47,135} The retrospective chest x-rays were performed as mobile radiography, which is prone to exposure artefacts.¹³⁶ Similarly, the chest images obtained from the Lodox x-ray system were taken on unconscious patients who might have had radiopaque materials as well as uncontrolled motion during the Lodox imaging. This could be the cause of the high prevalence of artefacts on images that were obtained retrospectively. The exposure artefacts and chevron artefacts hinder diagnosis.¹³⁶

An artefact is any irregularity on an image that is not caused by the proper shadowing of the tissue by the primary beam.¹³⁷ Artefacts are also undesirable optical densities, structures, or blemishes recorded on a radiographic image.^{136,138} Artefacts interfere with the visualisation of the radiographic image details and may lead to misdiagnosis.¹³⁸ Exposure artefacts occur during the examination and may be caused by the motion of the patient or improper patient positioning.¹³⁵ A correctly exposed PA chest film is one in which the ribs and spine are identifiable behind the cardiac shadow but the lungs are not overexposed.⁵⁸ An incorrectly positioned chest image is one where the medial ends of the clavicles are equidistant from the thoracic vertebrae, lung fields are equal and have similar densities.^{47,58} Exposure artefacts are the leading cause for retaking examinations, which raises the radiation dose on a patient.¹³⁵⁻¹³⁶ Patient motion is caused by improper preparation of the patient, lack of communication skill or patient condition.⁴⁷ Improper patient positioning, inadequate radiographic technique skills, patient condition, double exposure and radiopaque materials are the causes of exposure artefacts on an image.¹³⁵ They cause overlapping of anatomical structures, obscuring, distortion and magnification of the Region of Interest (ROI).^{2,136} Improper radiographic techniques like the incorrect positioning of the patient hinder diagnosis or may cause misdiagnosis which would lead to incorrect treatment.¹³⁵

This research found that over 74.00% of images from both conventional x-ray systems and Lodox x-ray systems had a good x-ray penetration. A good penetration indicates that both Lodox x-ray systems and conventional x-ray systems may diagnose low-density lesions, lobar pneumonia and pleural effusion which are hindered by low beam penetration. Overall, both imaging systems produced images with fewer exposure artefacts resulting in improved image quality.

6.3 Visualisation of lung parenchyma tracheobronchial and vascular patterns

6.3.1 Anatomy of lung parenchyma

Lung parenchyma is the functional part of the lung outside the circulatory system that is involved in gaseous exchange.¹³⁹⁻¹⁴⁰ Lung parenchyma has many thin-walled alveoli, forming a large surface area, that maintains gaseous exchange within a lung.¹³⁹ Lung interstitial is also a part of the lung parenchyma, consisting of connective tissue, lymphatics tissue, blood vessels and bronchi.⁵⁷ Diseases that affect the lung parenchyma can either be airspace diseases or interstitial diseases.⁵⁷ In this research, both the Lodox x-ray and conventional x-ray systems had over 84.00% visibility of lung parenchymal structures. The conventional x-ray systems had 117 (84.17%) and the Lodox x-ray systems had 137 (100.00%). These findings show that the anatomy of the lung parenchyma is well-visualised on both imaging systems and therefore images produced may be used to inform on any pathological changes that are associated with lung parenchyma.

6.3.2 Anatomy of tracheobronchial structures

Normally, the trachea lies midway, or slightly to the right of the mid-sagittal plane and between the medial ends of the clavicles.⁵⁸ Tracheal shift to the right of the patient is suggestive of tracheobronchial injuries in trauma.⁵⁶ On lateral radiographs of the cervical spine, a high position of the hyoid bone associated with deep cervical emphysema can be an important indication of tracheal transection.¹⁴¹ The defect in tracheal contour, deviation of the endotracheal tube tip, or tubal cuff over-distention or protrusion beyond the edge of the tracheal wall¹⁴² are more specific signs of tracheobronchial rupture.⁵⁶ A tracheobronchial lesion may be seen as a “bayonet sign” when a sharp angulation of the normal tracheal column or the bronchial lumen occurs.⁵⁶ The “fallen lung” sign, maybe visible when an air leak through an injured tracheobronchial wall is collapsing the hilus; this indicates a complete rupture or transection of the main bronchi.⁵⁶ A bronchocele (alias pneumatocele) may also be detected after blunt trauma. This is a consequence of compression or decompression trauma of the chest that causes a rupture of the small airways which are seen as round, radiolucent areas on a chest x-ray (CXR).⁵⁶ A deep cervical emphysema with paratracheal air is also a radiological manifestation of tracheobronchial injury.⁵⁶

This research found that conventional x-ray systems displayed tracheobronchial structures on 89 (64.03%) of images presenting as good and 40 (28.78%) as partly visible while 5 (3.6%) did not show tracheobronchial structures. The Lodox x-ray systems displayed tracheobronchial anatomy on 138 (99.28%) of the images having good visibility with only 1 (0.72%) as partly visible. The findings show that the Lodox x-ray systems displayed the tracheal bronchial system better than the conventional x-ray systems. This coincides with findings during a pilot study conducted by Daya et al. (2009), which found that the Lodox x-ray system was better than conventional x-ray systems in showing the tracheobronchial structures.⁴²

6.3.3 Anatomy of the pulmonary vasculature

Pulmonary vasculature includes both the pulmonary artery and pulmonary veins.⁵⁷ It acts as a barrier between blood, gas, and tissue.^{53,143} These arteries can be identified by x-ray images within normal lungs.⁵⁸ Blood vessels appear white and characteristically branch and taper gradually from the hila centrally to the peripheral margins of the lungs.⁵⁷ Blood vessels at the lower lobes of the lung are usually more angled than those at the upper lobe, on an image performed on an erect patient, due to the gravitation pull of the blood pool.⁵⁷ Generalised enlargement of blood vessels extending to the periphery of the lung, suggest an infection or an obstructive lung disease.¹⁴³ These are also indicators of pulmonary hypertension caused by emphysema and small airway diseases.¹⁴³ The ascending aorta should normally not project

further to the right than the right heart border. The aortic knuckle is normally <35 mm (measured from the edge of the air-filled trachea) and will normally push the trachea slightly to the right. The main pulmonary artery segment is usually concave or flat.

In this research, the anatomy of pulmonary vasculatures was displayed on images obtained from the conventional x-ray systems (253, 91.01%) as having good visibility with 25 (17.99%) of the images having partially visible pulmonary vasculature. On the other hand, the Lodox x-ray systems displayed pulmonary vasculatures on all its images (139, 100.00%) with good visibility. This indicates that the Lodox x-ray systems were superior in showing the pulmonary arteries and veins.

6.3.4 Disorders of the lung parenchyma and their pathological patterns

The results of the visualisation of lung parenchyma on the two sets of images are discussed below under two sub-sections. Sub-section a) interstitial (infiltrative) diseases and their presentation patterns, and subsection b) airspace (alveolar) diseases and their presentation patterns.

6.3.4.1 Interstitial (infiltrative) disease and their presentation patterns

Interstitial changes (interstitial opacities alias infiltrates) are disease patterns formed by processes that thicken the interstitial compartments of the lung.⁵⁷ The lung interstitium consists of structures surrounding and supporting airspaces.⁵⁷ These structures are connective tissue, lymphatics, blood vessels and bronchi.⁵⁷ Fluid, blood, tumour cells, or fibrous tissue may result in inflammation that may render the interstitial space visible on a radiograph.⁵⁹ Interstitial lung disease produces patterns of discrete “particles” that develop in the interstitial network of the lung.⁵⁷ Margins in interstitial lung disease are sharper than are the margins of airspace disease, where boundaries tend to be indistinct.⁵⁷ Radiographic patterns of interstitial disease are subdivided into reticular/ground-glass, reticulonodular, nodular and linear patterns on plain radiographs. Interstitial patterns of opacity produced depend on the nature of the underlying disease and the portion of the interstitial tissues affected.⁵⁹ On the similarity of the images from the conventional x-ray systems and those from the Lodox x-ray systems, conventional x-ray systems displayed interstitial changes on 24 (17.27%) of the images while the Lodox x-ray systems displayed interstitial changes on 27 (19.42%) of the images (see Table 4.3) One hundred and twelve (112, 80.58%) of the total images from the Lodox x-ray systems showed that interstitial changes were absent. On the same images, the conventional x-ray systems displayed lung infiltrate on 87 (62.59%) of images as having good visibility. On the other hand, Lodox x-ray systems displayed lung infiltrate on 90 (65.22%) as a having good visibility. In both cases, images obtained using the Lodox x-ray systems, showed the interstitial changes and interstitial diseases

of the lung. It may, however, be concluded that the Lodox x-ray systems showed the interstitial and lung infiltrate patterns better than conventional x-ray systems but not with any significant difference.

- **Pulmonary contusion**

Pulmonary contusion (alias lung contusion) is the most common parenchymal lung injury seen in a blunt injury of the thorax.⁵⁶ Pulmonary contusion is a haemorrhagic oedematous focal deposit, suggestive of damage to the alveolar and interstitial matter.⁵⁶ Parenchymal contusion is the most common cause of pulmonary opacity on CXR after blunt chest trauma, occurring in 30.00–75.00% of patients.^{54,56} This injury occurs through a direct blow adjacent to a normal lung or a contra-coup injury within the lung parenchyma.⁵⁴ Rib or spinal fractures are often associated with a pulmonary contusion.⁵⁴ The mortality rate for lung contusion varies from 14 to 40.00%, depending on the severity.⁵⁶ Radiographically, pulmonary contusion presents as focal or multifocal areas of confluent “ground-glass” opacity indicative of interstitial injury.⁵⁶ Pulmonary contusion often affects the base of the lung field due to basilar motility.⁶¹ Contusions are radiographically invisible immediately after trauma, but the evidence presents after 6 hours and within 24 to 72 hours after the injury.^{54,56} On a radiographic image, air bronchograms are usually absent due to blood filling the small airways.⁵⁴ CT imaging can detect pulmonary contusion in 100.00% of cases compared with 37.50% using chest radiographs.⁵⁴ Therefore, a contrast-enhanced CT imaging of the chest remains the gold standard modality of choice in the immediate diagnosis of this injury.

In this research, conventional x-ray systems displayed lung contusion on 24 (17.27%) of the images as having good visibility; 9 (6.47%) of images as partially visible; and 4 (2.88%) as poorly visible while 102 (73.38%) images showed no pulmonary contusion. The Lodox x-ray systems displayed that all the images 139 (100.00%) had no lung contusion. It can be concluded that conventional x-ray systems were superior, with 17.27% detecting pulmonary contusion, in comparison to the Lodox x-ray systems. The outcome of this finding could be because Lodox imaging was performed immediately after the patient arrived at the trauma hospital, and before the 6-8 hours in which pulmonary contusion starts to appear on the images.¹⁶ Noteworthy, is that this objective focused on the conventional x-ray systems images and the Lodox x-ray systems images that were performed within 24 hours and not within six hours. Therefore, further research is suggested to confirm the findings.

- **Bullae**

Bullae are air-containing lesions in the lung parenchyma that measure between 1 to 2 cm in diameter.⁵⁷ Bullae develop as a result of the destruction of the walls between alveoli, forming tiny air sacs, which are transformed into large air-filled spaces.⁶² Bullae form a thin continuous wall of less than one millimetre that is partially visible on conventional radiography but seen on CT images.⁵⁷ Bullae also appear as large, radiolucent, air-filled sacs that are found predominantly at the apices or the bases of the lung and may be large enough to cause respiratory insufficiency by compressing the remaining part of the normal lung.⁶² Fluids may also develop within bullae as a result of infection, haemorrhage, or liquefaction necrosis.⁵⁷ When bullae cavities are filled with fluid, they appear as a solid mass on the chest radiograph.⁵⁷ On conventional radiographs their presence is often inferred by a localised paucity of lung markings, due to loss of alveolar septa.⁶² They can grow to fill the entire hemithorax and compress the lung on the affected side to such an extent that the lung seems to disappear (vanishing lung syndrome).⁵⁷ Obstructive and destructive changes in small airways (the acini or terminal bronchioles) lead to a dramatic increase in the volume of air in the lungs. These changes are radiologically seen to have bullae patterns as a confirmation of emphysema.⁶² The decrease in alveoli decreases the oxygen supply to the lung and the heart, therefore, has to compensate by increasing in size (cardiomegaly). Additionally, bullae may rupture leading to pneumothorax or atelectasis.⁶² In this research, the conventional x-ray system showed bullae on 4 (2.9%) images with good visibility while 134 (97.10%) images had no bullae. Bullae were absent on all images 139 (100.00%) of the Lodox x-ray systems. It can be inferred that conventional x-ray systems are superior in showing bullae in comparison with Lodox x-ray images.

- **Nodules**

These are solitary spherical opacities in the lung.⁵⁸ Radiographically, nodular opacities represent small round lesions filled with a mass within the pulmonary interstitial tissues which are less than 3 centimetres in diameter.⁵⁹ In contrast to airspace nodules, interstitial nodules are seen on CXR as homogeneous and sharply defined due to their margins being surrounded by normally aerated lungs.^{57,59} These interstitial nodular opacities can be subdivided based on size into military nodules (<2 mm), micronodules (2 to 7 mm), nodules (7 to 30 mm), or masses (>30 mm). Nodules and masses are most often seen in metastatic diseases of the lung.⁵⁹ CT scanning of the chest illustrates the shape of the nodules well, showing “spiculation” or “irregularity” that may not be apparent on conventional radiographs.⁵⁷

In this research, the conventional x-ray systems showed nodules on 20 (14.39%) images with good visibility, although 1 (0.72%) was partially visible and 1 (0.72%) had poor visibility. On the other hand, the Lodox x-ray systems displayed nodules on 36 (25.90%) images with good visibility while 103 (74.10%) images had no nodules. It can be inferred that the Lodox x-ray systems were better at showing the nodules than the conventional x-ray systems.

These outcomes, together with the ability of the Lodox x-ray systems to show a tracheal bronchial tree, are advantageous in determining pulmonary tuberculosis, where the radiological features are enlargement of mediastinal lymph nodes, with a possible distortion of the tracheobronchial tree in paediatrics.⁴²

6.3.4.2 Airspace (alveolar) disease and their presentation patterns

- **Ground-glass opacity**

Ground-glass opacity is a nonspecific increased opacity of the lung parenchyma that may be caused by changes in the proportion of air and alveolar wall.¹⁴⁴ It has a fine reticular pattern referred to as “ground-glass opacity”.⁵⁷ Ground-glass appearance is seen in processes that thicken the parenchymal interstitial of the lung to produce a fine network of lines with intervening lucent spaces of 1 to 2 mm in diameter.^{57,144} It is a nonspecific radiological sign which represents both interstitial and airspaces diseases.¹⁴⁵ The granularity seen in the lungs is the interplay of air-distended bronchioles and ducts against a background of atelectasis of alveoli.⁵⁷ ground-glass opacity can also reflect airspace disease when the alveolar material incompletely fills the airspaces.⁵⁹ This can be associated with bronchiectasis, fibrosis, and “honeycombing” appearance on a radiograph. Additionally, this ground-glass appearance may be indicative of conditions such as interstitial pulmonary oedema and interstitial pneumonitis¹⁴⁴. Conventional x-ray systems showed ground-glass patterns on 19 (14.07%) images with good visibility, and 4 (2.96%) were partially visible while 112 (82.96%) images had no ground-glass features. On the other hand, ground-glass opacity was absent on all Lodox x-ray system images (138, 100%). Therefore, it can be concluded that conventional x-ray systems are superior to the Lodox x-ray systems in showing ground-glass patterns.

- **Air bronchograms**

Because of the surrounding airless lung parenchyma, the visibility of air within the bronchus tree creates a radiographic pattern called an air bronchogram.⁶² An air bronchogram is a sign of airspace disease.⁵⁷ Bronchi are normally not visible on a radiograph because their walls are very thin, they contain air, and they are surrounded by air.⁵³ When fluid or soft tissue replaces the air

normally surrounding the bronchus, the air inside the bronchus becomes visible on a radiograph as a series of black, branching tubular structures called air bronchogram patterns.⁵⁷ The air space may be filled by the inflammation exudate or blood.⁵⁷ This produces opacities in the lung that can be described as fluffy, cloudlike and hazy.⁵⁷ These opacities tend to be confluent, merging into one another. The margins of airspace disease are fuzzy and indistinct. Air bronchograms or the silhouette sign may be present.⁵⁷ In this research, conventional x-ray systems displayed 44 (32.35%) images with good visibility, 2 (1.47%) images partially visible while air bronchogram was absent on 90 (66.18%) of these images. In contrast, the Lodox x-ray systems displayed air bronchograms on 68 (48.92%) images with good visibility, while 71 (51.08%) did not have these features on the images. Overall, the Lodox x-ray system was superior in showing air bronchograms compared to the conventional x-ray system.

6.3.5 Disorders of the pleura and their pattern presentations

6.3.5.1 Pneumothorax chest-x-rays (CXR)

When correctly performed, a CXR may show a tension pneumothorax, a large haemothorax; and other conditions that require immediate treatment.⁵⁶ Pneumothorax occurs when air enters the pleural cavity due to pressure normally present in the pleural space rising higher than the intra-alveolar pressure.^{57,134} Pneumothorax may result in a partial or complete collapse of the lung.⁶² Pneumothorax affects 60.00% of patients with severe thoracic trauma and can be fatal even in the absence of other injuries.⁵⁶ It most commonly results from rupture of a sub-pleural bulla, either as a complication of emphysema or as a spontaneous traumatic event.⁶² Other causes of pneumothorax are traumatic incidences like stabbing, gunshots, or fractured ribs. Iatrogenic causes of pneumothorax are lung biopsy or the introduction of a chest tube for thoracentesis.⁵⁶ Regardless of the cause, the increased air in the pleural cavity compresses the lung and causes it to collapse. The collapse may cause the patient to experience sudden, severe chest pain and dyspnoea (difficulty in breathing). The definitive radiological sign of a pneumothorax is displayed by the presence of a visceral pleura line indicating a spatial relation with the chest wall.⁵⁷ This is also indicated by the presence of an air-filled interface in the pleural space.⁵⁷ In addition to routine full-inspiration images, a PA radiograph or an anteroposterior radiograph should be obtained with the lung in full expiration to allow identification of small pneumothoraxes.^{47,62} This manoeuvre causes the lung to decrease in volume and become relatively denser, whereas the volume of air in the pleural space remains constant and is easier to detect. Small pneumothoraxes may be evident on lateral decubitus images.⁴⁷ In this position, air rising to the highest point in the

haemothorax is more clearly visible over the lateral chest wall than on erect views with a small amount of air in the apical region that may be obscured by overlying bony densities.^{47,62}

When an expiration radiograph is taken, it shows a complete collapse of the ipsilateral lung and depression of the hemidiaphragm. The heart and mediastinal structures shift toward the opposite side, severely compromising cardiac output. This is because the elevated intrathoracic pressure decreases venous return to the heart of a tension pneumothorax is not treated.⁶² On an AP supine-positioned patient, the air in a large pneumothorax may collect anteriorly and inferiorly in the thorax; displacing the costophrenic sulcus inferiorly, while at the same time, producing increased lucency of the same costophrenic sulcus.⁵⁷

In this research, conventional x-ray systems showed a pneumothorax on 20 (14.39%) images with good visibility; 9 (6.47%) of these images were partially visible; and 3 (2.16%) were poorly visible, while 107 (76.98%) images had no pneumothorax. The Lodox x-ray systems displayed pneumothorax on 8 (8.76.00%) images and 131 (94.24%) had no pneumothorax. Overall conventional x-ray systems were superior in showing pneumothorax compared to the Lodox x-ray systems. Because of the significant difference between the percentages, the images obtained from the Lodox x-ray systems may not be reliable in showing these features.

6.3.5.2 Pleural Effusions

Extravascular fluid can also accumulate in serous cavities to produce pleural, pericardial effusions and peritoneal ascites.⁶² The accumulation of fluid in the pleural space is a nonspecific finding that may be caused by a wide variety of pathologic processes.⁵⁶ The most common causes include congestive heart failure, pulmonary embolism, infection (especially tuberculosis), pleurisy, neoplastic disease, and connective tissue disorders.⁵⁶ Pleural effusion can also be the result of abdominal diseases, such as recent surgery, ascites, sub-phrenic abscess, or pancreatitis. The earliest radiographic finding in pleural effusion is blunting of the normally sharp angle between the diaphragm and the rib cage (the costophrenic angle) along with an upward concave border of the fluid level, also called the meniscus.⁶² Because the costophrenic angles are deeper posteriorly than laterally, small pleural effusions are best seen on the routine lateral projection posteriorly.⁴⁷ As much as 400 mL of pleural fluid may accumulate and still not produce blunting of the lateral costophrenic angles on erect frontal views of the chest.⁶²

Larger amounts of pleural fluid produce a homogeneous opaque density (or whiteness) that may obscure the diaphragm and adjacent borders of the heart. Massive effusions may compress the adjacent lung and even displace the heart and mediastinum to the opposite side. Small pleural effusions may be difficult to distinguish from pleural thickening and fibrosis which results from

previous pleural inflammation and appears radiographically as a soft tissue density along the lateral chest wall.⁶² The diagnosis of a small pleural effusion is best made by radiography performed with the use of a horizontal x-ray beam where the patient is in a lateral decubitus position with the affected side down. When the patient is positioned in a slight lateral Trendelenburg position, as little as 5 mL of pleural fluid may be seen as a layer of linear opacification along the dependent chest walls.⁶²

A pleural fluid collection that has become fixed by inflammatory fibrosis, may mimic a solid mass.⁶² Pleural fluid may also collect below the inferior surface of the lung (subpulmonic effusion) and give the radiographic appearance of an elevated hemidiaphragm.⁶² In patients with congestive heart failure, an effusion may develop in an interlobar fissure to produce a round or oval density resembling a solitary pulmonary nodule.⁶² As the patient's heart condition improves, repeat examinations may show a decreased size or complete resolution of these phantom tumours.⁶² When the effusion reaches about 300 mL in size, it blunts the lateral costophrenic angle, which is visible on erect PA/AP chest radiographs.⁵⁷ CT images can show small pericardial effusions, although pericardial ultrasonography is usually the imaging modality of the first choice.⁵⁷ Conventional radiographs are poor at defining a pericardial effusion.⁵⁷ Pericardial effusion may signify viral PTB and trauma.⁵⁷

In this research, conventional x-ray systems displayed pleural effusion on 38 (27.34%) images with good visibility; 7 (5.04%) were partly visible, 2 (1.44%) were poorly visible, and it was absent on 92 (66.19%) images. The Lodox x-ray systems displayed, pleural effusion on 30 (21.58%) images with good visibility while 109 (78.42%) Lodox x-ray system images showed no pleural effusion. Conventional x-ray systems were superior to the Lodox x-ray systems in showing pleural effusions.

6.3.5.3 Surgical /subcutaneous emphysema

Subcutaneous emphysema is a secondary complication from a trauma caused by penetrating or blunt injuries; that disrupt the lung and parietal pleura, forcing air into the tissues of the chest wall.^{56,62} Presentation of surgical emphysema is often an indication of osseous injuries.⁵⁶ Deep cervical emphysema paratracheal air and pneumothorax are radiological manifestations of tracheobronchial or oesophageal injuries.⁵⁶

Cervical-thoracic subcutaneous emphysema is the most common finding among (65–87%) trauma cases.⁵⁶ Clinically when palpating the skin, there is a crepitation sound (a crackling sound or sensation).⁶² The radiographic appearance of subcutaneous emphysema is bizarre with streaks of lucence outlining muscle bundles.⁶² In this research, the conventional x-ray systems showed

subcutaneous emphysema on 20 (14.49%) of the images with good visibility; 1 (0.72%) partly visible; 3 (2.17%) poorly visible, and 114 (82.61%) of the images showed no subcutaneous emphysema. The Lodox images showed subcutaneous emphysema in 26 (18.71%) images, while 113 (81.28%) images showed no subcutaneous emphysema. It can be deduced that the Lodox x-ray systems were superior to conventional systems in showing surgical emphysema. There was also a marginal percentage difference between the two imaging systems.

6.3.6 Mediastinal structures and associated pathologies

6.3.6.1 Mediastinal injuries

The mediastinum and cardiac outlines should be seen.⁵⁸ The right superior mediastinal border is usually straight or slightly curved; as it passes downwards, to merge with the right heart border.⁵⁸ On a radiographic image, the changes in mediastinum to chest width ratio (>0.25), irregular aortic knob, blurred aortic contour, and trachea shifted to the patient's right are indicative of mediastinal injury.⁵⁶ In this research, conventional x-ray images displayed mediastinal injuries on 2 (1.45%) of the images with good visibility; 2 (1.45%) partially visible, 1 (0.72%) poorly visible while 133 (96.38%) showed no lesions. No images (139, 100%) from the Lodox x-ray systems showed any mediastinal injuries. Conventional x-ray systems were therefore superior in showing mediastinal injuries compared to the Lodox x-ray systems. On the contrary, a literature review indicated that the Lodox was efficient in showing mediastinal injuries.¹²

6.3.6.2 Pneumomediastinum

This condition is also known as mediastinal emphysema.⁶² A high-energy deceleration during a car accident may result in a hematoma of the lower neck and central chest.⁵⁶ The presence of such a haematoma may be displayed on a chest radiograph as a 'seatbelt sign'.⁵⁶ This sign is suggestive of cervical blood vessel injuries (carotid artery) injuries. Air within the mediastinal space may appear spontaneously resulting from chest trauma, perforation of the oesophagus or tracheobronchial tree, or the spread of air along fascial planes in the neck, peritoneal cavity, or retroperitoneal space. Spontaneous pneumo-mediastinum usually results from a sudden rise in interalveolar pressure (e.g., because of severe coughing, vomiting, or straining) that causes alveolar rupture and the dissection of air along blood vessels in the interstitial space to the hilum and mediastinum. Air may also extend peripherally and rupture into the pleural space, causing an associated pneumothorax.⁶²

According to Eisenberg et al. (2015), on frontal chest radiographs, air causes lateral displacement of the mediastinal pleura, which appears as a long linear opacity that runs parallel to the heart

border but is separated from it by the air (i.e., the broncho-vascular sheath).⁶² On lateral projections, air is typically seen to have collected behind the sternum extending in streaks downward and anterior to the heart. Chest radiographs may also show air outlining the pulmonary arterial trunk and aorta and dissecting into the soft tissue of the neck. In infants, mediastinal air causes elevation of the thymus. Loculated air confined to one side produces an appearance like that of a windblown sail. Bilateral mediastinal air elevates both thymic lobes, to produce an angel-wings configuration.⁶² In this research, both conventional x-ray system (37; 97.37%) and Lodox images (37; 94.87%) images displayed no pneumomediastinum (absent) while on 1 (2.63%) conventional x-ray system and 2 (5.13%) Lodox (2, 5.13%) images pneumomediastinum were well-visualised although the Lodox x-ray system demonstrated pneumomediastinum on more images. The two imaging systems can be described as having an almost identical ability for the visualisation of the features inconsistent with pneumomediastinum.

6.3.6.3 Cardiac and aortal outline visualised

The heart lies within the mediastinum, obliquely; and on average, one-third of the heart lies to the right of the midsagittal plane, creating a silhouette sign.^{53,58} In adults, the cardiothoracic ratio is <50%⁵⁷. Cardiac injury due to penetrating or blunt thoracic trauma is rare and, when an injury occurs, it is often associated with high morbidity and mortality.⁵⁶ Therefore, early diagnosis is crucial.⁵⁶ A pericardial effusion is the main diagnosis possible on a radiograph or CT image.⁵⁴ A pericardial injury may result from severe blunt injury or penetrating trauma.⁶⁵ Noteworthy, is that conventional radiographs are poor in showing a pericardial effusion when compared with CT images.⁵⁷ Ultrasonography is the first imaging examination of choice if a pericardial effusion is suspected.⁵⁷

A large pleuro-pericardial or diaphragmatic pericardial rupture may result in cardiac herniation accompanied by a shift of the cardiac silhouette.⁶⁵ On a chest radiograph, pericardial injury is displayed as irregular convexities of the heart border; a sign referred to as a “snow cone sign”.⁶⁵ Additionally, pneumo-pericardium is a reliable sign of a pericardial injury.⁵⁶ It is radiographically displayed as the air surrounding the heart.⁵⁷ Pericardial injuries can be complicated by a diaphragmatic rupture and cardiac herniation that results in severe cardiac failure.⁵⁶

On a radiograph, a pericardial tear can be detected by both irregular margins and a disrupted outline of the pericardium.⁵⁶ CXRs may also show cardiac-related pathologies like lodged foreign bodies, pneumopericardium, congestive cardiac failure and mediastinal widening.⁵⁶ On a CXR, large pleuropericardial or diaphragmatic pericardial ruptures can result in cardiac herniation and

a shift of the cardiac silhouette.⁵⁶ Generally, any unclear aortic contour is always a suggestive sign of aortic injury.⁵⁶ In this research, conventional x-ray systems displayed the cardiac and aorta outline on 111 (80.43%) images with good visibility, 24 (17.39%) with partial visibility, 1 (0.72%) with poor visibility and 2 (1.45%) with no cardiac and aorta outline. The Lodox x-ray systems showed a good outline of the cardiac and aorta on 138 (99.28%) images, while 1 (0.72%) image did not show the outline of the cardiac and aorta. Although conventional images showed a high proportion (80.43%) of lesions with good visibility, the Lodox x-ray systems clearly showed a superior ability to show the cardiac and aorta outline in 99% of the images which were assessed.

6.3.7 Structures of the thoracic cage and associated pathologies

6.3.7.1 Soft tissues of the thoracic wall and mammary gland

The chest wall consists of the skin, subcutaneous fat, and muscles; soft tissues lateral to the bony thorax should be smooth, symmetric, and homogeneous in density.⁵³ On a CXR, breast shadows should be visible and must be homogenous bilaterally.⁵⁹ Abnormal pulmonary opacities or translucencies should be visible.⁵⁹ A unilateral hyperlucency may be due to mastectomy.⁵⁹ In addition, no abnormal pulmonary opacities or translucencies on a radiograph are important.^{59,65} However, the pectoral muscles, breasts or plaits of hair should not be mistaken for pulmonary opacities.⁶² Skin lumps or the nipples may mimic pulmonary nodules.⁶² A skinfold may also mimic pneumothorax and must not be mistaken for the visceral line.⁵⁷ Unlike pneumothorax, a radiographic feature of a skinfold is a thick white band of density; while a viscera pleural white line is convex outwards assuming the shape of the lung.⁵⁷ The nipples are usually in the fifth anterior rib space, but they are, in practice, rarely misdiagnosed because, in general, if one nipple is visible the other should also be seen unless a mastectomy has been performed.⁵⁹ A variety of skin lesions such as moles, nevi, warts, neurofibromas and accessory nipples may produce a nodular opacity on frontal radiographs that mimics a solitary pulmonary nodule.⁵⁹

In this research, conventional x-ray systems displayed the soft tissue of the thoracic cage on 101 (72.19%) images with good visibility, 17 (12.32%) with partial visibility, while 20 (14.49%) of the images did not show soft tissue of the thoracic wall. On the other hand, the Lodox x-ray systems showed the soft tissue of the thoracic wall on 138 (99.28%) images; with only 1 (0.72%) image that did not show soft tissues. Although there was no significant difference shown, the Lodox x-ray systems, with 99.28%, appears to be superior in showing the soft tissue of the thoracic cage compared to the conventional x-ray systems.

On the visualisation of mammary glands, the conventional x-ray systems showed mammary gland tissue on 30 (22.06%) of the images with good visibility and 10 (7.35%) with partial visibility while

96 (70.59%) did not show the outline of the soft tissue of the mammary gland. The Lodox x-ray systems showed the mammary gland tissue on 30 (21.58%) images with good visibility while 109 (78.42%) images did not show the outline of the mammary gland. The conventional x-ray systems were superior in showing the outline of the mammary gland compared to the Lodox x-ray systems.

6.3.7.2 Fractures of ribs and clavicles

On a CXR, ten to twelve posterior pairs of symmetric ribs should be visible and five to six anterior ribs.^{47,57} Cervical ribs are identified in approximately 2.00% of individuals and may be associated with symptoms of thoracic outlet syndrome. Costal cartilage calcification is seen in most adults. It increases in prevalence with advancing age and can add multiple shadows to the PA view.

Rib fractures are the most common skeletal injury in blunt chest trauma appearing in 50.00% of the patients.⁵⁶ The rate of complications, such as pneumothorax, haemothorax, pulmonary contusion, flail chest, pneumonia and atelectasis rises with the number of fractured ribs.⁵⁶ The brachial plexus and subclavian blood vessels are associated with injuries of the upper ribs and clavicle.^{56,60} On the other hand, fractures of the lower three ribs are associated with trauma of the liver, spleen, kidneys and lungs.⁵⁹

Therefore, rib fractures of the 10th, 11th and 12th ribs might be indicators of coexisting thoracic or abdominal trauma.⁵⁶ The standard initial imaging study required for showing ribs and clavicle fractures after trauma is chest AP, lateral and rib projections.⁴⁷ CT imaging of a chest is the imaging study of choice when showing injuries of the chest⁵⁶. On a radiograph, rib fractures are seen as a thin vertical lucency.⁵⁹ Only 50.00% of rib fractures can be detected with chest radiography.⁵⁶ In about 50.00% of injuries, fractures of the first two ribs are associated with the thoracic aorta and other thoracic vascular injuries.^{56,59} The presence of three or more rib fractures has an increased indication of haemothorax, pneumothorax, spleen injury and liver injury.⁵⁶ The fracture of the first three ribs is an indication of high-energy impact since these ribs are short, broad and well-protected by the scapular, clavicle and muscles of the upper thoracic and neck.⁵⁶ The fracture of the first two ribs is associated with the thoracic aorta and other thoracic vascular injuries⁵⁶. Clavicle fractures account for 2.6–5% of all fractures.⁵⁶ The distal third of the clavicle is the most common fracture site in blunt trauma.⁵⁹ Clavicle fracture is an indicative sign of a large amount of energy having been transmitted to the chest wall and deeper structures.⁵⁶

In this research, conventional x-ray systems showed fractures of the ribs and clavicles on 27 (19.42%) images with good visibility and 6 (4.32%) with partial visibility, while 106 (76.26%) did not show a fracture of the ribs or clavicles. The Lodox x-rays systems showed fractures of ribs and

clavicles on 17 (12.23%) images whereas on 122 (87.77%) of the Lodox images the fractures of ribs and clavicles were absent. Although the Lodox x-ray systems can show fractures of the ribs and clavicles, conventional x-ray systems were superior in showing these pathologies.

6.3.7.3 Fracture of the thoracic spine

Thoracic spine fractures account for 16.00% to 30.00% of all spine fractures.⁶⁰ It was recorded that 70.00–90.00% of thoracic spine fractures could be displayed on conventional images.⁶⁰ Fractures of the thoracolumbar spine occur in up to 18.00% of blunt trauma patients.⁵⁶ Despite a different function, a thoracic spine is seen on a CXR across the cardiac shadow.⁵⁷ On an image, a fracture of the spine may be displayed by abnormal vertebral body size, shape, malalignment of the spinous process, transverse processes, cortical disruptions, opacity and location.⁶² Possible functional symptoms indicating fractures is a loss of motor or sensory function and failure in the regulation of bowel, bladder, blood pressure, heart rate or breathing.⁵⁶ Approximately 16–30.00% of all spine fractures are thoracic spine fractures, and about 50.00% of patients presented with associated focal neurologic deficit.⁵⁶ Spinal cord injuries with a neurologic deficit are present in every 13th patient presented as a polytrauma.⁵⁶ On a radiographic image, thoracic vertebral bodies should be vertically aligned, with visualisation of the endplates, pedicles, and spinous processes.⁵⁹ Bilateral anterior and posterior cortical margins of the thoracic vertebral bodies should be aligned with no disruption.⁵⁹ Fractures of the cervicothoracic spine may also be associated with sternal fractures because of an over-flexion of the trunk. Approximately 16.00–30.00% of all spinal fractures are thoracic spinal fractures and about 50.00% of patients present with associated focal neurologic deficit.

In this research, the conventional x-ray systems displayed fractures of thoracic spines on 1 (0.74%) image as partially visible and 3 (2.22%) images as poorly visible, while 131 (97.04%) images did not show thoracic spine fracture. Lodox x-ray systems did not show any thoracic spine on 138 (100.00%) of the images. In summary, neither conventional x-ray systems nor the Lodox x-ray systems were reliable in showing thoracic spine fractures.

6.3.7.4 Fracture of the vertebral body and spinous process fracture

On a chest image, the vertebral injuries may be identified by assessing the alignment of the vertebra, spinous process, vertebral body height and disc space height.⁶⁴ Spinous processes must lie on a straight line and be equidistant from the lateral aspect of the vertebrae.⁶⁴ The loss of intervertebral and vertebral body height is indicative of compression fracture.^{57,64}

In this research, the conventional x-ray systems displayed the fracture of a vertebral body and spinous process on 3 (2.19%) images as poorly visible, while 134 (97.81%) of the images did not show any fracture of a vertebral body or spinous process fracture. On the other hand, no Lodox x-images (139, 100.00%) showed fractures of a vertebral body or spinous processes. Although the fractures of a vertebral body and spinous process were not rated as having good visibility, conventional x-ray systems were superior to those of the Lodox x-ray systems.

6.3.7.5 Diaphragms

The upper surfaces of the diaphragm should be visible from one costophrenic angle.⁵⁸ The dome of the right hemidiaphragm is at the level of the anterior end of the sixth rib, the right hemidiaphragm being up to 2.5 cm higher than the left.⁵⁸ The right hemidiaphragm overlies the liver, and the left hemidiaphragm overlies the stomach and spleen. The most noticeable signs of diaphragmatic rupture seen on chest radiography are definite visualisation of abdominal viscera above the diaphragm (with or without a focal constriction of herniated viscera as they pass through the violated diaphragm (the collar sign)) and visualisation of the tip of a nasogastric tube above the diaphragm.⁵⁶ The unexplained elevation of a hemidiaphragm of 6 cm elevation of either hemidiaphragm; is correlated with injury to that hemidiaphragm.⁵⁶ In this research, conventional x-ray images displayed a diaphragm on 91 (65.47%) of the image's good visibility, 44 (31.65%) with partial visibility while 4 (2.88%) had no visibility on these images. On the other hand, the Lodox x-ray systems showed the diaphragm on 114 (82.01%) images with good visibility, 24 (17.27%) with partial visibility and 1 (0.72%) with poor visibility. Overall, the Lodox x-ray systems were superior in showing the diaphragm.

6.3.7.6 Extra-luminal air

Extra-luminal is air outside the bowel.⁵⁷ It is recognised by air beneath the diaphragm. Air will rise to the highest part of the abdomen. In the upright position, free air will usually reveal itself under the diaphragm as a crescentic lucency that parallels the under-surface of the diaphragm.⁵⁷ In the supine position, a small amount of free air will not be displayed on chest x-ray (CXR) images.⁵⁷ Free air is more easily seen on the right diaphragm than on the left diaphragm due to a gastric bubble on the left and discrete density on the liver on the right side.⁵⁷ In this research, conventional x-ray systems showed extra-luminal air in 5 (3.62%) images with good visibility while on 132 (95.65%) of these images extra-luminal air features were absent. On the other hand, the Lodox x-ray systems displayed extra-luminal air on 4 (2.88%) images with a good visibility while 135 (97.12%) displayed no features of extra-luminal air. The two imaging systems seem to have

almost same result, although conventional x-ray systems appear superior in showing extraluminal air.

6.4 Discussion of the diagnostic quality of chest images

This section addressed the objective: to assess the diagnostic quality of adult chest images acquired using a Lodox chest-dedicated imaging programme compared to images acquired using conventional x-ray systems concerning the level of distortion, spatial resolution, contrast resolution and image noise. The diagnostic quality of adult chest images acquired using a conventional x-ray system was compared with the chest images obtained using a chest-dedicated programme of a Lodox x-ray system, concerning the level of distortion, spatial resolution, contrast resolution and image noise. This objective was to confirm the outcome in the first objective of this study where images of a CXR were obtained from full-body Lodox imaging and compared to a chest image performed using a conventional x-ray. To confirm the outcome, an image of a walk-in patient referred by a physician for a CXR was requested by the researcher to undergo an additional CXR using a Lodox x-ray system. Purposive selection was used for the walk-in patients because these patients were conscious and could respond to the radiographer's command, could retain the position and images could be taken with the patients in an erect position, unlike a trauma patient. It is expected that a good chest x-ray will be performed in an erect position the patient must be able to breathe in and be asked to hold the breath and be positioned such that the scapulae and chin are off the lung field.^{47,136}

6.4.1 Diagnostic quality of a chest images and size distortion

Distortion means unequal magnification of different portions of the same object as seen on a resultant image.^{2,74} Geometric distortion, also known as size distortion, scaling error or magnification, arises from problems that cause the displayed image to vary in size from the true size of an object when both are measured.^{2,146} Noteworthy is that measurements obtained should correspond to the actual distances were it not for distortion.¹⁴⁶ distorted image has reduced spatial resolution which is undesirable on a diagnostic image.^{2,74} Therefore, minimisation of magnification is always desirable to improve diagnosis.⁷⁴ The verification of geometric distortion can be performed by measuring the length of the image.⁶⁸ Measurements are taken on various known sizes to look at variations in geometric length. The acceptable level of distortion is 2.00% of the known distance.² Geometric distortion may be caused by the variation of SID or OID.⁷⁴ In this case, the variation of SID between the Lodox and conventional x-ray systems may produce variations in measured geometric distortion. With a longer SID, organs far from the image receptor will be magnified in comparison to those closer to the image receptor.⁷⁴ This results in a

stretched image that does not represent the true size of an object. Additionally, this results in a low radiographic image quality due to diminished image sharpness, hence degrading the diagnostic quality and subsequently the diagnosis of disease.⁷⁴

The Lodox x-ray system has a SID of 130cm whereas conventional x-ray systems have a SID of 180cm.⁴⁴ This means that the Lodox x-ray system is expected to have a magnification bigger than that obtained from the conventional x-ray systems. It was shown that the conventional x-ray system and Lodox x-ray system had an average distortion of 0.70 and 0.34 respectively. Since the Lodox x-ray system has a shorter SID, a bigger distortion would be expected than its counterpart. Conversely, the outcome of the measurements on the phantom implied that SID in these systems had little impact on distortion.

Considering the structural differences between these two systems, conventional x-ray systems use a cone-beam technology, which is associated with distortion due to the divergent nature of the beam.⁷³ Cone-beam technology implies that the x-ray beam originates from a point source within the x-ray tube and diverges as it approached an object.⁷³ It is due to this point source that the x-ray beam possesses its divergent nature when it exits the x-ray tube.⁶⁸ The only section of the beam that is not divergent is the central rays of the beam.⁷³ However, the periphery of the beam is divergent, and this is what causes non-linear distortion by stretching the size of the imaged object.^{44,68,73} The Lodox x-ray system, however, uses the Linear Slot Scanning Radiographic (LSSR) technology which differs from cone-beam technology in that the beam is highly collimated by a narrow slit to produce a very narrow slit of one millimetre in length to control the divergence of the beam along with the object; the beam is, therefore, divergent only across the object.^{44,73} These structural differences could be because of the variation of size distortion between the two imaging systems. Despite the sizes and location of some of the structures (on the AP of a chest), the variations of the level of distortion do not seem to affect the visibility of organs recorded on an image. Using the Lodox x-ray system, trachea and proximal bronchial (38/38,100.00%) (Table 4.9), cardiac and aorta outline (34/38, 89.40%) (Table 4.13) and thoracic cage and soft tissue outline (38/38, 100.00%) (Table 4.14), were rated to have good visibility on the images. Similarly, on the conventional x-ray systems, the trachea and proximal bronchial (39/39,100.00%) (Table 4.9), cardiac and aorta outline (35/39, 89.74%) (Table 4.13) and thoracic cage and soft tissue outline (39/39, 100%) (Table 4.14) images were also rated to have good visibility. The two imaging systems seem to have produced images of almost the same quality. This confirms that the level of distortion on the two imaging systems did not affect the diagnostic quality of the images produced.

6.4.2 Diagnostic quality of chest images and level of spatial resolution

The quality of a radiographic image depends on both the visibility and the accuracy of the anatomic structural lines or recorded details.^{2,74} Spatial resolution, also referred to as image details,⁶⁸ is the ability of an imaging system to accurately record small objects that have high-subject contrast.² It is also the distinctness or sharpness of the structural lines that make up the recorded image.² The ability of a radiographic image to show sharp lines determines the quality of the spatial resolution of recorded detail.^{2,74} Spatial resolution is expressed by the number of line pairs per millimetre (lp/mm) consisting of lead lines separated by interspaces of equal sizes.⁶⁸

This test pattern is also called a line-pair test pattern.⁶⁸ It is also the measure of how far apart two objects must be before they can be seen as separate details on the image.⁶⁸ The measure of spatial frequency relates to the number of line pairs in a determined length, expressed as line-pair per millimetre (lp/mm) or lines pair centimetres (lp/cm).² Quality control test tools, for example, the line-pair gauge and NORMI 13, have been designed to measure the amount of spatial resolution.⁷⁵ The higher this number is, the smaller the object that can be imaged and the better the spatial resolution.⁸⁰ Clinically, spatial resolution is the ability of an imaging system to show small, high-contrast objects, such as calcifications in soft tissue.²

The visualisation of the anatomic area of interest (brightness/density and contrast) is the desired component of radiographic quality.⁷⁴ Therefore, minimising the unsharpness of a radiographic image that has a greater spatial resolution or recorded detail of the anatomical structure improves diagnosis.⁷⁴ Spatial resolution is determined by the geometry of the focal-spot size, distortion and amount of scattered radiation.⁷⁴ Small focal spots created by an increased anode angle give better spatial resolution.⁷⁸ Reduced focal spots also reduce focal spot blur, which is an undesirable illusion that reduces spatial resolution at the edges and in the middle of the images.² In an x-ray tube of both a conventional x-ray system and a Lodox x-ray system, focal-spot blur is small on the anode side and large on the cathode side of the image.² The differences between the spatial resolution with an average of 0.4 on the two imaging systems could be due to variation of focal-spot size, image recording media (digital detectors), distortion or scatter radiation.⁷⁴ The outstanding factor is the differences in SID between the two imaging systems where the Lodox imaging system uses 130 centimetres and conventional x-ray systems use a source-image distance of 180 centimetres.⁴⁴ The image source distance affects the image's sharpness due to the increased size of the penumbra.⁷⁴ The use of a longer SID on the imaging system results in less magnification, less focal-spot blur, resulting in improved spatial resolution of an image.⁶⁸

Additionally, reduced spatial resolution can be obtained by x-ray tube motion-related unsharpness, which occurs when the x-ray tube moves during the imaging of an object. The Lodox x-ray system is made in a way that the x-ray tube moves while the image is captured.⁴⁴ Not only does this cause a penumbra but is also a source of secondary radiation which results in scatter radiation on the images and consequent lower spatial resolution.^{44,80} The results obtained after measuring spatial resolution on NORMI 13 Phantom (Figure 3.2) mean that conventional x-ray systems can record 2.37 line stripes in a distance of 1 mm while the Lodox x-ray system can record 1.97 line stripes per distance of 1 mm. Since there can never be a half line-pair, rounding up these sizes results in 2.00 stripes per distance of 1 mm on both x-ray systems. That means there is no significant difference between the Lodox x-ray system and conventional x-ray systems. Conventional x-ray systems use an anode angle between 5 and 20° and two focal-spot sizes measuring 0.6 and 1.2 mm.^{2,76} Overall the acceptable focal-spot sizes, as dictated by manufacturers of x-ray tubes, range from about 0.1 mm to ~1.2 mm.⁸⁰ The anode sizes used on the Lodox x-ray system were withheld for confidentiality purposes in terms of a non-disclosure agreement between the researcher and the Lodox company. However, the diagnostic quality of images obtained from the conventional x-ray systems and those from the Lodox x-ray system displayed almost similar outcomes on the smallest anatomical and pathological patterns of the lung (see Tables 4.9, 4.10 and 4.11).

The conventional x-ray systems and Lodox x-ray systems showed pulmonary vasculature and lung parenchyma with almost similar percentages (Table 4.9 and 4.10). The recorded details on the images obtained from the two imaging systems show that there are minor differences in recorded details of the anatomical and pathological details of the patients. This is supported by Figure 4.2 which shows almost similar levels of spatial resolution on the two imaging systems.

6.4.3 Diagnostic quality of chest images and level of contrast resolution

Contrast resolution is the ability of the imaging system to distinguish many shades of grey from black to white or images of similar subject contrast like spleen and liver or grey and white matter.^{68,74} The imaging system also can reproduce objects, such as cysts and tumours, that do not vary much from surrounding tissue in their x-ray absorption properties.⁶⁸ The principal descriptor for contrast resolution is grayscale, also called dynamic range or contrast detectability.²

Contrast resolution is determined by scatter radiation and dark noise.⁶⁸ One of the principal tools that is used to control scatter radiation is a beam-restricting device.⁶⁸ Images that have lower

noise have increased contrast resolution.⁶⁸ The three primary factors that contribute to increased scatter radiation are increased kilovoltage (kVp) and increased x-ray field size.

The x-ray field size can be reduced by beam-restricting devices that are designed to control and minimise scatter radiation by limiting the x-ray field size only to the anatomy of interest.⁴³ The Lodox x-ray system has a kVp range of 50kVp to 145kVp⁷⁷ whereas conventional x-ray systems have a range of 25kVp to 150kVp.⁴³ This indicates that conventional x-ray systems and Lodox x-ray systems have almost the same range of Kilovoltage on these systems.⁷⁷ Although these ranges of kVp have no significant variations, imaging of a patient should use a lower kVp where possible, due to increased Compton scatter radiation which could reduce contrast resolution.⁶⁸ In the Lodox x-ray system, there is minimal radiation scatter attributed to the x-ray beam and detector configuration, where a fan beam of 6 mm length (when the light reaches the detector and along the scanning length) is used.⁸¹

This beam is restricted by a narrow slit and a fan-width adjustment collimator into a laser-like fan beam of primary X-ray photons which spreads out in only one direction across the scanning direction.⁷⁷ This narrow beam reduces the number of x-rays scattered that causes the noise hence reducing the contrast resolution.⁴⁴ By contrast, in a conventional X-ray system, the X-ray beam emitted from the source has a conical shape that spreads out in four directions after collimation.⁴³⁻⁴⁴ Despite the two modalities having these structural variations, there is no significant change in the contrast resolution. The measured contrast resolution on conventional x-ray systems and Lodox x-ray systems displayed that conventional x-ray systems have an average dynamic range of 2.67 while Lodox x-ray system has a range of 2.47. This shows a marginal difference between the two systems with a value of 0.20.

Referring to the diagnostic quality of the images, both the conventional x-ray system and the Lodox x-ray system have shown the ability to successfully show the anatomical and pathological details that have the desired contrast resolution. Although with a minor significant difference, the variation on visualisation of air bronchogram, bronchi, pleural effusion, lung soft tissues and pneumothorax is seen on the air bronchograms produced by the conventional x-ray system and the Lodox x-ray system (see Table 4.11–Table 4.12). In conclusion, the two imaging systems seem to have minor variations in their ability to record the anatomical and pathological patterns of a chest.

6.4.4 Diagnostic quality of chest images and level of dark noise on the image

Radiographic noise is the random fluctuation in the optical density of an image.⁶⁸ It is also a grainy or uneven appearance of an image caused by an insufficient number of primary x-rays.⁸⁰

Radiographic noise is expressed as a signal to noise ratio (S/N).⁴³ A high signal to noise ratio indicates less noise on an image.⁴³ The signal in a radiographic image is that portion of the image-forming x-rays that represents anatomy.⁶⁸ The signal represents the difference between those x-rays transmitted to the image receptor and those absorbed photoelectrically inside the body by the object which can be a patient.⁴³ It should be noted that as noise increases, contrast on the image decreases.⁴³ Radiographic noise has fewer effects on the density in digital radiography as a computer can compensate for lack of density; therefore, the effects of noise are only in contrast.⁴³ Lower noise results in a better radiographic image because it improves contrast resolution.⁶⁸ Radiographic noise can be caused by a quantum mottle and scatter radiation.⁶⁸ Additionally the principal source of radiographic noise is scatter radiation.⁶⁸

Quantum noise refers to the random nature in which x-rays interact with the image receptor.⁴³ It is highest when very few photons interact with the image receptor than with very large numbers of photons.⁶⁸ It is recommended that a radiographer should always aim at using only adequate high mAs, low kVp and slower speed image receptors to reduce quantum mottle.⁶⁸ Although at increased mAs there is low noise, there is also an increased radiation dose on the patient.⁶⁸ Therefore a balance between the image noise and contrast resolution is essential.⁴³ Fast image receptors have high noise, low spatial resolution and low contrast resolution.⁶⁸ High spatial resolution, high-contrast resolution and low noise are essential for quality images and can be obtained from a slow image receptor.⁶⁸ The researcher used 100 kVp and 10 mAs on both the Lodox x-ray system and conventional x-ray system to obtain an image from a copper plate that was used to obtain values for the image noise. This, therefore, means that there was no discrepancy in the values of the exposure factors selected during the measurement of dark noise. The SID was for conventional x-ray systems was 180cm and that from the Lodox x-ray system was 130cm.

The three primary factors that influence the relative intensity of scatter radiation that reaches the image receptor are kVp, field size, and patient thickness.^{43,68} The radiation scatter that causes noise on an image is primarily caused by Compton interaction between the body electrons and the x-ray photons.⁶⁸ When kVp increases, the interaction between photons and electrons increases hence increasing noise on an image;⁶⁸ thus, the selection of kVp should be sufficient only to form an optimal image.⁶⁸ Additionally, the more the beam is restricted by collimation, the less the amount of radiation that reaches the image receptor and the less the scatter resulting in less noise.⁶⁸ Therefore, it is essential to reduce the noise by restricting the beam only to the Region of Interest (ROI).

This research has shown that the x-ray beam penetration was good in both the conventional x-ray system and the Lodox x-ray system. It was found that 37/38 (97.37%) of the conventional x-ray system images had good x-ray beam penetration. This was very similar to the Lodox x-ray system images of 30/39 (97.44%) which were rated to have a good x-ray beam penetration. Overall, both conventional x-ray systems and Lodox x-ray systems showed some anatomical and pathological patterns with 100.00% visibility rated as good: for example, the pulmonary vessels at the periphery of the lung field, trachea and proximal bronchial, thoracic cage and soft tissue outline. These structures were visible on 97.00% of the images from both conventional x-ray systems and Lodox x-ray systems. These were pulmonary vasculature and lung parenchyma. These two observations showed patterns of macro (large) and micro (tiny) tissues in the soft lung. This means that the two imaging systems had almost similar dark noise because of an almost similar range in observable structures on the image. This was confirmed by the outcome values of dark noise measured on conventional x-ray systems compared with that of the Lodox x-ray system. The average values of dark noise for conventional x-ray systems and that of the Lodox x-ray system obtained (Figure 4.4) were 3936.17 and 3883.83 respectively, which indicates an almost insignificant variation between the two systems.

To minimise the scatter radiation, the Lodox x-ray system is fitted with a detector that has a scatter-absorbing housing that eliminates the remaining scatter before scatter detection.⁸⁴ This can increase the signal-to-noise ratio on the image.⁸⁴ Additionally, the Lodox linear slot scanning technology uses only a 6 mm aperture that is lead collimated.⁸⁴ The controlled aperture minimises the amount of scatter compared to the rectangular collimated surface than conventional x-ray systems cover.^{43,84} In addition to a narrowed aperture, there is an additional post-patient rejection grid that absorbs the scatter before reaching the surface of the image receptor.⁸⁴ This wide beam on conventional x-ray systems results in increased scattered x-ray photons that increase scatter radiation causing increased noise on an image.^{43,68,84} This higher radiation exposure and the wide cone of x-rays also causes relatively high amounts of scattered radiation throughout the room. The average value of dark noise for conventional x-ray systems and that of the Lodox x-ray system was 3936.17 and 3883.83 respectively. Despite the differences in the technologies used on the two imaging systems, there was no significant difference in the level of image noise.

6.5 Discussion of Phase 2: Development and formulation of referral pathway (imaging protocol) guidelines

This section discusses the referral pathway (imaging protocol) guidelines that were developed and verified using the e-Delphi technique.

6.5.1 Introduction

A guideline is a document that has been systematically developed for a health intervention whether in the form of clinical, public or policy interventions for evidence-based decision-making.¹¹³⁻¹¹⁴ Guidelines are systematically developed standards of practice recommended by a team of experts in a particular discipline.¹¹³ Guidelines are also decision tools to close gaps between current and optional practice to assist practitioners and clients in making appropriate decisions regarding relevant health care for a given situation.^{9,147} The guidelines in the health sector aim to assist providers and recipients of health care and other stakeholders to make informed decisions to achieve significant health outcomes by reducing inappropriate practice variations.^{9,113}

For guidelines to meet public health needs, they need to be based on comprehensive and objective assessment, and the process used to develop these guidelines must be clear to see how recommendations were derived.¹¹³ Guidelines could come from many sources such as local hospitals, government organisations, health plans, patient advocacy organisations, government agencies or international organisations.^{9,91} Guideline recommendations may differ because of some variations in systems of care, the availability of technologies or resources, the process or methods used to develop them, and traditions of caregiving or cultural considerations.⁹¹ In this research, the formulation and verification of referral pathway (imaging protocol) guidelines for patients undergoing Lodox imaging were done using a consensus research method called the e-Delphi method.⁸⁵ The results of the e-Delphi method for the two objectives are discussed below.

Thirteen referral pathway (imaging protocol) guidelines were formulated and verified by the researcher based on the comments and recommendations outlined by the panel of experts in each of the e-Delphi rounds. A description of the final guidelines is presented below.

6.5.2 Name of the guidelines

Adult referral pathway (imaging protocol) guidelines for Lodox x-ray systems at trauma units in South Africa.

6.5.3 Overall aim of the guidelines

The overall aim of these guidelines is to present adult chest referral pathway (imaging protocol) guidelines for trauma patients undergoing Lodox x-ray system imaging at trauma units.

6.5.4 Scope of guidelines

The referral pathway (imaging protocol) guidelines in this study were developed for trauma specialists that refer patients for Lodox imaging. These are medical doctors and nurses working at trauma units where a Lodox x-ray system is used.

6.5.5 Purposed process of guidelines development

The research results were obtained by addressing the four proposed objectives (see 6.1).

The study was successfully executed as the research was carried out in line with the stated design and methodology.

6.5.6 Referral pathway (imaging protocol) guidelines

| | |
|--------------------|--|
| Guideline 1 | Appropriately trained medical doctors and registered trauma/emergency medical specialists (either a doctor or a nurse) may refer a patient for a full-body Lodox imaging or a regional dedicated Lodox imaging only when this decision is supported by the primary survey, rapid physical examination, and mechanism of injury of the patient |
|--------------------|--|

- **The rationale for the implementation of the guideline**

The Lodox x-ray system is radiation-emitting equipment.¹³ This means that Lodox x-ray systems may be categorised and regulated under the South African Hazardous Substances Act 1973 which controls the manufacture, sale, use application, modification, disposal or dumping of substances and (electronic) products that may hurt or kill human beings because of their detrimental direct effect or side effects.¹⁴⁸ Therefore, the request for the radiological examination has to be done by appropriately trained and registered healthcare professionals as described in a policy for requesting medical x-ray examinations.¹⁴⁹ Since the Lodox x-ray system is used at emergency trauma units, the person requesting these radiological examinations must be a registered healthcare worker and particularly acquainted with the triage of the patient and clinical indications that may lead to requesting these radiological examinations.¹⁵⁰ The clinical indication

can be derived after a primary survey, rapid physical assessment and focused physical examinations of the patient have been performed.

The primary survey involves detecting the immediate life-threatening conditions in a prioritised sequence based on the effects of the injuries on the patient’s physiology.¹⁵⁰⁻¹⁵¹ This assessment involves checking the patient’s ABCs.¹⁵² This is performed to address and correct immediate threats.¹⁵⁰ It is recommended that a primary survey be performed before referring a patient for radiological examination.

| | |
|--------------------|--|
| Guideline 2 | <p>In case a patient is hemodynamically unstable, the intervention will be a priority to the imaging . Transfer the patient directly to the operating room without any imaging studies.</p> <p>Unstable signs namely: Heart (pulse) rate <60 or >120, a respiration rate of <10 or >30 breaths per minute, blood pressure (systole <90) and Glasgow Coma Scale (GCS) of <12 in adult patients support the referral for full-body Lodox imaging. <i>This is if the patient does not need direct operative intervention.</i></p> |
|--------------------|--|

- **The rationale for the implementation of the guideline**

Vital signs serve as non-invasive evidence of the patient’s condition as well as an indication of the patients’ physiologic response to therapy or intervention.⁸³ Vital signs include systolic blood pressure (SBP, mmHg), diastolic blood pressure (DBP, mmHg), temperature (°C), pulse rate (beats per minute), respiratory rate (breaths per minute), and the Glasgow Coma Scale (GCS).¹⁵³ Vital signs are not discrete indicators for a Lodox scanning. The normal range for the adult vital signs is heart (pulse) rate (60–100 beats per minute), respiration rate 12 to 20 breaths per minute), blood pressure (systole and diastole) less than 120/80 mm Hg and Glasgow Coma Scale of 15.¹⁵⁴ Degradation of physiological function may not necessarily be attributed to trauma. Other conditions contribute to abnormal vital signs. The taking of vital signs is performed just after a primary survey. In cases where the patient is identified as hemodynamically unstable and has extensive blood loss, the imaging will not be a priority, the patient will undergo an intervention prior to imaging. The intervention can be done while patient is still on the Lodox imaging bed. Lodox imaging will be justified by rapid physical examination and the mechanism of injury. Referral for a radiological investigation may be done after stabilising the patient by arresting the immediate cause of death.¹⁵⁰

| | |
|--------------------|---|
| Guideline 3 | Upon triage of a patient, P1 and P2 are highly likely to undergo Lodox imaging. P3 and P4 are less likely to undergo Lodox imaging unless justified by a focused physical examination. |
|--------------------|---|

- **The rationale for the implementation of the guideline**

Triage is the method used in sorting patients in order of priority with the critically ill getting the highest priority¹⁵⁴. This is performed in situations where the number and severity of casualties exceed the medical capacity of a hospital.¹⁵⁴ Therefore, patients are attended to in order of clinical need rather than the order in which they reported. In South, the triage score is based on vital data and discriminators. This is where patients are coded between 1 and 4 based on the clinical need where code 1 (P1) is labelled with a colour red meaning immediate attention, P2 is coded yellow meaning urgent attention, P3 is labelled green and means a stable patient and P4 is labelled blue meaning completely stable or deceased, meaning there is no need for urgent attention.¹⁵⁴ Upon triage, P3 and P4 trauma patients may undergo regional dedicated imaging of the injured part using conventional x-ray systems or a Lodox x-ray system. The decision must be supported by a focused physical examination. The request for the Lodox x-ray images is similar to that requested for a conventional x-ray. The patient can only be referred for full-body Lodox imaging or dedicated regional radiological examination after stabilisation of the ABCs of a patient.¹⁵⁰⁻¹⁵¹

A radiological investigation for regional dedicated images (examination) like chest, cervical-, thoracic- and lumbar spine, knee, pelvis, abdominal and extremities imaging may be performed using a conventional x-ray system or a Lodox x-ray system. This will limit scanning to the regions of interest which will minimise the radiation dose and medical bill for the patient.

| | |
|--------------------|---|
| Guideline 4 | Full-body Lodox imaging or regional dedicated Lodox imaging may be requested for the following clinical indication: Polytrauma patients, ballistic injury, vascular injury, limb-ablation injury (traumatic amputation), forensic indications and routine medical follow-up |
|--------------------|---|

- **The rationale for the indications listed in the guideline**

In this research, the trauma specialists suggested the following to be acceptable clinical indications for a request for Lodox imaging.

- ✓ Polytrauma patients with suspected injuries at chest, abdomen-pelvic and multiple fractures of the extremities.¹⁰ Traumatic injuries with a mechanism of injury such as motor vehicle accident (MVA), motorcycle accident (MCA), pedestrian-vehicle accident (PVA) and collapsed buildings with multiple injuries and death/s on the scene.¹⁵⁵
- ✓ Ballistic injuries: Injuries caused on a body by the impact of a projectile object. This can be an accelerated object or patient e.g., fell off a height, gunshot injury, pellets, shrapnel, arrowheads.¹⁵⁶
- ✓ Traumatic amputations of a limb, where an extremity or a section of the body has been cut off because of the accident or explosion.
- ✓ Forensic investigations: Suspected multiple non-accidental injuries with possible fractures. For example, assault, torture, custodian injuries, suicide attempt and ingested materials (drug smuggling).¹⁵⁶⁻¹⁵⁷
- ✓ Mass fatalities where conventional x-ray systems are in use or x-rays machines are not available.¹⁵⁶
- ✓ Contrast-enhanced studies, intravascular administration of contrast media for evaluation of patency and vascular pathology where a single scan will show many regions at once.
- ✓ Routine follow-up of pulmonary diseases like pulmonary tuberculosis, metastasis, screening of occupational disease and disorders.
- ✓ Routine follow-up on patency of prosthesis, e.g., breast implant, hip replacements, and knee replacements.
- ✓ Evaluation of stent, e.g., ventriculoperitoneal shunt dysfunction. Lodox would take a single image for multiple regions then a separate image would be taken using conventional x-ray systems.¹⁵⁸
- ✓ A skeletal radiological survey; for detection of focal or widespread abnormalities of the skeleton e.g., multiple myeloma, metastasis, congenital skeletal abnormalities in children, babygram on stillbirth. The Lodox x-ray system uses lo radiation dose and therefore it is appropriate for use in taking these images.¹⁵⁹

| | |
|--------------------|--|
| Guideline 5 | Request full-body Lodox imaging if the patient is suspected to have injuries in more than half of the five big regions of the body the whole body |
|--------------------|--|

- **The rationale for the implementation of the guideline**

Radiography of the chest, abdomen and pelvis are adjunct to the primary survey.¹⁵⁰ The cervical spine may not be cleared of injuries using conventional x-ray images unless CT imaging of the neck has been performed. The use of Lodox imaging of the five big regions of the body (head, spine, torso, upper extremity, and lower extremity) is significant when injuries have been identified in more than two areas of such body regions. The rule of the thumb applies: if more than two of these regions are suspected of injuries, request full-body Lodox imaging. If lateral Lodox images of the spine are required, limit scanning to the cervical spine, thoracic spine, lumbar spine and /or sacral spine only. The scanning must be performed with the arms of the patient gripped across the chest to see the lateral thoracic spine. While imaging the lateral spine of a patient using a Lodox x-ray system, lateral images of the upper or lower extremities on the same image should be avoided. These images show fewer pathological details due to the superimposition of the upper extremity with the spine and superimposition of the left and right lower extremity on the same image.

Request regional dedicated imaging procedures for the suspected pathologies after the focused physical examination. Chest-dedicated Lodox imaging is recommended if chest pathology is suspected, or clearance of a patient from the intrathoracic injuries is needed.^{150,160} Based on a clinical presentation, full-body contrast-enhanced CT imaging may be requested without performing full-body Lodox imaging or regional conventional x-ray images.¹⁶¹ Additionally, after a focused physical examination, the healthcare worker may request contrast-enhanced CT imaging of a chest or FAST chest, without performing Lodox imaging of a chest or conventional chest images. CT imaging remains the gold standard.⁵⁶ This could minimise the radiation dose to the patient.

| | |
|--------------------|--|
| Guideline 6 | Full-body Lodox imaging should not be performed on stable ambulant patients. If full-body Lodox imaging must be performed using a Lodox x-ray system, it must be supported by a clinical history (e.g., forensic investigations) and retake of images may be performed for medico-legal purposes using appropriate imaging modalities justified by optimal radiation dose. If regional images need to be performed, request regional dedicated imaging and limit scanning to the regions of interest. |
|--------------------|--|

- **The rationale for the implementation of this guideline**

The Lodox x-ray system was initially made for use in trauma units and as an adjunct screening tool as part of the primary survey.¹⁰ Although the use of this imaging system has advanced, full-body imaging on a stable patient may not be of value but results in increased radiation dose to the patient. Lodox imaging may be employed for medico-legal investigation and if supported by the clinical history, full-body imaging may be performed in support of the evidence.¹⁶² The use of Lodox imaging for medical-legal investigations like body packers, multiple injuries due to assault on an adult and a battered child has demonstrated benefits in both minimising radiation dose and reducing examination time.¹⁶²

It is therefore suggested that the Lodox x-ray system should not be used as a full-body screening tool on stable ambulant patients. If full-body imaging must be performed using a Lodox x-ray system, it must be supported by a clinical history (e.g., forensic investigations). The retake of the same images to confirm injuries may be justified by optimal radiation dose. If regional images are required, regional dedicated images only, or preferably conventional x-ray images should be obtained, and scanning limited to a specific site only.

| | |
|--------------------|--|
| Guideline 7 | In case there is no CT imaging system in the hospital, a patient may be referred for Ultrasound imaging to investigate a suspected pericardial effusion, cardiac tamponade, sternal fracture, atelectasis, pneumothorax, hemopneumothorax or effusion not evident on supine chest x-rays. |
|--------------------|--|

- **The rationale for the implementation of this guideline**

A FAST scan is a point-of-care ultrasound examination performed at the time of presentation of a trauma patient.¹⁶³ FAST is performed to identify intrathoracic free fluid to allow for an immediate transfer to theatre for intervention.¹⁶³ FAST scanning has a reported sensitivity of 90.00% (range 75–100.00%) and a specificity of 95.00% (range 88–100%) for detecting intraperitoneal free fluid. Sensitivity for detecting solid organ injuries is much lower. Moreover, mesenteric vascular injuries, solid organ injuries, hollow viscus injuries and diaphragmatic injuries may not result in free intraperitoneal fluid, and thus may not be detected. The sensitivity and specificity of thoracic ultrasonography in detecting pneumothorax outperforms the supine chest x-ray images. The sensitivity of 86.00–98.00% and specificity of 97.00%–100.00% was noted.¹⁶³ Additionally the sensitivities and specificities of ultrasound for the detection of haemothorax are 92.00% to 100.00%.¹⁶³ The FAST examination also evaluates the pericardium and three potential spaces

within the peritoneal cavity for pathologic fluid.¹⁶³ In addition to Advanced Trauma Life Support (ATLS), more than 96.00% of Level 1 trauma centres have incorporated FAST into their trauma algorithms.¹⁶³ The FAST has also been used in the evaluation of heart, pleura effusion, haemothorax pneumothorax and great blood vessels, apnoea, atelectasis, chronic obstructive pulmonary disease, bullous changes, pleural thickening, post pleurodesis, unilateral subcutaneous emphysema and main stem bronchus.¹⁶⁴

| | |
|--------------------|---|
| Guideline 8 | Chest imaging is a more urgent radiological examination than other regions of the body in the management of a polytrauma patient. CXR may be requested on a chest-dedicated Lodox x-ray system or a conventional x-ray system yielding a diagnostic image. |
|--------------------|---|

- **The rationale for the implementation of the guideline**

Although chest x-ray (CXR) is recommended for the initial evaluation of the trauma patient by the ATLS, much literature has disputed this.¹⁶⁵ There has been a suggestion of a physical examination history being taken to replace a request for a CXR.^{150,165} In other words, the request of CXR must be supported by the appropriate clinical indications ascertained by the rapid physical assessment or focused physical assessment.¹⁶⁰

It was found that there is no significant difference between diagnostic qualities of chest images performed with Lodox x-rays system and those from the conventional x-ray systems. Upon performing CXR, the mechanism of injury, primary survey and rapid and focused physical examination will inform the appropriate and subsequent imaging modalities of choice after CXR has been performed using either the Lodox or conventional x-ray system.

Trauma specialists also suggested the following as clinical indications to be referred to as indicators for requesting chest Lodox images/ conventional chest imaging.

- ✓ Any post-traumatic wounds on a chest.
- ✓ Blunt and penetrating injury.
- ✓ Any abnormal findings on cardiovascular or respiratory examination examinations.
- ✓ Chest pain, dyspnoea, tachypnoea.
- ✓ Use of accessory muscles in breathing.
- ✓ Abnormal breath sounds.

- ✓ Suspected rib fractures, haemothorax or pneumothorax.
- ✓ Paradoxical chest movement.
- ✓ Suspected aspiration.
- ✓ Blunt chest trauma, hypoxia, penetrating chest trauma.
- ✓ Clinical features of Lower respiratory tract infection.
- ✓ Suspected metastasis.
- ✓ Flail chest, swelling and tenderness.

| | |
|--------------------|---|
| Guideline 9 | Request contrast-enhanced CT imaging of the chest without performing Lodox imaging or conventional CXR imaging if the patient is suspected to have injuries of blood vessels, mediastinum, or lung parenchyma. |
|--------------------|---|

- **The rationale for the implementation of this guideline**

CXR is the first-line imaging examination performed on trauma without risking further injury.⁶⁵ CXR has limited diagnostic ability due to its two-dimensional images which can miss subtle abnormalities as well as injuries of the mediastinum.⁶¹ Therefore, scanning the patient with a Lodox x-ray system or conventional x-ray systems will not yield a comprehensive diagnosis. A CT scanner takes multiple cross-sectional images of the body and particularly shows lung and mediastinal windows more clearly than either the Lodox x-rays system or conventional x-ray system.⁶¹ CT imaging remains the gold standard in the diagnosis of internal structures of the body.¹⁶³ Helical volumetric CT imaging is recommended due to its ability to acquire finely detailed images of the tissue.¹⁶⁶ In the evaluation of suspected blood vessels abnormalities, contrast-enhanced CT Imaging is performed.¹⁶⁶ On an adult patient, an estimation of 100 to 150 mL at an injection rate of 2-4 mL/sec using an agent with 30.00% to 40.00% concentration of iodine is recommended.¹⁶⁶ Uncontrasted CT chest images yield limited details of cardiovascular imaging thus limiting diagnosis. It is, therefore, recommended that patients with suspected injuries of the chest undergo contrast-enhanced CT imaging.^{61,166}

It is, therefore, recommended that a patient be referred directly for CT imaging if a patient has the following suspected clinical conditions.

- ✓ Intrathoracic vascular injury including blunt aortic injury or arch-vessel injury.
- ✓ Fractures of bones of the thoracic cage or Flail chest.

- ✓ Pulmonary contusions / Atelectasis / lung collapse / lung parenchymal injuries.
- ✓ Suspected hemopneumothorax that might be missed on x-rays.
- ✓ Evaluation of tracheobronchial tree / Bronchopleural fistula.
- ✓ Diaphragm injuries.
- ✓ Impacted foreign body.
- ✓ Pericardial injuries / Injury of mediastinal structures.

| | |
|---------------------|---|
| Guideline 10 | <p>Request full spine Lodox imaging or regional dedicated spine imaging with a Lodox x-ray system if a patient presents these clinical indications:</p> <ul style="list-style-type: none"> ✓ The fallout of vertebral, and intervertebral disc spaces. ✓ Prevertebral tenderness or swelling. ✓ Penetrating midline back injuries. ✓ Distracting injuries of the spine. ✓ Midline and paraspinal tenderness and swelling. ✓ Deformity Bogginess Splaying Sensory function fallout. ✓ Loss of motor function. ✓ Spinal tenderness and associated neurological shock. ✓ Spinal swelling with a limited range of movement. |
|---------------------|---|

- **The rationale for the implementation of the guideline**

The main aim of spinal imaging is to avoid preventable neurological deterioration and to aid short- and long-term management of spinal injury.¹⁶¹ In some countries and hospitals, the cervical spine forms part of the radiological primary survey where the cervical spine, chest and pelvis x-ray are performed to clear a patient from the injury. Cervical spine radiographs are not indicated in patients who are awake, alert, sober, neurologically normal, have no neck pain or midline tenderness, can voluntarily move their neck from side to side, and flex and extend without pain.¹⁵⁰ Radiography of the spine is the first screening examination that precedes a physical examination.¹⁵⁰ In cases where an injury of the spine is suspected but is not shown on a radiograph, CT imaging is recommended.^{150,161} CT imaging provides detailed images in multi-planar reconstructions (MPR) and three-dimensional volume images.¹⁵⁰ Magnetic resonance imaging (MRI) is recommended for its sensitivity for soft tissue and neurological injury.^{150,161} Plain radiographs of the spine are the primary diagnostic option before referral of a patient to ancillary imaging modalities like CT and MRI.¹⁶¹ Whereas the conventional x-ray system takes regional

images separately, the Lodox x-ray system scans full spine images with a single scan.¹⁶⁷ The visualisation of lateral images of the atlantoaxial junction, cervical thoracic junction, and thoracolumbar junction, as well as lumbar-sacral joint, is crucial in the diagnosis.^{47,136,150} The visualisation of lateral cervical thoracic (Cervical number 7 and Thoracic number 1 is a challenge on conventional x-ray due to superimposition of shoulders and the spine.¹³⁶ The ability of the Lodox x-ray system to show the full spine with a single scan minimises the radiation dose caused by the radiation scatter. Unlike conventional x-rays, the quality of images produced by the Lodox increased confidence among trauma surgeons to clear patients of injuries.^{10,16} Therefore, Lodox x-ray system is suggested as imaging modality of choice for spinal evaluation. The trauma specialists suggested the following as clinical indications for the spine Lodox imaging.

- ✓ The fallout of vertebral, and intervertebral disc spaces.
- ✓ Prevertebral tenderness or swelling.
- ✓ Penetrating midline back injuries.
- ✓ Distracting injuries of the spine.
- ✓ Midline and paraspinal tenderness and swelling.
- ✓ Deformity Bogginess Splaying Sensory function fallout.
- ✓ Loss of motor function.
- ✓ Spinal tenderness and associated neurological shock.
- ✓ Spinal swelling with a limited range of movement.

| | |
|---------------------|--|
| Guideline 11 | You may request abdomino-pelvic Lodox imaging if a patient is suspected of a penetrating injury or fracture at the abdomino-pelvic region. A single image inclusive of the abdomen and pelvis will be performed |
|---------------------|--|

- **The rationale for the implementation of this guideline**

Plain x-rays have limited diagnosis on the abdomen but significant diagnosis on the pelvic images.¹⁶⁸ The pelvis plain x-ray is useful in the diagnosis of fractures of the pelvic bones while abdominal x-ray shows the gas shadows^{150,169}. The visualisation of free intraperitoneal air and trapped retroperitoneal air from duodenal perforation on plain abdominal x-rays are not informative of the site of the puncture. This creates a need for more detailed imaging (CT imaging

or FAST).¹⁶⁸ A diagnosis on chest images informs the possible injuries of the abdomen especially if the injury is affecting the diaphragm or ribcage with associated pneumothorax. An ultrasound is the common initial and useful assessment for intra-abdominal injuries.¹⁶⁸ The FAST examination has been adopted as a standard part of the diagnostic algorithm.^{54,168} It informs on intra-peritoneal and intra-pericardial injuries.⁵⁴ Plain radiography has no role in blunt trauma.⁵⁴ FAST is not able to exclude solid organ, mesenteric or retroperitoneal injury.⁵⁴

Contrast-enhanced CT imaging of the abdomen is the modality of choice in assessing hollow and solid visceral injuries, vascular injuries, spinal and bony pelvic injuries, hemoperitoneum and pneumoperitoneum and allows specific injuries to be graded.⁵⁴ Contrast extravasation found on CT images is a sign of active bleeding and may require interventional radiology services if available. It is also a strong predictor of failure of non-operative management.¹⁶⁸

Despite the limited diagnosis obtained on the abdominopelvic images of conventional x-rays, trauma specialists requested the Lodox imaging of the same region when these clinical indications are present:

- ✓ Suspected fracture of the pelvis with associated abdominal tenderness.
- ✓ Blunt or penetrating trauma injury at the abdominopelvic region.
- ✓ Unstable pelvis, haematuria, and abdominal tenderness (including doing a Lodox cystogram).
- ✓ Tenderness on the abdominal and pelvis, unexplained blood loss, bruising or swelling of abdomen and pelvis regions.
- ✓ Painful abdomen and pelvis, deformity limb length discrepancy, decreased range of movement at hips.
- ✓ Abdominal distension, vomiting, constipation, or obstipation after a trauma.

| | |
|---------------------|---|
| Guideline 12 | Imaging of the extremities may be performed using the dedicated programme of the Lodox- or conventional x-ray systems. Lodox x-ray systems can only obtain diagnostic images of extremities in the AP projection |
|---------------------|---|

- **The rationale for the implementation of the guideline**

Although extremities are not always prioritised in the trauma units, high priority injuries on the extremities may lead to excessive blood loss and such can be life-threatening.¹⁷⁰ The prioritisation of performing the extremities is necessitated by the nature of injury accompanied by the

bleeding. The structure of the Lodox x-ray system allows angulations in a limited direction, this makes it difficult to obtain lateral projections of the images of joints such as the knee joint that requires angulation of 5 to 7 degrees with the knee flexed at 20-30 degrees.⁴⁷ Additionally, lateral scanning of lower extremities creates a superimposed image of the left and right limb on a supine patient with a horizontal x-ray beam projection. It is recommended that a sound leg may be lifted off the images and supported thus capturing a single image. When upper extremity and lower extremities images are regions of interest and images of chest and abdominopelvic are to be performed, AP full-body Lodox imaging may be performed such that: .

Patients should be in the supine position, arm adducted, the elbow is extended, the palm of hand supinated and aligned with the long axis of the body. The upper extremity (arm) will produce a true. AP projection images of shoulder joint, humerus, elbow, forearm, wrist, and hand. The full length of the lower leg is inverted 5 degrees inwards. This will produce true AP images of the hip joint, femur, knee joint, tibia fibular and ankle joint.

Trauma specialists suggested these clinical indications for requesting a Lodox x-ray for a limb/extremities (lower and upper limb images).

- ✓ Tenderness and deep lacerations.
- ✓ Deep penetrating wounds.
- ✓ Abnormal movement of the limbs.
- ✓ Limb length discrepancy.
- ✓ Decreased movement of the joints.
- ✓ Crepitation with limited movement.
- ✓ Deformities of the extremities.
- ✓ Amputation of the limb.

| | |
|---------------------|--|
| Guideline 13 | You may request skull Lodox imaging if a patient presents with facial bone injuries with no associated symptoms of intracranial pathology (e.g., scalp laceration) and impacted foreign body. |
|---------------------|--|

- **The rationale for the implementation of the guideline**

A skull image has limited ability to diagnose a brain injury and therefore has no clinical benefits in the diagnosis of minor traumatic injuries.¹⁷¹ Additionally skull imaging show fractures only and does not allow visualisation of either the brain or any traces of bleeding that would show an intracranial injury.¹⁷¹ CT imaging of the brain is a reliable imaging modality that may be sensitive to intracranial and detailed facial bone injuries.¹⁷¹ In resource-constrained hospitals, Lodox imaging of the skull may be requested but should be limited to facial bones pathology.¹⁷² Trauma specialists suggested the following as the clinical indications for skull Lodox imaging.

- ✓ Facial bone injuries with no associated symptoms of intracranial pathology (e.g., scalp laceration).
- ✓ Impacted foreign body.

6.6 Referral pathway (imaging protocol) guidelines for trauma patients undergoing Lodox chest imaging

After a primary survey, a rapid physical assessment must be performed on a patient before referring the patient for Lodox imaging of the chest. A primary survey is expected to take less than 10 minutes.¹⁶⁰ Rapid physical assessment can replace a focused physical assessment when the patient is critically ill and needs to be referred for an intervention or a specialised radiological procedure. Rapid physical assessment must take 60–90 seconds of the ten minutes of the primary survey and can be performed while other healthcare personnel are focused on performing the primary survey.¹⁵¹ In this case full-body Lodox imaging is likely to be requested and chest imaging will be part of the images. Focused physical examinations must be performed on a patient before requesting chest-dedicated Lodox imaging. In cases where full-body Lodox imaging or chest-dedicated Lodox imaging has been performed, no conventional CXR will be requested. Chest images performed using the Lodox x-ray system are of diagnostic value and a repeat x-ray using a conventional x-ray system is not necessary. In cases where the diagnosis has been yielded on a Lodox image of the chest, a patient can be referred for an interventional procedure without a need for Ultrasound- or CT imaging. It is recommended that a FAST be performed after Lodox imaging of the chest has been performed. This is an example where a further investigation should be done to confirm a diagnosis. The use of Ultrasound imaging complements the findings on the Lodox images of the chest since Ultrasound can confirm rib fractures, fracture of the sternum, fracture of the clavicle, a haematoma on the chest wall, pleural effusion and lung contusion better than both the Lodox- and conventional x-ray systems.¹⁷³

In cases where a Lodox-, conventional system and CT are available, it is recommended that after undergoing Lodox imaging of the chest and intrathoracic injuries are suspected, the patient be referred for Computed Tomography Angiography (CTA) of the chest.¹⁷⁴ The use of CT imaging as an immediate modality after full-body Lodox imaging minimises the radiation dose of the patient by skipping the request for conventional CXR images. CT imaging is far more effective than chest images from a conventional- or Lodox x-ray system in detecting pulmonary contusion, thoracic aortic injury and osseous trauma, especially at the cervicothoracic spine.¹⁷⁴ In comparison to other imaging modalities, CT imaging remains the gold standard for the diagnosis of chest pathologies associated with trauma.¹⁷⁴ The researcher believes that the implementation of the suggested guidelines as well as the developed chest-imaging referral pathway/imaging protocol will guide the imaging of trauma patients, minimise the radiation dose on the patients, reduce the scatter radiation on the staff and reduce the radiological costs for the patients. There will be a reduced workload due to fewer radiological examinations performed on the patient. The referral pathway/imaging protocol will also enhance multidisciplinary collaboration in handling patients, thereby synchronising, and integrating skills towards patient care to improve healthcare services and the management of the trauma patients.²⁵⁻²⁷

CHAPTER 7: SUMMARY OF THE FINDINGS, ESTABLISHMENT OF THE PROTOCOL, RECOMMENDATIONS AND CONCLUSION

7.1 Introduction

This research aimed to develop an adult chest referral pathway/imaging protocol for trauma patients undergoing imaging with the Lodox x-ray system. This was performed by establishing the diagnostic similarity between chest images of adult trauma patients acquired using a conventional x-ray system and those acquired using the Lodox x-ray system.

To meet this aim, images of the same patient that were performed using the conventional x-ray system and those performed using the Lodox x-ray system were retrieved and investigated. These images were rated by radiologists based on criteria established on a checklist (see Annexure B). The variables on Annexure B were scored for images obtained from the conventional x-ray system and those from the Lodox x-ray system.

Firstly, diagnostic similarities of the images obtained from the conventional x-ray system and those from the Lodox x-ray system were established. Secondly, the diagnostic quality of the images obtained from the conventional x-ray system and those from the Lodox x-ray system obtained on a walk-in patient were also rated. The outcomes for comparison of diagnostic similarities and quality of images were presented to a team of experts who participated in the development of guidelines and a protocol.

7.2 Summary of the findings

It was shown that the Lodox x-ray system showed the following structures better than the conventional x-ray system: pulmonary vasculature, lung parenchyma, thoracic cage and soft tissues, trachea and proximal bronchi, pulmonary vessels cardiac outline, aorta outline, retro-cardiac and mediastinal outline, thoracic spine, vertebral bodies, and vertebral disc spaces. The following pathological conditions were clearer on the Lodox x-ray system than the conventional x-ray system images, lung infiltrates, surgical emphysema, nodules, interstitial changes, air bronchograms, fractures of ribs, fractures of clavicles and diaphragms. Both conventional x-ray system images and Lodox x-ray system images showed breast tissue outline equally. The conventional x-ray system showed these structures better than the Lodox x-ray system: pneumothorax, effusions, and extra-luminal air. Overall, the Lodox x-ray system seems to show most of the structures better than the conventional x-ray system. To confirm this, the researcher decided to perform additional CXR images using the Lodox x-ray system on patients that had been referred for CXR on a conventional x-ray system.

These findings were then confirmed on a patient (walk-in patient) that was conscious and able to respond to radiological instructions during the imaging procedure. During chest imaging, a patient is expected to be in an erect position, be able to breathe in deeply and hold their breath to attain the maximum capacity of the lungs. This technique shows the full surface of the lung, which assist in detecting diseases. As the images used earlier were obtained from x-rays on a trauma patient who may have been unconscious, an image performed on a walk-in patient must have met the criteria suggested for chest imaging. These considerations enabled the evaluation of image quality of an adult chest acquired using the chest-dedicated imaging programme of a Lodox x-ray system, compared to those acquired using conventional x-ray systems concerning the level of distortion, resolution, contrast, and image noise. It was further found that both the conventional and Lodox x-ray systems had equal beam penetration and showed the following features equally: pulmonary vasculature, lung infiltrate, thoracic cage soft tissue outlines, trachea and proximal bronchi, pulmonary vessels, thoracic spine vertebral bodies, disc spaces, pneumothorax, surgical emphysema, extra-luminal air, and air bronchograms.

Conventional x-ray system images showed the following features better than the Lodox x-ray system: pulmonary effusion, extra-luminal air, and pneumothorax while the Lodox x-ray system showed these features with superior qualities for lung parenchyma, retro-cardiac and mediastinal outline, effusions, nodules, interstitial changes, and thoracic spine fracture. It was also found that the conventional x-ray system and the Lodox x-ray system had similar contrast resolution, image noise and spatial resolution. The geometric distortion (also called scaling error) was higher in the conventional x-ray system than it was on Lodox x-ray system images. Increased geometric distortion was a setback for the conventional x-ray system because the image details are exaggerated. These findings were presented to the experts (trauma specialists, medical doctors, and trauma specialist nurses) who were participants in the e-Delphi method of the research. These experts used the results on image similarity and image quality to develop an imaging protocol for the Lodox x-ray system.

7.3 Establishment of referral pathway (imaging protocol) guidelines Lodox imaging

Clinical guidelines for patients undergoing full-body Lodox imaging and the referral pathway (imaging protocol) guidelines for adult patients undergoing full-body Lodox imaging were established in this research. Figures 7.1 and 7.2 represent a referral pathway (imaging protocol) for an adult patient undergoing full-body Lodox imaging and for adult patients undergoing chest imaging using a Lodox x-ray system respectively.

FULL-BODY LODOX IMAGING PROTOCOL FOR ADULT PATIENTS UNDERGOING LODOX IMAGING

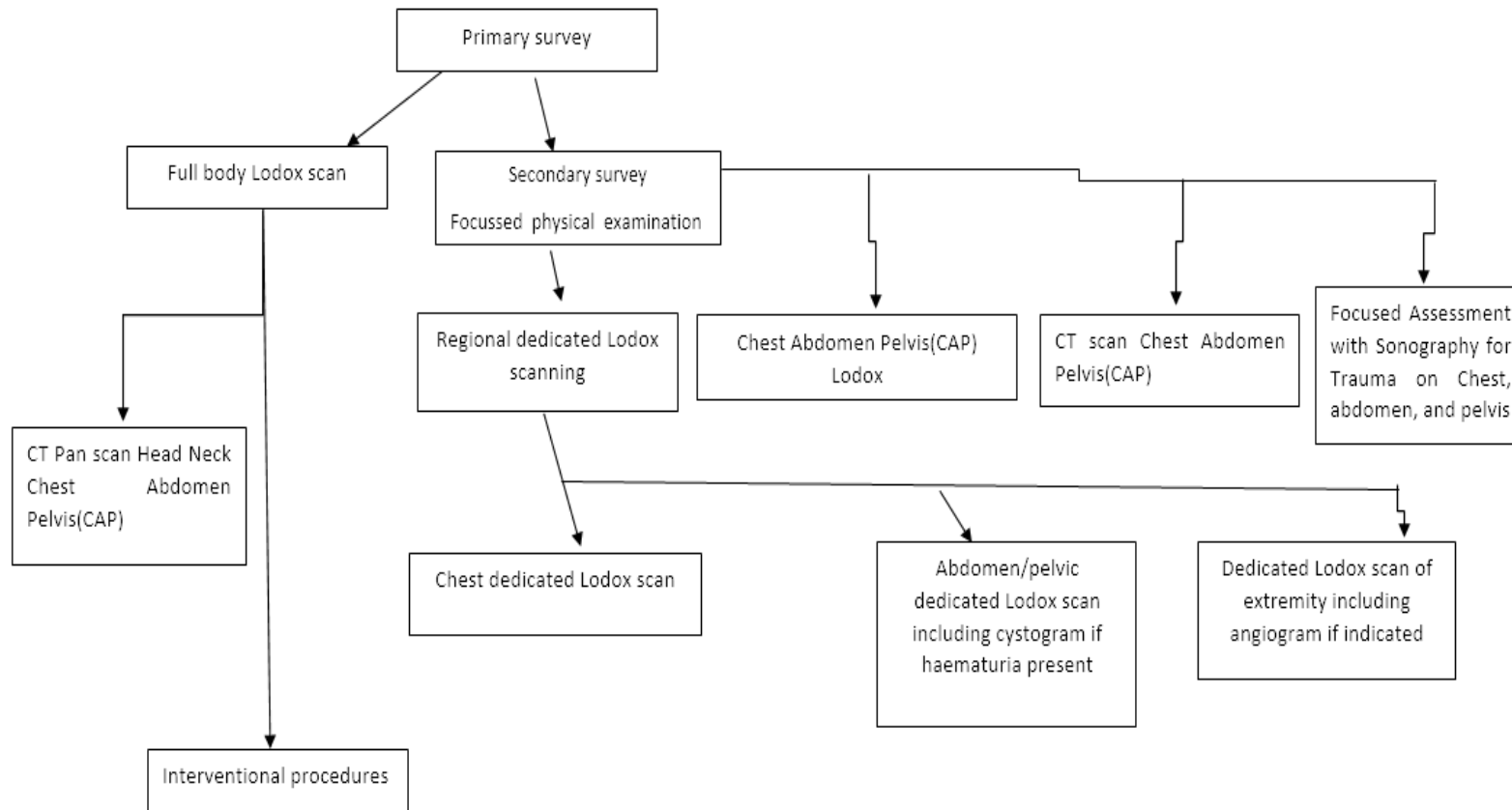


Figure 7.1: Referral pathway (imaging protocol) for adult patients undergoing full-body Lodox imaging

Table 7.1: Clinical indications and suggested imaging modalities for trauma patients

| CLINICAL INDICATION | SUGGESTED IMAGING MODALITY |
|---|---|
| Suspected injuries of facial bones, spine, chest abdomen, pelvis, and extremities | Full-body imaging (AP and Lateral) |
| Suspected injuries of brain tissue, spine, blunt aortic injury, blunt cardiac injury, intrathoracic vascular injury, lung contusion, flail chest, impacted foreign body, blunt trauma or deep laceration of chest or abdomen injuries, pelvis, and extremities injuries | Full-body imaging with the patient in anatomical position, feet inverted 10–15 degrees, elbow extended and palm facing forward |
| Suspected injuries of chest abdomen and pelvis only | Perform chest abdomen and pelvis Lodox imaging |
| Suspected injuries of abdomen organ or intra-abdominal haemorrhage (right upper quadrant (RUQ), left upper quadrant (LUQ), and pelvic windows), hemopericardium (subxiphoid window), and pneumothorax and haemothorax (thoracic and pleural ultrasound) | FAST (Ultrasound) after chest, abdomen, and pelvis (CAP) Lodox imaging |
| Suspected injuries of the chest (in absence of CT imaging in the hospital) | Perform chest-dedicated Lodox imaging and FAST (Ultrasound) Contrast-enhanced CT imaging of the chest is recommended for a comprehensive diagnosis of the chest and injuries involving blood vessels and the mediastinum |
| Suspected injuries of Pelvis, with suspected uroperitoneum | Perform AP pelvic imaging with the Lodox x-ray system. CT cystography or retrograde cystography may be performed on the Lodox x-ray system bed to rule out suspected uroperitoneum |
| Suspected chest injuries | Perform chest-dedicated Lodox imaging then refer for FAST to evaluate pneumothorax |
| Suspected chest injuries associated with intrathoracic thoracic organs | Refer the patient for contrast-enhanced CT imaging of the chest |
| Chest injury with associated pneumothorax, | Perform a FAST (conventional and Lodox x-ray systems are not good at showing this on a supine CXR) |
| Suspected multiple fractures of the lower extremities | Perform AP imaging of both extremities with internal rotation of the lower leg between 15 and 20 degrees. Dedicated imaging can be performed on sites of injury (ROI) |

CHEST IMAGING PROTOCOL FOR ADULT PATIENTS UNDERGOING LODOX IMAGING

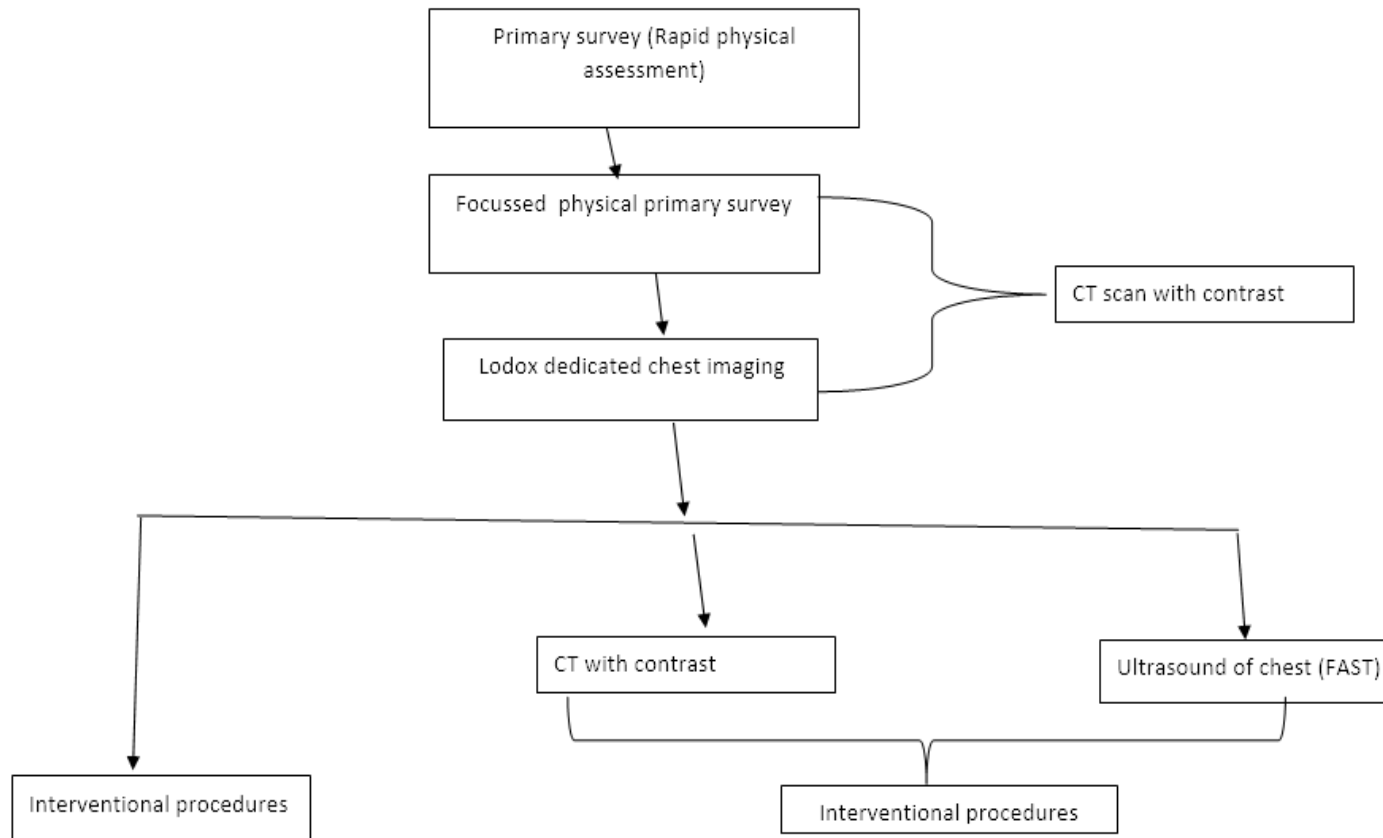


Figure 7.2: Referral pathway (imaging protocol) for an adult patient undergoing chest imaging using Lodox imaging

7.4 Referral pathway (imaging protocol) for adult chest imaging with the Lodox x-ray system

After a primary survey has been performed, a rapid physical assessment must be performed on a patient before a decision to refer the patient for chest Lodox imaging. A primary survey is expected to take less than 10 minutes.¹⁵⁵ Rapid physical assessment can replace a focused physical assessment when the patient is critically ill and needs to be referred for an intervention or a specialised radiological procedure. A rapid physical assessment should take 60–90 seconds of the ten minutes of the primary survey and can be performed while other healthcare personnel are focused on conducting the primary survey.¹⁵¹ In this case, full-body Lodox imaging is likely to be requested and chest images will be part of the images. A patient must be supine, and in an anatomical position, feet inverted 10–15 degrees, elbow extended and palms facing forward. The mid-sagittal plane of the patient must be perpendicular to the image receptor and the coronal plane must be parallel to the image receptor. Focused physical examinations must be performed on a patient prior to requesting chest-dedicated Lodox imaging. In cases where full-body Lodox imaging or chest-dedicated Lodox imaging has been performed, no conventional CXR needs to be requested. Chest images performed using the Lodox x-ray system are of diagnostic value and repeat imaging using a conventional x-ray system is not necessary. In cases where a diagnosis has been yielded on Lodox images of the chest, a patient can be referred for an interventional procedure without the need for Ultrasound or CT imaging. It is recommended that a Focused Assessment Ultrasound in Trauma (FAST) be performed after Lodox imaging of the chest has been performed. This is another example of where a further investigation can confirm a diagnosis. The use of Ultrasound imaging complements the findings on the Lodox images of the chest in that Ultrasound imaging can confirm rib fractures, a fracture of the sternum, a fracture of the clavicle, and haematoma on the chest wall, pleural effusion and lung contusion better than either the Lodox x-ray system or a conventional x-ray system.¹⁷³ Because of the orientation of the patient during Lodox- and conventional imaging, pleural effusion is visualised better on Ultrasound images than on images acquired by either a Lodox- or conventional x-ray system.¹⁷³ Additionally, Ultrasound imaging is better at showing rib fractures when compared to imaging with either a conventional- or the Lodox x-ray system.¹⁷³

In cases where Lodox imaging, conventional imaging and CT imaging are available, it is recommended that after undergoing Lodox imaging of the chest which indicate the presence of intrathoracic injuries, the patient can be referred for a CTA (CT Angiography) of the chest. The use of a multi-detector CT machine provides high-quality multiplanar and volumetric reformatted CT images which have great sensitivity for injuries of the chest.¹⁷⁴ The use of CT imaging as an immediate modality after full-body Lodox imaging minimises the radiation dose to the patient by

skipping the request for conventional CXR imaging. CT imaging is far more effective than chest imaging with either a conventional- Lodox x-ray system in detecting pulmonary contusion, thoracic aortic injury and osseous trauma, especially at the cervicothoracic spine.¹⁷⁴ Six to seven minutes (6-7 minutes) delayed post-CTA imaging of the chest would show retained contrast medium in perforated anatomy or ruptured organs.¹⁷⁴ In comparison to other imaging modalities, CT imaging remains the gold standard for the diagnosis of chest pathologies associated with trauma.¹⁷⁴

7.5 Recommendations

Recommendations have been categorised into three sections: service delivery, research and trauma education and training.

a) Service delivery

- Improved patient care. The established protocol will minimise time spent in performing a duplicate radiological investigation. This will shorten the time taken to decide on the type and availability of interventional or therapeutic procedures. This will shorten the waiting periods for a patient and improve the recovery rate for conditions that require specialised skills and equipment.
- Trauma specialists will consider referral of patients for Lodox imaging only or for conventional x-ray systems and not both, in cases where the predicted disease/prognosis is similar. Results obtained from Lodox imaging are good enough to be used for both diagnostic and screening.
- That trauma specialist considers justification and optimisation of ionising radiation on medical radiation exposure, radiation exposure to the public and occupation radiation before patient referral for a radiological procedure. The referral of a patient needs to be motivated by an appropriate primary survey, vital signs, and mechanism of injury of the patient with an adequate clinical history that justifies the intended radiological procedure to avoid investigations that are unlikely to affect patient management. In addition to a section on clinical history on a radiological request form, the researcher suggests the incorporation of a section for a predicted disease/ prognosis with a question “*What would you like to see on the image?*” on a request form. This will prompt the justification of the procedures.

b) Research

- Research on the positioning of the patient to obtain an effective full-body image is recommended. This will minimise ionising radiation, reduce radiology billing on costs of patients' examinations, and reduce patients' waiting time before management time for patient condition.

There is a need for research to show the effective positioning of the lower extremities and upper extremities to rule out pathologies of the shoulder, elbow, wrists, hip, knee, and ankle joints. Currently, Lodox imaging can only obtain AP images of these joints.

- Research is recommended to define the composition of an emergency care team, triage, scope of practice, prehospital management of a patient's condition and a primary survey to avoid duplication of activities in hospital patient management. The improved patient handover to the trauma/resuscitation team will improve the patient throughput due to minimised duplication of the duties already performed at the prehospital stage.
- Research is recommended to establish the use of the Lodox x-ray system in other countries to correlate these findings with the one obtained in the feasibility study of this research.

c) Education and training

- Training of trauma personnel on the referral of patients to various imaging modalities to avoid over the investigation. This will avoid the procedures that do not add value to the patient because similar investigations have already been performed (over-servicing). Ongoing training is needed to update trauma specialists, radiographers, and radiologists on advancements in the use of the Lodox x-ray system in trauma centres that use Lodox imaging.
- There is a need to establish a positioning booklet that will guide the various trauma personnel on requesting the diagnostic imaging projections as well as radiographers in imaging a trauma patient.
- Incorporation of the Lodox imaging contents in the radiography and radiology curriculum is recommended. The incorporation of the Linear Slot Scanning Radiography (LSSR) technology, fan-beam technology, positioning, and pathology related to Lodox imaging is recommended. This will create an improved foundation for current and future research on the advancement of conventional x-ray systems and the Lodox x-ray system.

7.6 Implications of this research

- The improved multidisciplinary approach to patient care. The guidelines for patient referrals will improve the understanding of the sequence of the interventional- and diagnostic procedures on the trauma patients undergoing Lodox imaging. This improves the understanding of the various roles and when various skills will be required in the management of the patient. The clinical information on the diagnostic efficacy of the Lodox images has provided an improved referral pathway for trauma patients. Reduced over-servicing and duplication of imaging procedures will minimise strain on the use of hospital resources.
- Cost-effectiveness. The guidelines will be effective in improving efficiency and optimising value for money. Patients will not have to pay for procedures that will not affect the management of their conditions. There will be less duplication of images produced by the Lodox x-ray system than images taken when using conventional x-ray systems.
- Improve the consistency of care. The patient guidelines developed will regulate deviations and inconsistencies in the management of the patient. Patients with identical clinical conditions and prognoses will undergo similar procedures. This may be used as a term of reference when improving the established protocol or for research purposes.
- Improved clinical decisions. The established protocol will guide clinicians on what to do when by offering recommendations on options available which will aid in the management of the patients. The guideline will offer a critically appraised option by informing healthcare workers on how it could assist with the diagnosis of various medical conditions.

7.7 Limitations of this research

- This research was limited to public hospitals. The use of the Lodox x-ray system in private hospitals was not researched. Only one private hospital in South Africa uses the Lodox x-ray system for imaging trauma patients. Therefore, results from this research can only be generalised to public hospitals although the application is recommended for use in both private- and public hospitals.
- This research was limited to South African trauma units only. Although there are no structural and functional variations on the Lodox x-ray system, research on the use of the Lodox x-ray system in other countries would add greater value to this research.

- The protocol developed in this research has not been applied and tested in any clinical setting. Therefore, it cannot be firmly concluded that the referral pathway (imaging protocol) guidelines would achieve their intended purpose. This will be proven after the protocol has been used in clinical settings over a given period.
- The participants and data collection of this research was limited to South Africa. South Africa has 28 of the 45 Lodox x-ray systems installed across the world. Therefore, this was a suitable data collection site among other countries. Although the researcher would be interested in engaging the other countries in this research, the process could be lengthy and expensive. Therefore, the outcome of this research can only be applied in South Africa.
- Most Lodox x-ray systems were not connected to a PACS system and some of the patient information details were not captured with their correct names, which made the retrieval of images, identifying and matching of images performed within 24 hours difficult for the researcher. This made the data collection period longer than planned.

Data collection was performed in five hospitals in South Africa. Due to financial constraints, data could not be collected from all the clinical sites that use the Lodox x-ray system.

- On the methodology, the researcher opted to use the e-Delphi method of data collection in Phase 2 Objective 1 and Objective 2. A Nominal Group Technique would not work because there was not enough time during the conference held in Cape Town on 21–22 November 2021. The pandemic disrupted the live meetings in the year 2020 and year 2021. Therefore, the ideal method remained the e-Delphi method.

7.8 Contribution to the body of knowledge

- This research has provided an evidence-based protocol for use on adult patients that are undergoing Lodox imaging. The confirmation that there is no significant difference in chest images obtained from conventional x-ray- and Lodox x-ray systems is a milestone towards minimisation of irradiation caused by repeated radiological examinations.
- The results from this study can be generalised to other regions of the body because of all densities being available on chest images. There was a representation of air, fluid, bones muscles and tendons on the chest images. These patterns are also evident in other regions of the body.

Methodology contributions. The previous research compared chest images from the Lodox x-ray system with those from the conventional x-ray systems but from a different patient.

Images obtained from the Lodox x-ray system were also compared with those from CT imaging, to determine the similarity between Lodox and conventional images¹⁸. This research retrospectively compared images obtained from the same patients within 24 hours to minimise the pathological differences. This provided a platform to compare images from the two imaging systems as if they were taken simultaneously to minimise radiation dose on the patient and to visualise pathologies with similar clinical presentations at a similar stage.

No previous research was found that investigated the factors affecting the image quality of a chest image. The researcher measured factors affecting image quality; size distortion, spatial resolution, contrast resolution and dark noise on the conventional x-ray systems and the Lodox x-ray system. The values of these factors were linked to the quality of the images obtained. The values obtained from the Lodox x-ray system were linked to the images obtained from the same system. This was also done on the conventional x-ray systems.

- Point-of-care. The Lodox x-ray system has proven to be a useful diagnostic tool in point-of-care testing. Point-of-care is a medical diagnosis or treatment at the time and place of care to the patient.¹⁷⁵ It is also an investigation performed on a patient at the time of consultation with instant availability of results in making immediate and informed decisions about the patient care. In trauma units, this means the investigations that are performed right at the patient site at the emergency unit for immediate diagnosis and intervention. This research has found that there is no significant difference in the quality of images obtained from the conventional x-ray systems and the Lodox x-ray system. The diagnostic quality is similar and therefore the images obtained from the Lodox x-ray system can be used to decide on the patient's condition. The use of the Lodox x-ray system at the trauma units as a screening and radiological diagnostic tool has created the level of point-of-care service expected in a global context.¹⁷⁶ The Lodox x-ray system has also provided shortened time for radiological examinations while providing diagnostic images. The minimised ionising radiation dose on the patient and the staff has increased radiation safety, hence reducing stochastic and deterministic effects of ionising radiation. The point-of-care is expected to provide a quick diagnosis and reliable and accurate results.¹⁷⁵ The use of the Lodox x-ray system can provide an early diagnosis while the patient is still at the emergency unit, early disease management of the patient condition and minimised radiation dose. In addition, single imaging has replaced multiple regional images that used to be performed. Using the Lodox x-ray system has shortened the time to diagnose a disease and has led to timeous clinical decisions and interventional procedures, hence speeding up patient recovery time.

7.9 Conclusion

This research was aimed at developing an adult chest imaging protocol for trauma patients undergoing imaging using the Lodox x-ray system.

Considering the first objective, the researcher assessed the diagnostic similarity between chest images of adult trauma patients acquired using a conventional x-ray system and those acquired using the full-body Statscan programme of the Lodox x-ray system. It was found that the Lodox x-ray system produced images of superior quality to the conventional x-ray systems in showing pulmonary vasculature, lung parenchyma, lung infiltrates, surgical emphysema, thoracic cage and soft tissue outline, thoracic spine, vertebral bodies intervertebral discs, trachea, proximal bronchi, nodulations, pulmonary vessels at the periphery of the lung, cardiac and aorta outline, air bronchograms, interstitial changes, fractures of ribs, fractures of clavicles and diaphragms. On the other hand, conventional x-ray systems were better than the Lodox x-ray system in showing pulmonary effusion, extra-luminal air and pneumothorax.

The second objective was to compare the diagnostic quality of adult chest images acquired using a Lodox chest-dedicated imaging programme and a conventional x-ray system, concerning the level of distortion, resolution, contrast, and image noise. It was found that conventional x-ray systems and Lodox x-ray systems were similar in the visualisation of the pulmonary vasculature, lungs parenchyma, lung infiltrates, thoracic cage, soft tissue outlines, trachea and proximal bronchi, peripheral pulmonary vessels, retro-cardiac space, mediastinal space, thoracic spine, vertebral bodies and vertebral disc spaces, lung contusion, pneumothorax, effusions, pneumomediastinum, surgical emphysema, extra-luminal air, nodules, air bronchograms, granular glass opacity, bullae, mediastinal injuries, fractured ribs, clavicle, thoracic spine fracture, vertebral body or spinous fracture, thoracic spine lesions and diaphragms.

On the other hand, Lodox x-ray systems were noted to be superior to conventional x-ray systems in showing pulmonary vasculature, lung parenchyma, lung infiltrates, surgical emphysema, thoracic cage and soft tissue outline, thoracic spine, vertebral bodies, vertebral discs, trachea and proximal bronchi, nodulations, pulmonary vessels at the periphery of the lung, cardiac and aorta outline, air bronchograms, interstitial changes, fractures of ribs and clavicles and diaphragms. On the other hand, conventional x-ray systems were better than Lodox x-ray systems in showing pulmonary effusion, extra-luminal air, and pneumothorax. This outcome addresses the recommendation by Whiley (2012) that there is a need for extensive research to show the efficiency of the Lodox x-ray system in the production of quality images.

Although the Lodox x-ray system had a lower level of distortion/scaling error (geometric distortion) when compared to a conventional x-ray system, there were no significant differences between the two imaging systems for contrast resolution, spatial resolution, and dark noise (image noise). The low scaling error on the image superiority could indicate a preference for using a Lodox x-ray system rather than a conventional x-ray system.

For the formulation and verification of guidelines for referring adult patients undergoing chest imaging using the Lodox x-ray system, the e-Delphi method was used.⁸⁶ The following is the referral pathway (imaging protocol) guidelines that were developed for use on patients undergoing Lodox imaging⁹;

- Appropriately trained medical doctors and registered trauma/emergency medical specialists (either a doctor or a nurse) may refer a patient for a full-body Lodox imaging or a regional dedicated Lodox imaging only when this decision is supported by the primary survey, rapid physical examination, and mechanism of injury of the patient.
- Unstable signs namely: Heart (pulse) rate <60 or >120, a respiration rate of <10 or >30 breaths per minute, blood pressure (systole <90) and Glasgow Coma Scale (GCS) of <12 in adult patients support the referral for full-body imaging. *This is if the patient does not need direct operative intervention.*
- Upon triage of a patient, P1 and P2 are highly likely to undergo Lodox imaging. P3 and P4 are less likely to undergo a Lodox imaging unless justified by a focused physical examination.
- A full-body Lodox or a regional dedicated Lodox imaging may be requested for the following clinical indication. Polytrauma patients, ballistic injury, vascular injury, limb-ablation injury (traumatic amputation), forensic indications and routine medical follow-up.
- Request full-body Lodox imaging if the patient is suspected to have injuries in more than half of the five big regions of the body the whole body.
- Full-body imaging should not be performed on stable ambulant patients. If full-body Lodox imaging must be performed, it must be supported by a clinical history (e.g., forensic investigations) and retake of images may be performed for medico-legal purposes using appropriate imaging modalities justified by optimal radiation dose. If regional images need to be performed, request regional dedicated imaging and limit imaging to the regions of interest.
- In case there is no CT imaging system in the hospital, a patient may be referred for Ultrasound imaging to investigate a suspected pericardial effusion, cardiac tamponade,

sternal fracture, atelectasis, pneumothorax, hemopneumothorax or effusion not evident on supine chest x-rays.

- Chest imaging is a more urgent radiological examination than other regions of the body in the management of a polytrauma patient. CXR may be requested on a chest-dedicated Lodox x-ray system or a conventional x-ray system yielding a diagnostic image.
- Request contrast-enhanced CT imaging of a chest without performing Lodox imaging or conventional imaging if the patient is suspected to have injuries of the blood vessels, mediastinum, or lung parenchyma.
- Request full spine Lodox imaging or regional dedicated spine imaging on a Lodox x-ray system if a patient presents appropriate clinical indications to justify the request.
- You may request an abdominopelvic Lodox image if a penetrating injury or fracture is suspected in the abdominopelvic region. A single image inclusive of the abdomen and pelvis should be performed.
- Imaging of the extremities may be performed using the dedicated programme of the Lodox or conventional x-ray system. The Lodox x-ray system can only obtain images in the AP position for the extremities.
- You may request skull Lodox images if a patient presents with facial bone injuries with no associated symptoms of intracranial pathology (e.g., scalp laceration), and for an impacted foreign body.

It can be concluded that the objectives of this study were achieved based on the findings of this research. The findings for the first and second objectives guided the development and validation of referral pathway (imaging protocol) guidelines for Lodox imaging. This study recommends the use of images performed with the Lodox x-ray system without necessarily performing secondary imaging using a conventional x-ray system. Lodox imaging systems are very useful in resource strained hospitals where there is no CT imaging available. The use of the developed referral pathway (imaging protocol) guidelines will ensure an interdisciplinary approach to healthcare, cost-effectiveness, improved clinical decision making and improved consistency in the delivery of healthcare.

REFERENCES

1. Evangelopoulos DS, Deyle S, Zimmermann H, Exadaktylos AK. Personal experience with whole-body, low-dosage, digital X-ray scanning (LODOX-Statscan) in trauma. *Scandinavian journal of trauma, resuscitation and emergency medicine*. 2009 Dec;17(1):1-5.
2. Bushong SC. *Radiologic science for technologists: Physics, biology, and protection*. 11th ed. St. Louis, Missouri: Elsevier; 2017.
3. Boffard KD. Secretary-general, international society of surgery (iss-sic) and president trauma society south. 2018.
4. IAEA. *Diagnostic radiology physics: A handbook for teachers and students*. 2014.
5. Bontrager KL, Lampignano JP. *Bontrager's handbook of radiographic positioning and techniques*. 7th ed. St. Louis, Mo. :: Mosby/Elsevier; 2010.
6. Oxford: Clarendon Press. Retrieved March. 1989. *Oxford English dictionary online*; p. 2008.
7. Farooq S. Clinical protocols: Introduction to a useful strategy in clinical practice. *JPMA. The Journal of the Pakistan Medical Association*. 2000; 50(10):354-7.
8. Hewitt-Taylor J. *Clinical guidelines and care protocols*: John Wiley & Sons; 2006.
9. Lethaby A, Wells S, Furness S, Strid J, Arroll B, Milne R. *Handbook for the preparation of explicit evidence-based clinical practice guidelines*. Auckland, New Zealand: New Zealand Guidelines Group, Effective Practice Institute of the University of Auckland. 2001.
10. Boffard KD, Goosen J, Planı F, Degiannis E, Potgieter H. The use of low dosage x-ray (Iodox/Statscan) in major trauma: Comparison between low dose x-ray and conventional x-ray techniques. *Journal of Trauma and Acute Care Surgery*. 2006; 60(6):1175-83.
11. Forrest CB, Nutting PA, Von Schrader S, Rohde C, Starfield B. Primary care physician speciality referral decision making: patient, physician, and health care system determinants. *Medical decision making*. 2006; 26(1):76-85.
12. Amirlak B, Zakhary B, Weichman K, Ahluwalia H, Forse AR, Gaines RD. Novel use of Iodox Statscan in a level one trauma center. *Ulus Travma Acil Cerrahi Derg*. 2009; 15(6):521-8.
13. Evangelopoulos DS, Deyle S, Zimmermann H, Exadaktylos AK. Full-body radiography (Iodox Statscan) in trauma and emergency medicine: A report from the first European installation site. *Trauma*. 2011; 13(1):5-15.
14. Evangelopoulos DS, Deyle S, Zimmermann H, Exadaktylos AK. Personal experience with whole-body, low-dosage, digital x-ray scanning (Iodox-Statscan) in trauma. *Scandinavian journal of trauma, resuscitation and emergency medicine*. 2009; 17(1):41.
15. Irving B, Maree G, Hering E, Douglas T. Radiation dose from a linear slit scanning x-ray machine with full-body imaging capabilities. *Radiation protection dosimetry*. 2008; 130(4):482-9.
16. Deyle S, Wagner A, Benneker LM, Jeger V, Eggi S, Bonel HM, et al. Could full-body digital x-ray (Iodox-Statscan) screening in trauma challenge conventional radiography? *Journal of Trauma and Acute Care Surgery*. 2009; 66(2):418-22.
17. Markgraaff Christian George DJJ. *Magnification error correction in Statscan images*: University of Cape Town.; 2003.
18. Ireland Horizon Scanning Network. *Horizon scanning technology prioritizing summary. Statscan critical imaging system*. In: Ageing Doha, editor. Canberra Australia: Commonwealth of Australia 2010; 2010.
19. World Health Organization. *Communicating radiation risks in paediatric imaging: Information to support health care discussions about benefit and risk*. 2016.
20. Bortz J. *Chest diseases: Applied pathology for radiographers*. *South African Radiographer*. 2007; 45(1):13.
21. Douglas TS, Sanders V, Pitcher R, van As AB. Early detection of fractures with low-dose digital x-ray images in a pediatric trauma unit. *Journal of Trauma and Acute Care Surgery*. 2008; 65(1):E4-E7.

22. Hall JE. Guyton and hall textbook of medical physiology e-book: Elsevier Health Sciences; 2015.
23. Bushong SC. Radiologic science for technologists-e-book: Physics, biology, and protection: Elsevier Health Sciences; 2013.
24. Robin ED, Burke CM. Routine chest x-ray examinations. *Chest*. 1986; 90(2):258-62.
25. Radiology ESo. Summary of the proceedings of the international forum 2016: "Imaging referral guidelines and clinical decision support-how can radiologists implement imaging referral guidelines in clinical routine?". *Insights into imaging*. 2017; 8(1):1-9.
26. Alizo G, Sciarretta JD, Gibson S, Muertos K, Holmes S, Denittis F, et al. Multidisciplinary team approach to traumatic spinal cord injuries: A single institution's quality improvement project. *European Journal of Trauma and Emergency Surgery*. 2018; 44(2):245-50.
27. Bach JA, Leskovan JJ, Scharschmidt T, Boulger C, Papadimos TJ, Russell S, et al. The right team at the right time—multidisciplinary approach to multi-trauma patient with orthopaedic injuries. *International journal of critical illness and injury science*. 2017; 7(1):32.
28. Brink H, Van der Walt C, Van Rensburg GH. *Fundamentals of research methodology for health care professionals*. 3rd ed. ed. Cape Town, South Africa:: Juta; 2012.
29. Gray J, Burns N, Grove SK, Sutherland S. *Burns and grove's the practice of nursing research: Appraisal, synthesis, and generation of evidence* 2017.
30. Feder G, Eccles M, Grol R, Griffiths C, Grimshaw J. Using clinical guidelines. *BMJ*. 1999; 318(7185):728-30.
31. Davies AM, Pettersson H, Pettersson H, Arredondo F. *The who manual of diagnostic imaging: Radiographic anatomy and interpretation of the musculoskeletal system*: World Health Organization; 2002.
32. Lodox company. *Lodox world*. 2021.
33. Kelly B. The chest radiograph. *The Ulster medical journal*. 2012; 81(3):143-8.
34. De Vos AS. *Research at grassroots: For the social sciences and human services professions*. Pretoria: Van Schaik; 2011.
35. Mouton J. *How to succeed in your master's and doctoral studies*. Van Schaik. 2001.
36. Burns N, Grove SK. *The practice of nursing research: Conduct, critique, and utilization*. 5th ed. ed. St. Louis, Mo.: Elsevier/Saunders; 2005.
37. Trevelyan EG, Robinson N. Delphi methodology in health research: How to do it? *European Journal of Integrative Medicine*. 2015; 7(4):423-8.
38. Msibi PN, Mogale R, de Waal M, Ngcobo N. Using e-Delphi to formulate and appraise the guidelines for women's health concerns at a coal mine: A case study. *Curationis*. 2018; 41(1):1-6.
39. World Health Organization. *Who handbook for guideline development*: World Health Organization; 2014.
40. Grisham T. The Delphi technique: A method for testing complex and multifaceted topics. *International Journal of Managing Projects in Business*. 2009; 2(1):112-30.
41. Kousha K, Thelwall M, Rezaie S. Assessing the citation impact of books: The role of google books, google scholar, and Scopus. *Journal of the American Society for information science and technology*. 2011; 62(11):2147-64.
42. Daya RB, Kibel MA, Pitcher RD, Workman L, Douglas TS, Sanders V. A pilot study evaluating erect chest imaging in children, using the lodox Statscan digital x-ray machine. *SA Journal of Radiology*. 2009; 13(4).
43. Carlton RR, Adler AM. *Principles of radiographic imaging: An art and a science*. 5th ed. ed. Clifton Park, NY:: Delmar/Cengage Learning; 2013.
44. Lodox C [Internet] *Lodox critical imaging technology*. Johannesburg 2018 [cited 2018 05 June 2018]. Available from: <http://lodox.com/trauma/#xmplar-dr>
45. Carver E, Carver B. *Medical imaging: Techniques. Reflection and Evaluation*. 2006.

46. Szucs-Farkas Z, Vock P. Image quality of supine chest radiographs: Intra-individual comparison of computed radiography and low-dose linear-slit digital radiography. *European radiology*. 2009; 19(9):2156-62.
47. Bontrager KL, Lampignano J. *Bontrager's handbook of radiographic positioning and techniques*. 9th ed: Elsevier Health Sciences; 2017.
48. Ball J, Price T. Chesney's radiographic imaging. *Magnetic Resonance Imaging*. 1996; 9(14):1117.
49. Carver E, Carver B. *Medical imaging-e-book: Techniques, reflection and evaluation*: Elsevier Health Sciences; 2012.
50. Walker CM, Chung JH. *Muller's imaging of the chest e-book: Expert radiology series*: Elsevier Health Sciences; 2018.
51. Parker MS, Abbott GF, Rosado-de-Christenson ML. *Teaching atlas of chest imaging*: Thieme Medical Publishers; 2006.
52. Dalley II AF, Agur AM, Moore KL. *Essential clinical anatomy* 2015.
53. Waugh A, Grant A. *Ross & Wilson anatomy and physiology in health and illness e-book*: Elsevier Health Sciences; 2014.
54. Costantino M, Gosselin MV, Primack SL, editors. *The ABCs of thoracic trauma imaging. Seminars in roentgenology*; 2006: Elsevier.
55. Lomoschitz FM, Eisenhuber E, Linnau KF, Peloschek P, Schoder M, Bankier AA. Imaging of chest trauma: Radiological patterns of injury and diagnostic algorithms. *European journal of radiology*. 2003; 48(1):61-70.
56. Scaglione M, Linsenmaier U, Schueller G, Berger F, Wirth S. *Emergency radiology of the chest and cardiovascular system*: Springer; 2016.
57. Herring W. *Learning radiology: Recognizing the basics*. 2020.
58. Rockall AG, Hatrick A, Armstrong P, Wastie M. *Diagnostic imaging*: John Wiley & Sons; 2013.
59. Klein J, Pohl J, Vinson EN, Brant WE, Helms CA. *Brant and helms' fundamentals of diagnostic radiology*: Lippincott Williams & Wilkins; 2018.
60. Collins J, Stern EJ. *Chest radiology: The essentials*: Lippincott Williams & Wilkins; 2012.
61. Corne J, Kumaran M. *Chest x-ray made easy*: Elsevier Health Sciences; 2015.
62. Eisenberg RL, Johnson NM. *Comprehensive radiographic pathology*.: Elsevier Health Sciences; 2015.
63. Walker CM, Abbott GF, Greene RE, Shepard J-AO, Vummidi D, Digumarthy SR. Imaging pulmonary infection: Classic signs and patterns. *American Journal of Roentgenology*. 2014; 202(3):479-92.
64. Ellis SM, Flower C. *The who manual of diagnostic imaging: Radiographic anatomy and interpretation of the chest and the pulmonary system*: World Health Organization; 2006.
65. Ho M-L, Gutierrez FR. Chest radiography in thoracic polytrauma. *American Journal of Roentgenology*. 2009; 192(3):599-612.
66. Vyborny CJ. Image quality and the clinical radiographic examination. *Radiographics*. 1997; 17(2):479-98.
67. Carroll QB. *Radiography in the digital age: Physics-exposure-radiation biology*: Charles C Thomas Publisher; 2011.
68. Bushong SC. *Radiologic science for technologists. Physics, biology, and protection*: Elsevier Health Sciences; 2016.
69. Thayalan K. *The physics of radiology and imaging*: JP Medical Ltd; 2014.
70. Bontrager KL, Lampignano JP. *Textbook of radiographic positioning and related anatomy*. 6th ed. ed. St. Louis, Mo. :: Elsevier Mosby; 2005.
71. Stull KE, L'abbé EN, Steiner S. Measuring distortion of skeletal elements in Iodex Statscan-generated images. *Clinical anatomy*. 2013; 26(6):780-6.

72. Evangelopoulos DS, Deyle S, Brehmer T, Benneker LM, Hasler R, Martinolli L, et al. The efficiency of full-body radiography 'Iodox Statscan' in the detection of peripheral skeletal fractures in adult trauma patients. *INJURY EXTRA*. 2010; 41(12):132.
73. Beets MP. Distortion correction in Iodox Statscan x-ray images: University of Cape Town; 2007.
74. Fauber TL. Radiographic imaging & exposure 2017.
75. PTW-Freiburg [Internet] Normi 13 operating manual for diagnostic imaging. Germany: Brilliance Innovations; 2015 [cited 2018 23 October 2018]. Available from: <https://www.ptwdosimetry.com>
76. Huda W, Abrahams RB. X-ray-based medical imaging and resolution. *American Journal of Roentgenology*. 2015; 204(4): W393-W7.
77. Lodox company [Internet] Full-body high-speed digital radiology with low radiation emission and scatter. Sandton, n.d. [cited 2020 20 June]. Available from: http://mitech.co.kr/download/technology/Lodox_Xmplar-dr_Full_Technical_Specifications.pdf
78. Nishankar H, Shankar A, Nagesh SS, Bednarek D, Rudin S, editors. Demonstration of improved image resolution for larger focal spot sizes by decreasing anode angles in clinical settings. *Medical Imaging 2019: Biomedical Applications in Molecular, Structural, and Functional Imaging*; 2019: International Society for Optics and Photonics.
79. Lindell B, Dunster HJ, Valentin J. International commission on radiological protection: History, policies, procedures. Swedish Radiation Protection Institute, SE. 1998; 171:16.
80. Huda W, Slone RM. Review of radiologic physics: Lippincott Williams & Wilkins; 2003.
81. Kulkarni M, Dendere R, Nicolls F, Steiner S, Douglas TS. Monte-Carlo simulation of a slot-scanning x-ray imaging system. *Physica Medica*. 2016; 32(1):284-9.
82. Desai N, Valentino DJ, editors. A software tool for quality assurance of computed/digital radiography (cr/dr) systems. *Medical Imaging 2011: Physics of Medical Imaging*; 2011: International Society for Optics and Photonics.
83. Adler AM, Carlton RR. Introduction to radiologic and imaging sciences and patient care - e-book 2015.
84. Potgieter JH, de Villiers M, Scheelke M, de Jager G, editors. An explanation for the extremely low, but variable, radiation dosages measured in a linear slot scanning radiography system. *Medical Imaging 2005: Physics of Medical Imaging*; 2005: International Society for Optics and Photonics.
85. Foth T, Efstathiou N, Vanderspank-Wright B, Ufholz L-A, Dütthorn N, Zimansky M, et al. The use of Delphi and nominal group technique in nursing education: A review. *International Journal of Nursing Studies*. 2016; 60:112-20.
86. Okoli C, Pawlowski SD. The Delphi method as a research tool: An example, design considerations and applications. *Information & management*. 2004; 42(1):15-29.
87. Thangaratinam S, Redman CW. The Delphi technique. *The obstetrician & gynaecologist*. 2005; 7(2):120-5.
88. Cantrill J, Sibbald B, Buetow S. The Delphi and nominal group techniques in health services research. *International Journal of Pharmacy Practice*. 1996; 4(2):67-74.
89. McMillan SS, Kelly F, Sav A, Kendall E, King MA, Whitty JA, et al. Using the nominal group technique: How to analyse across multiple groups. *Health Services and Outcomes Research Methodology*. 2014; 14(3):92-108.
90. Lennon R, Glasper A, Carpenter D. Nominal group technique: Its utilisation to explore the rewards and challenges of becoming a mental health nurse, before the introduction of the all graduate nursing curriculum in England. *Work. Pap. Health Sci*. 2012; 1(2):1-5.
91. Brouwers MC, Kho ME, Browman GP, Burgers JS, Cluzeau F, Feder G, et al. Agree ii: Advancing guideline development, reporting and evaluation in health care. *Canadian Medical Association Journal*. 2010; 182(18):E839-E42.

92. Welman J, Kruger S, Mitchele B. Research methodology. Cape Town: Oxford university press southern Africa. 2009.
93. Kivunja C, Kuyini AB. Understanding and applying research paradigms in educational contexts. *International Journal of Higher Education*. 2017; 6(5):26.
94. De Vos AS. Research at grassroots: For the social sciences and human services professions: Van Schaik; 2009.
95. Brink H, Van der Walt C, Van Rensburg GH. Fundamentals of research methodology for healthcare professionals. 2018.
96. Mackenzie N, Knipe S. Research dilemmas: Paradigms, methods and methodology. *Issues in educational research*. 2006; 16(2):193-205.
97. Kothari CR. Research methodology: Methods and techniques: New Age International; 2004.
98. White MD, Marsh EE. Content analysis: A flexible methodology. *Library trends*. 2006; 55(1):22-45.
99. Stemler S. An overview of content analysis. *Practical assessment, research & evaluation*. 2001; 7(17):137-46.
100. Walliman N. Research methods: The basics: Routledge; 2017.
101. DePoy E, Gitlin LN. Introduction to research: Understanding and applying multiple strategies 2016.
102. Mills AJ, Durepos G, Wiebe E. Encyclopedia of case study research: L-z; index: Sage; 2009.
103. Erlingsson C, Brysiewicz P. A hands-on guide to doing content analysis. *African Journal of Emergency Medicine*. 2017; 7(3):93-9.
104. Bock A, Isermann H, Knieper T. Quantitative content analysis of the visual. *The Sage handbook of visual research methods*. 2011:265-82.
105. Zhao B, Tan Y, Bell DJ, Marley SE, Guo P, Mann H, et al. Exploring intra- and inter-reader variability in uni-dimensional, bi-dimensional, and volumetric measurements of solid tumours on ct scans reconstructed at different slice intervals. *European journal of radiology*. 2013; 82(6):959-68.
106. Groenewald A, Groenewald WA. Development of a universal medical x-ray imaging phantom prototype. *Journal of applied clinical medical physics*. 2016; 17(6):356-65.
107. Taylor-Powell E, Steele S. Collecting evaluation data: Direct observation. *Program Development and Evaluation*. Wisconsin: University of Wisconsin-Extension. 1996:1-7.
108. Jersild AT, Meigs MF. Chapter v: Direct observation as a research method. *Review of Educational Research*. 1939; 9(5):472-82.
109. MicroDicom [Internet] Downloads for microdicom Dicom viewer version 3.0.1. 2019. Available from: <https://www.microdicom.com/downloads.html>
110. Inventions B [Internet] Normi 13, x-ray test object. Germany: PTW-Freiburg; 1922 [23 October 2017].
111. Al Sulaiman R. Establishing a quality assurance routine for digital imaging: Wright State University; 2018.
112. Meghzifene A, Vano E, Le Heron J, Cheung K. Roles and responsibilities of medical physicists in radiation protection. *European journal of radiology*. 2010; 76(1):24-7.
113. World Health Organization. Who handbook for guideline development. *Who handbook for guideline development* 2011.
114. Polit DF, Beck CT. Nursing research: Generating and assessing evidence for nursing practice.
115. Brink H, Van der Walt C, Van Rensburg GH. Fundamentals of research methodology for healthcare professionals 2018.
116. Du Plessis E, Human SP. The art of the Delphi technique: Highlighting its scientific merit. *Health SA Gesondheid*. 2007; 12(4):13-24.
117. WHO. Who handbook for guideline development: World Health Organization; 2014.
118. Hasson F, Keeney S, McKenna H. Research guidelines for the Delphi survey technique. *Journal of advanced nursing*. 2000; 32(4):1008-15.

119. Morse JM, Barrett M, Mayan M, Olson K, Spiers J. Verification strategies for establishing reliability and validity in qualitative research. *International journal of qualitative methods*. 2002; 1(2):13-22.
120. AGREE Collaboration T. Appraisal of guidelines research and evaluation. AGREE Instrument [Online-Text]. 2001.
121. Ding W, Wang Q-G, Zhang J-X. Analysis and prediction of COVID-19 epidemic in South Africa. *ISA Transactions*. 2021.
122. Perrault SJ. Merriam-Webster's advanced learner's English dictionary: Merriam-Webster; 2008.
123. Aigbavboa C, editor. A Delphi technique approach of identifying and validating subsidised low-income housing satisfaction indicators. *International Conference of Korean Housing Association*; 2015.
124. He F, Deng Y, Li W. Coronavirus disease 2019: What we know? *Journal of medical virology*. 2020; 92(7):719-25.
125. Team RC. R: A language and environment for statistical computing. *Foundation for Statistical Computing*. 2013.
126. Team RC [Internet] R: A language and environment for statistical computing. Vienna, Austria 2021 [cited 2021 11 November]. Available from: <https://www.R-project.org/>
127. McKnight PE, Najab J. Mann-Whitney u test. *The Corsini encyclopedia of psychology*. 2010:1.
128. Multon KDaC, J S M. *The sage encyclopedia of educational research, measurement, and evaluation*. 2018.
129. Tinsley HE, Weiss DJ. Interrater reliability and agreement. *Handbook of applied multivariate statistics and mathematical modelling*: Elsevier; 2000. p. 95-124.
130. McHugh ML. Interrater reliability: The kappa statistic. *Biochemia Medica*. 2012; 22(3):276-82.
131. Landis JR, Koch GG. The measurement of observer agreement for categorical data. *biometrics*. 1977:159-74.
132. Lavrakas PJ. *Encyclopedia of survey research methods*: Sage publications; 2008.
133. Mucci B, Murray H, Downie A, Osborne K. Interrater variation in scoring radiological discrepancies. *The British journal of radiology*. 2013; 86(1028):20130245.
134. Planner A, Uthappa MC, Misra RR. *A-z of chest radiology*. Cambridge: Cambridge University Press; 2007.
135. Nuth EK, Armbrust LJ, Roush JK, Biller DS. Identification and effects of common errors and artefacts on the perceived quality of radiographs. *Journal of the American Veterinary Medical Association*. 2014; 244(8):961-7.
136. Whitley AS, Jefferson G, Holmes K, Sloane C, Anderson C, Hoadley G. *Clark's positioning in radiography 13e*: CRC Press; 2015.
137. Henny GC. Artefacts in roentgen films. *Radiology*. 1935; 24(3):350-6.
138. Adejoh T, Onwuzu S, Nkubli F, Ikegwuonu N. Film-screen radiographic artefacts: A paradigm shift in classification. *Open Journal of Medical Imaging*. 2014; 4(03):108.
139. Suki B, Stamenović D, Hubmayr R. Lung parenchymal mechanics. *Comprehensive Physiology*. 2011; 1(3):1317-51.
140. Page M. *The British medical association illustrated medical dictionary*: Dorling Kindersley; 2002.
141. Chen R-J, Fu C-Y, Wu S-C, Wang Y-C, Chung P-K, Huang H-C, et al. Diagnostic accuracy, biohazard safety, and cost-effectiveness—the Iodox/Statscan provides a beneficial alternative for the primary evaluation of patients with multiple injuries. *Journal of Trauma and Acute Care Surgery*. 2010; 69(4):826-30.
142. Chen J-D, Shanmuganathan K, Mirvis SE, Killeen KL, Dutton RP. Using ct to diagnose tracheal rupture. *American Journal of Roentgenology*. 2001; 176(5):1273-80.

143. Wright JL, Lawson L, Paré PD, Hooper RO, Peretz DI, Nelems JB, et al. The structure and function of the pulmonary vasculature in mild chronic obstructive pulmonary disease: The effect of oxygen and exercise. *American Review of Respiratory Disease*. 1983; 128(4):702-7.
144. Engeler CE, Tashjian JH, Trenkner SW, Walsh JW. Ground-glass opacity of the lung parenchyma: A guide to analysis with high-resolution ct. *AJR. American journal of roentgenology*. 1993; 160(2):249-51.
145. Nowers K, Rasband JD, Berges G, Gosselin M, editors. *Approach to ground-glass opacification of the lung. Seminars in Ultrasound, CT and MRI*; 2002: Elsevier.
146. Carroll QB. *Instructor resources for radiography in the digital age*. Springfield, IL: Charles C. Thomas Publisher; 2011.
147. Health Nif, Excellence C. *How nice clinical guidelines are developed: An overview for stakeholders, the public and the NHS*: National Institute for Health and Clinical Excellence; 2009.
148. South African National Government. *Hazardous substances act 15 of 1973*. In: Health NDo, editor. Cape Town: National Department of Health; 1973. p. 1-30.
149. South African National Government. *Policy on requesting medical x-ray examinations*. In: Directorate for Radiation Control, editor. Pretoria: South African Health Products Regulatory Authority; 2016.
150. Kool DR, Blickman JG. *Advanced trauma life support®. Abcde from a radiological point of view. Emergency radiology*. 2007; 14(3):135-41.
151. Committee on Trauma. *Advanced trauma life support student course manual*, ACS American College of Surgeons, American College of Surgeons; 2012.
152. Mock C. *Guidelines for essential trauma care*: World Health Organization; 2004.
153. Azad AD, Kong VY, Clarke DL, Laing GL, Bruce JL, Chao TE. Use of vital signs in predicting surgical intervention in a South African population: A cross-sectional study. *International Journal of Surgery*. 2020; 79:300-4.
154. Gottschalk S. *Triage—a South African perspective. Continuing Medical Education*. 2004; 22(6).
155. Louis CJ, Caminos CB, Esain BF, Diez DR, Otano TB. *Prehospital management of trauma patients*.
156. Thali MJ, Viner MD, Brogdon BG. *Brogdon's forensic radiology*: CRC Press; 2010.
157. Douglas T, Fenton-Muir N, Kewana K, Ngema Y, Liebenberg L. *Radiological findings at a South African forensic pathology laboratory in cases of sudden unexpected death in infants. SA Journal of Radiology*. 2012; 16(1).
158. Fathi A-R, Mariani L, Farkas ZS, Exadaktylos A-K, Bonel HM. Evaluation of the new Statscan radiography device for ventriculoperitoneal shunt assessment. *American journal of roentgenology*. 2011; 196(3): W285-W9.
159. Belfer RA, Klein BL, Orr L. Use of the skeletal survey in the evaluation of child maltreatment. *The American journal of emergency medicine*. 2001; 19(2):122-4.
160. LOUIS CJ, CAMINOS CB, ESAIN BF, DÍEZ DR, OTANO TB. *Prehospital management of trauma patients*.
161. Tins BJ. *Imaging investigations in spine trauma: The value of commonly used imaging modalities and emerging imaging modalities. Journal of clinical orthopaedics and trauma*. 2017; 8(2):107-15.
162. Jorgenson KM, Lanter J, Wiens Do AL. *Benefits of utilizing full-body Iodex digital radiography in forensic pathology. Academic Forensic Pathology*. 2015; 5(3):492-8.
163. Bloom BA, Gibbons RC. *Focused assessment with sonography for trauma. StatPearls [Internet]*. 2020.
164. Richards JR, McGahan JP. *Focused assessment with sonography in trauma (fast) in 2017: What radiologists can learn. Radiology*. 2017; 283(1):30-48.

165. Paydar S, Johari HG, Ghaffarpasand F, Shahidian D, Dehbozorgi A, Ziaeiian B, et al. The role of routine chest radiography in the initial evaluation of stable blunt trauma patients. *The American journal of emergency medicine*. 2012; 30(1):1-4.
166. McCloud TC. *Thoracic radiology: The requisites e-book*: Elsevier Health Sciences; 2010.
167. Tabbara M, Evangelopoulos DS, Zimmermann H, Exadaktylos A. Full body low radiation radiography using Iodex Statscan. *British journal of hospital medicine*. 2011; 72(2):86-9.
168. Mama N, Jemni H, Achour NA, Sidiya OC, Kadri K, Gaha M, et al. Abdominal trauma imaging. *Abdominal Surgery*. 2012:1.
169. Gans SL, Stoker J, Boermeester MA. Plain abdominal radiography in acute abdominal pain; past, present, and future. *International journal of general medicine*. 2012; 5:525.
170. Demetriades D, Newton E. *Color atlas of emergency trauma*: Cambridge University Press; 2011.
171. Pullicino G, Thompson J, Grech EM, Sciortino P. A study on plain x-ray skull imaging in the public primary health care department in Malta. 2018.
172. Willett JK. Imaging in trauma in limited-resource settings: A literature review. *African Journal of Emergency Medicine*. 2018.
173. Wüstner A, Gehmacher O, Hämmerle S, Schenkenbach C, Häfele H, Mathis G. Ultrasound diagnosis in blunt thoracic trauma. *Ultraschall in der Medizin (Stuttgart, Germany)*. 2005; 26(4):285-90.
174. Oikonomou A, Prassopoulos P. Ct imaging of blunt chest trauma. *Insights into imaging*. 2011; 2(3):281-95.
175. Khunti K. Near-patient testing in primary care. *British Journal of General Practice*; 2010.
176. Pai M, Ghiasi M, Pai NP. The main goal of such testing is to inform caregivers in ways that lead rapidly to their starting correct treatments for patients. *Microbe*. 2015; 10(3):103-107.

ANNEXURES

ANNEXURE A: RESULTS FOR A PILOT STUDY

How Lodox x-ray systems are currently used in hospitals

Twenty-eight hospitals in South Africa have Lodox x-ray systems installed at trauma units. All the hospitals were contacted, only twenty (71.40%) of the twenty-eight hospitals responded. At each hospital, one radiographer that was working using the Lodox x-ray system completed an online questionnaire.

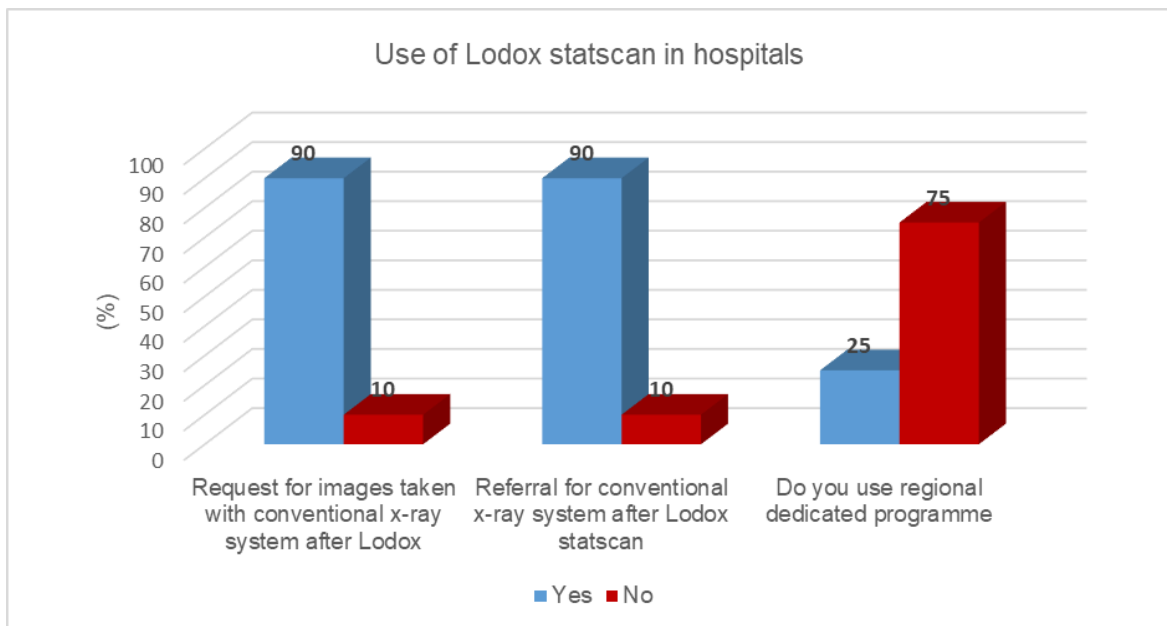


Figure 1: Reporting of Lodox images and the use of the regional dedicated programme.

- 90.00% of the twenty hospitals in South Africa received requests for conventional images after patients have undergone Lodox imaging.
- 75.00% of the twenty hospitals were not using the regional dedicated programme of the Lodox x-ray system.

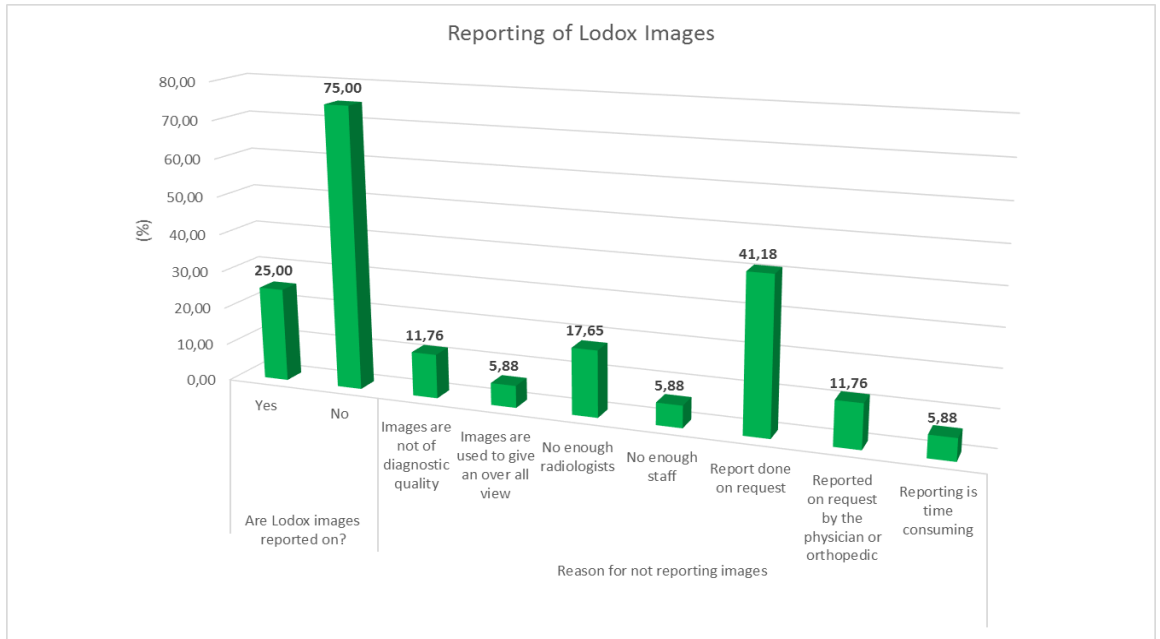


Figure 2: Are the Lodox images reported? What are the reasons for non-reporting

- 75.00% stated that Lodox x-ray system images were not reported.
- The reasons stated where reports are done only on request (41.18%), not enough radiologists/staff to report (23.53%), 11.76% stated that images are of poor diagnostic quality.

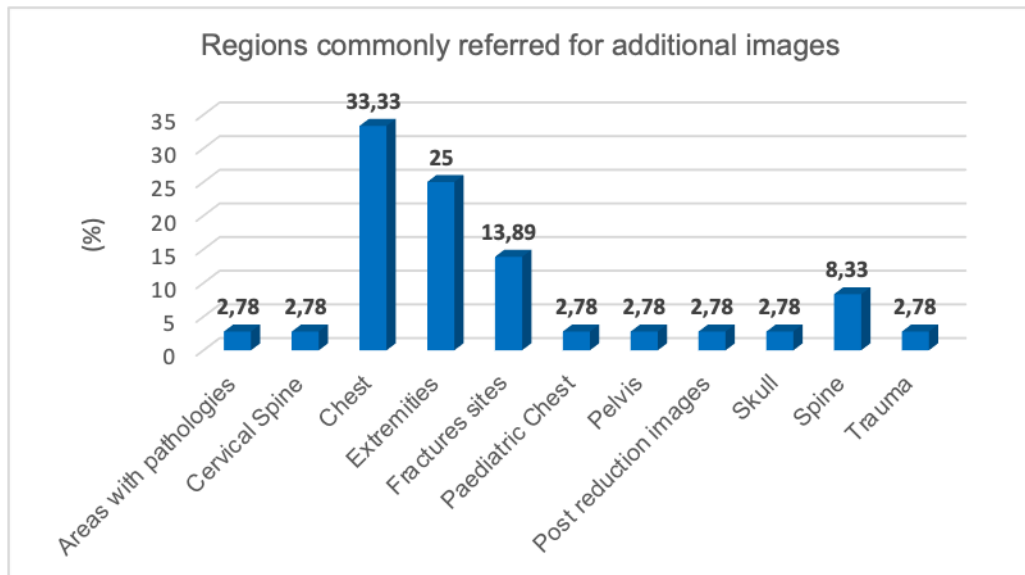


Figure 3: Regions commonly referred/are routinely referred for additional images on conventional systems

- Both adult and paediatric chest 36.11%, extremities 25.00%, fractures 13.89%, spine 8.33%, pelvis, trauma, post-reduction images, skulls, cervical spine, and areas with pathology had 2.75%.

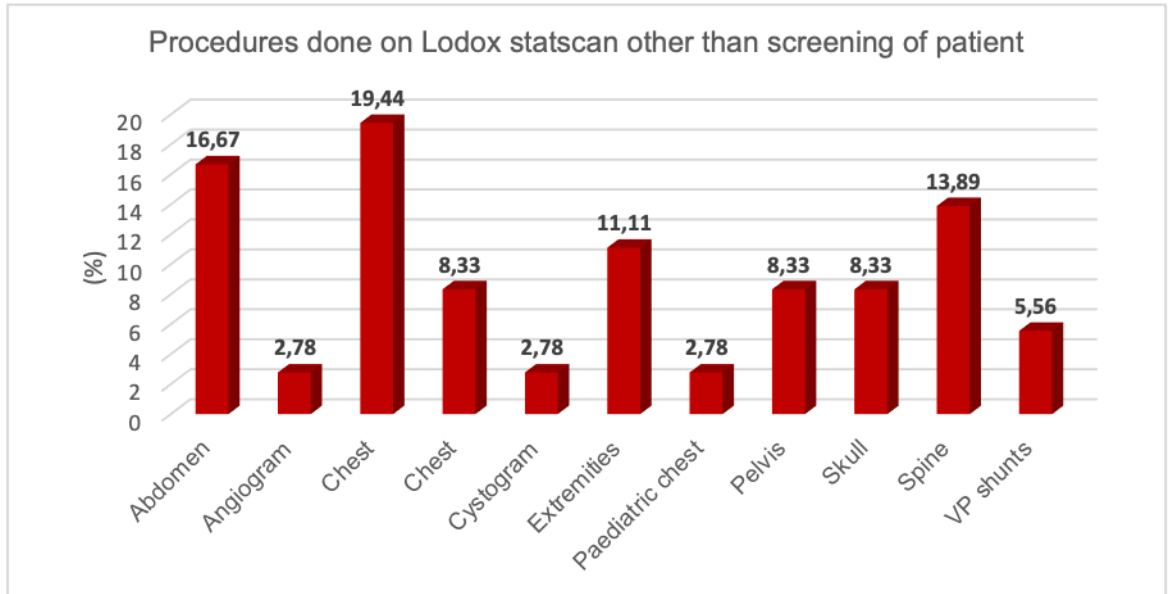


Figure 4: Other imaging procedures performed on Lodox Statscan than the screening of a patient

- Chests 27.77%, Abdomen 16.67%, spine 13.89% extremities had 11.11%, skull and pelvis had 8.33%, VP stunt 5.56%, paediatric chest and cystogram had 2.78%

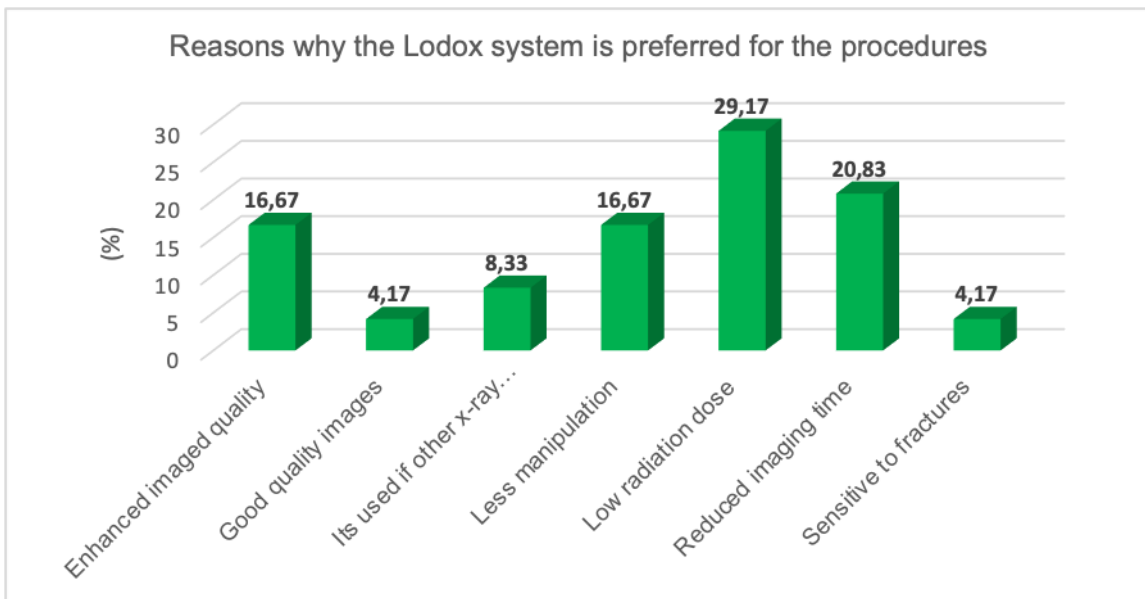


Figure 5: Reasons why Lodox Statscan is preferred for other procedures

- Respondents indicated reasons for using Lodox x-ray system as low radiation dose 29.17%, reduced imaging time 20.83%, fewer manipulations of the patient and enhanced image quality, 16.67% indicated that lodox required less manipulation of the equipment, 8.33% indicated that lodox x-ray system was used when other imaging equipments were busy, and 4.17% indicated that lodox produced quality images and also images obtained from the Lodox x-ray system were sensitive to fractures.

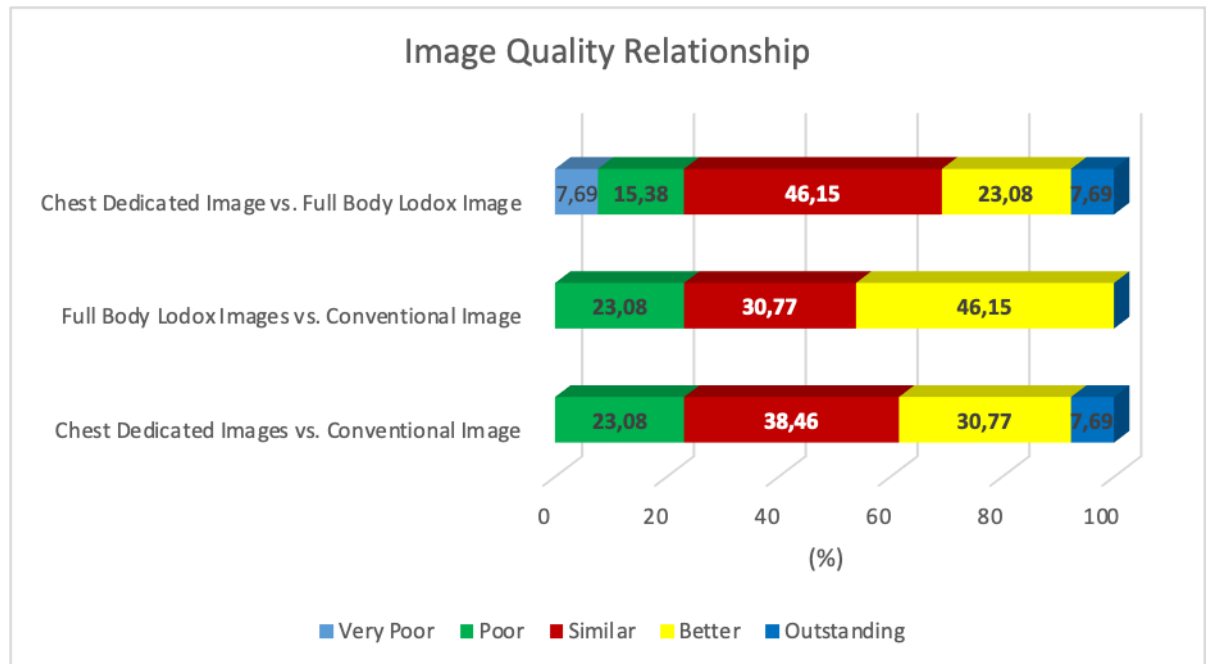


Figure 6: Comparison between qualities of Lodox full-body scan, dedicated images, and conventional x-ray system images

- Dedicated images are (similar to) = full-body Lodox Statscan.*
- Full-body Lodox x-ray system is better than conventional images.*

ANNEXURE B: RADIOLOGISTS' CHECKLISTS

Radiologists' checklist.

Please mark (1 indicating / Network Marketing Market Report 2018.

Visible or Good) 2- Partially visible or Satisfactory and (0 = **Poor/invisible**) on each of the following features on the radiographs given. **You may comment on a possible cause of the differences seen.**


| Variables | | Radiograph A | Radiograph B | Comment |
|-----------|---|-----------------|-----------------|---------|
| 1. | Exposure artefacts/ chevron exposure artefact | | | |
| 2. | Penetration | | | |
| 3. | Pulmonary vasculature shown | | | |
| 4. | Lungs Parenchyma visualised | | | |
| 5. | Lund infiltrates visualised | | | |
| 6. | Breast tissues outline visualised | | | |
| 7. | Thoracic cage soft tissue outlines visualised | | | |
| 8. | The trachea and proximal bronchi shown | | | |
| 9. | Pulmonary vessels peripherally shown | | | |
| 10. | Cardiac and Aorta outline visualised | | | |
| 11. | Retro-cardiac and mediastinum outline clear | | | |
| 12. | Thoracic spine (vertebral bodies and disc spaces) | | | |
| 13. | Lung contusion | | | |
| 14. | Pneumothorax | | | |
| 15. | Effusions | | | |
| 16. | Pneumomediastinum | | | |
| 17. | Surgical emphysema | | | |
| 18. | Extra-luminal air | | | |
| 19. | Nodules | | | |

| | | | | |
|-----|------------------------------------|--|--|--|
| 20. | Interstitial changes | | | |
| 21. | Air bronchograms | | | |
| 22. | Granular glass opacity | | | |
| 23. | Bullae | | | |
| 24. | Mediastinal injuries | | | |
| 25. | Fracture ribs, clavicle | | | |
| 26. | Thoracic spine fracture | | | |
| 27. | Vertebral body or spinous fracture | | | |
| 28. | Thoracic spine lesions | | | |
| 29. | Diaphragms | | | |
| 30. | Other's observations | | | |

ANNEXURE C: QUALITY ASSURANCE CHECKLISTS

| QUALITY ASSURANCE CHECKLIST | | | | |
|--|---|--|--|--|
| Conventional machine (Make and model) | | | | |
| Lodox x-ray system (Year manufactured) | | | | |
| Variable | A digital conventional imaging system (metric units) | Manufacturer. Threshold (metric units) | Lodox Statscan imaging system (metric units) | Manufacturer. Threshold (metric units) |
| Distortion/ Scaling error | | | | |
| Spatial resolution | | | | |
| Contrast resolution | | | | |
| Noise | | | | |

ANNEXURE D: MOTIVATION LETTER FROM PHYSICISTS



RATE Medical Physics Consulting
137 9th Road
Carlswald
Midrand
1684
Email: info@ratempc.co.za

Mr MJ Thambura
University of Pretoria
Faculty of Health Sciences
Bophelo Road
Gezina
0001
30 May 2018

Dear Julius

RE: Motivation for acquiring additional radiographic images on a selected group of patients

I write in response to the motivation letter dated 15th May 2018 regarding the necessity to acquire additional radiographic images in connection with your research study. I hereby would like to confirm that research studies have proven that radiation doses from the Lodox Statscan X-ray units are significantly minimal compared to those from conventional X-ray units.

A typical posterior anterior (PA) chest X-ray amounts to approximately 0.02 mSv of effective dose to the patient on a conventional X-ray unit. Since the Lodox can produce a full-body image using about a third of the radiation required to produce an equivalent image by a conventional X-ray unit, the estimated radiation dose for a PA chest image would be 0.0067 mSv.

Thus, the request for additional radiographic images using the Lodox Statscan would not pose any delirious effects on the selected group of patients for the research study.

Thank you

Kindest regards

RT Molatedi

A handwritten signature in black ink that reads "Molatedi". The signature is written in a cursive style and is positioned above a horizontal line.

Consultant Medical Physicist

Radiologie Technik (Pty) Ltd
t/a RATE Medical Physics Consulting
Reg. no: 2017/294025/07

137 9th Road
Carlswald
Midrand
1684
Tel: 072 208 6304
Email: info@ratempc.co.za

ANNEXURE E: SAMPLE OF HOSPITALS ETHICS APPROVAL (DR GEORGE MUKHARI ACADEMIC HOSPITAL)



GAUTENG PROVINCE
HEALTH
REPUBLIC OF SOUTH AFRICA

Dr. George Mukhari Academic Hospital

Office of the Director Clinical Services

Enquiries : Dr. C Holm

Tel : (012) 529 3691

Fax : (012) 560 0099

Email:Christene.Holm@gauteng.gov.za

keitumetse.mongale@gauteng.gov.za

To Mr M.J Thambura
Faculty of Health and Science
Department of Radiography
University of Pretoria
Pretoria
0007

Date : 05 April 2019

PERMISSION TO CONDUCT RESEARCH

The Dr. George Mukhari Academic Hospital hereby grants you permission to conduct research on "Development of an adult chest imaging protocol for Iodox system at trauma unit in South Africa at Dr George Mukhari Academic Hospital

This permission is granted subject to the following conditions:

- That you obtain Ethical Clearance from the Human Research Ethics Committee of the relevant University
- NB* That the Hospital incurs no cost in the course of your research
- That access to the staff and patients at the Dr George Mukhari Hospital will not interrupt the daily provision of services.
- That prior to conducting the research you will liaise with the supervisors of the relevant sections to introduce yourself (with this letter) and to make arrangements with them in a manner that is convenient to the sections.
- Formal written feedback on research outcomes must be given to the Director: Clinical Services
- Permission for publication of research must be obtained from the Chief Executive Officer

Yours sincerely



DR. C. HOLM
ACTING DIRECTOR CLINICAL SERVICES

DATE: 5/4/19

ANNEXURE F: LETTER OF CONSULTATION TO THE STATISTICIAN



UNIVERSITEIT VAN PRETORIA
UNIVERSITY OF PRETORIA
YUNIBESITHI YA PRETORIA
Denkleiers • Leading Minds • Dikgopolo tša Dihalefi

DEPARTMENT OF STATISTICS

LETTER OF STATISTICAL SUPPORT

Date: 25th February 2022

This letter is to confirm that **Mr. Julius Thambura**, studying at the University of Pretoria, discussed the project with the title '*Development of an adult chest imaging protocol for Lodox systems at trauma units in South Africa.*' with me.

I hereby confirm that I am aware of the project and assisted with statistical analysis of the data generated from the project. The aim of the study was to develop an adult chest imaging protocol for trauma patients undergoing Lodox system imaging at trauma units.

The assistance consisted of two phases:

Pilot Study

To assess the extent of patient referral for additional imaging after full-body imaging with the Lodox statscan has been performed.

The data will be collected using a purposive sample selecting one radiographer for each of the twenty-eight hospitals in South Africa which has a Lodox Statscan. In the case where it's not possible to collect information from all the hospitals, a minimum of 20 hospitals will be considered.

The data analysis will consist of descriptive statistics like modes and frequencies which will summarize the demographics and Lodox Statscan application data collected.

Phase One

Objective 1

Assessing the diagnostic similarity between trauma-chest images obtained from conventional x-ray systems and those obtained by use of full body Lodox system from the same patient.

Convenience sampling will be used to collect retrospectively, 139 chest images taken using conventional x-ray system and 139 images taken using full-body Statscan system programme, from

ANNEXURE G: CRITERIA FOR EVALUATING THE DEVELOPED PROTOCOL

Domains used in the evaluation of guidelines

| DOMAINS | Scope and purpose | | | | Stake holder's involvement | | | | Rigour of the development | | | | Clarity of presentation | | | | Applicability | | | | Editorial Independence | | | |
|---------------------|-------------------|---|---|---|----------------------------|---|---|---|---------------------------|---|---|---|-------------------------|---|---|---|---------------|---|---|---|------------------------|---|---|---|
| | 1 | 2 | 3 | 4 | 1 | 2 | 3 | 4 | 1 | 2 | 3 | 4 | 1 | 2 | 3 | 4 | 1 | 2 | 3 | 4 | 1 | 2 | 3 | 4 |
| Guideline 1 | | | | | | | | | | | | | | | | | | | | | | | | |
| Guideline 2 | | | | | | | | | | | | | | | | | | | | | | | | |
| Guideline 3 | | | | | | | | | | | | | | | | | | | | | | | | |
| Guideline 4 | | | | | | | | | | | | | | | | | | | | | | | | |
| Guideline 5 | | | | | | | | | | | | | | | | | | | | | | | | |
| <i>Total scores</i> | | | | | | | | | | | | | | | | | | | | | | | | |

Definition of four-point scale criteria that guided the scoring of the evaluation on annexure G above

| Criteria | Rating scale | | | |
|-------------------------------------|--------------------------|-----------------|--------------|-----------------------|
| | Strongly disagree (1) | Disagree (2) | Agree (3) | Strongly agree (4) |
| Validity | | | | |
| Reliability | | | | |
| Clarity | | | | |
| Relevance | | | | |
| Comprehensiveness and effectiveness | | | | |
| Flexibility | | | | |
| Acceptability | | | | |
| Validity | | | | |

PARTICIPANT'S. INFORMATION &. INFORMED CONSENT. DOCUMENT.

JM. Thambura.

Department of Radiography.

University of Pretoria.

Dear Participant,

Development of an adult chest imaging protocol for Lodox x-ray systems at trauma units in South Africa.

I am a PhD student at the Department of Radiography, University of Pretoria. You are invited to participate in my research project.

This letter gives information to help you decide if you want to take part in this study. Before you agree, you should fully understand that by agreeing to participate in this research, you will undergo an additional (single image) x-ray image by use of a Lodox x-ray system. This additional chest image may assist radiologists to see more details of your disease. You will not pay for this image; the images are taken free of charge. You will get an additional radiation dose, but lower than that is used by the x-rays that are usually taken by the machines used in an ordinary x-rays system.

If you do not understand any given information or have any other questions, do not hesitate to ask me for clarification. Or you may call me on 0716399818. You should not agree to take part in this study unless you completely understand what is expected of you.

This is a study, is aimed at developing an adult chest imaging protocol for trauma patients undergoing Lodox Statscan imaging. The development of this imaging protocol is expected to reduce the number of images that are taken on the patient at trauma units if they must undergo Lodox scanning. This is because at the moment patients that undergo Lodox scanning at trauma units undergo additional x-rays, which means they get additional radiation doses, increased medical bills, and time wastage at the trauma units. This is what we are trying to address with this research.

The information and your details will be kept confidential. If a publication will be done on this work, your information will be hidden. Please do not write your name on the questionnaire. Your details will not be disclosed or associated with a code assigned to your images/report. This will

ensure anonymity.

The examination will only take 10 minutes of your time.

In case of complaints or issues about this research, please contact the researcher (0716399818) or the Research Ethics Committee of the University of Pretoria, Faculty of Health Sciences, Tswelopele Building, Level 4, Room 4-60. Dr Savage Road, Gemini, Pretoria and telephone number. Tel: 012-356 3085 who approved this study.

Your participation in this study is voluntary. You can refuse to participate or withdraw at any time without giving any reason. Your details will remain anonymous in any publication from this study.

Name of the participant.

Signature of the participant

Name of the person who witnessed the informed consent

Signature of the witness

PARTICIPANT'S. INFORMATION &. INFORMED CONSENT. DOCUMENT.

JM. Thambura.

Department of Radiography.

University of Pretoria.

Dear Participant,

Development of an adult chest imaging protocol for Lodox x-ray systems at trauma units in South Africa

I am a PhD student, at the. Department of Radiography, University of Pretoria. In the fulfilment of my doctoral degree, I am expected to conduct research. As part of my research, I expected to develop an adult chest imaging protocol for Lodox x-ray systems at trauma units. In fulfilling this, I am in a process of formulating and verifying guidelines that will be used in formulating the imaging protocol. The reason why the researcher is developing this imaging protocol is to reduce the number of images that are taken on the patient at trauma units if they must undergo Lodox scanning. This is because at the moment patients that undergo Lodox scanning at trauma units undergo additional x-rays, which means they get additional radiation doses, increased medical bills, and time wastage at the trauma units. This is what we are trying to address with this research.

As an expert in the trauma speciality, you are invited to participate in the Delphi technique of data collection. In this data collection method, you will be contacted by email, you will be expected to read complete the questions that will be accessible by clicking/opening a link. Before participating you will be expected to read through this disclaimer (in form of a letter of participation and information consent) to choose either to participate in this research or decline participation. This will be done by one of the two options that will have a button. The second round of. Delphi technique will be developed using preliminary guidelines developed by the researcher from the first round, where similar inputs from participants will be summarised and used to develop a second questionnaire. A third round of. Delphi may be conducted where you will be expected to verify the formulated guidelines. Additionally, you will be sent a link with a guideline validation tool to rate each guideline against the criteria stated on that rating tool.

Therefore, this letter gives you information to help you decide if you want to take part in this study. Before you agree, you should fully understand that by agreeing to participate in this

research, you will not receive any benefits in the form of monetary compensation, whatsoever.

If you do not understand any given information or have any other questions, do not hesitate to ask me for clarification. Or you may call me on 0716399818. You should not agree to take part in this study unless you completely understand what is expected of you.

The protocol for this research was submitted to the Faculty of Health Sciences Research Ethics Committee, the University of Pretoria for review, and written approval was granted by the committee (**Protocol 35/2019**). The research has been structured following the Declaration of Helsinki (last update: October 2013), which deals with the recommendations guiding research involving human subjects. A copy of this Declaration may be obtained from the researcher should you wish to review it.

The information and your details will be kept confidential. And if the publication will be done on this work, your information will be hidden. Please do not write your name on the questionnaire. Your details will not be disclosed or associated with your responses/input. This will ensure anonymity.

The examination will only take 10 minutes of your time.

In case of complaints or issues or requests for clarification about this research, please contact the researcher (0716399818) or the Research Ethics Committee of the University of Pretoria, Faculty of Health Sciences, Tswelopele Building, Level 4, Room 4-60. Dr Savage Road, Gemini, Pretoria and telephone number. Tel: 012-356 3085 who approved this study.

Your participation in this study is voluntary. You can refuse to participate, or you can withdraw at any time without any penalty imposed on you.

Name of the participant _____ Signature of the participant _____.

Name of the person who witnessed the informed consent. _____.

Signature of the witness _____.

ANNEXURE J: DELPHI QUESTIONS ROUND 1 (OBJECTIVE 1)

E-DELPHI QUESTIONS ROUND ONE

- *This questionnaire has two sections.*
- *Select answers by marking X, where applicable.*
- *Regular x-ray system also means conventional x-rays*

SECTION. A: Demographics

1. What is your Gender? Male Female
2. How old are you? _____.
3. How long have you been working at a trauma unit? _____.
4. How long have you been working at a trauma unit where the Lodox x-ray system is being used?
5. What is your highest qualification in trauma? Mark X where applicable.

| | |
|---------------------|--------------------------|
| | Medical practitioner |
| | Surgical specialists |
| | Trauma specialists |
| | Trauma subspecialists |
| | Trauma specialists nurse |
| Other (specialist) | |

6. Which university did you obtain your trauma qualifications from?

SECTION B:

7. Is it necessary to have a universal referral guideline that may be used in all the hospitals on trauma patients undergoing Lodox imaging?

| | | | |
|-----|--|----|--|
| Yes | | No | |
|-----|--|----|--|

8. Who amongst these should request full-body Lodox imaging for trauma patients?

| | | | | | | | |
|--------|--|--------------------|--|----------------------|--|-----|--|
| Nurses | | Trauma specialists | | Medical practitioner | | All | |
|--------|--|--------------------|--|----------------------|--|-----|--|

9. State a reason for the choice above?

-----.

10. Did you receive training on the use of the Lodox x-ray system before referring patients for Lodox scanning?

11. Have you received training on regional dedicated programmes of a Lodox Statscan system?

| | | | |
|-----|--|----|--|
| Yes | | No | |
|-----|--|----|--|

12. If yes to No. 11 above, do you request Lodox regional dedicated images than a full-body scan?

| | | | |
|-----|--|----|--|
| Yes | | No | |
|-----|--|----|--|

13. What training would you like to receive on Lodox imaging?

14. Drag and drop the statements that describe the activities that are performed in the prehospital setting before scanning the patient with the Lodox x-ray system.

- Conduct initial patient triage.
- Maintenance of airway patency and ventilation.
- Provide resuscitation and stabilisation of severely injured patients.
- Transfer seriously injured patients to higher levels of care.
- Haemorrhagic control and sustenance of circulation.
- Intravenous fluid therapy.
- Administering intravenous fluids.

- Immobilisation on a spine board and application of cervical spine protection.
 - Connection of the patient to a monitor for vital sign surveillance.
 - Gathering information; mechanism of injury, patient history and time of injury.
15. Briefly indicate range or values for vital signs of an adult patient that need a referral for a full-body Lodox scan. i) Blood pressure (systole).
 16. Briefly indicate range or values for vital signs of an adult patient that need a referral for a full-body Lodox scan. ii) Respiration rate (RR).
 17. Briefly indicate range or values for vital signs of an adult patient that need a referral for a full-body Lodox scan. iii) GCS.
 18. Briefly indicate range or values for vital signs of an adult patient that need a referral for a full-body Lodox scan. iv) Heart (Pulse) rate.
 19. Briefly describe various ***clinical indications that guide a decision to refer a patient*** for full Lodox imaging.
 20. Rank these regional images in order of priority in the management of a patient at the emergency/trauma unit. Where 1 is the most important and 5 is the least important.
 - a) Chest x-rays.
 - b) Abdomen and pelvic x-rays.
 - c) Skull x-rays.
 - d) Extremities (lower and upper) x-rays.
 - e) Spine (Cervical, Thoracic, and Lumbar sacral spine image).
 21. Briefly indicate clinical indication (signs and symptoms) that would lead you to request Lodox imaging of this region on a polytrauma patient (*Skull Lodox imaging*).
 22. Briefly indicate clinical indication (signs and symptoms) that would lead you to request Lodox imaging of this region on a polytrauma patient (*Chest Lodox imaging*).
 23. Briefly indicate clinical indication (signs and symptoms) that would lead you to request Lodox imaging of this region on a polytrauma patient (*Abdomen and pelvic Lodox scan imaging*).
 24. Briefly indicate clinical indication (signs and symptoms) that would lead you to request

Lodox imaging of this region on a polytrauma patient (*Extremities (lower and upper limb Lodox imaging)*).

25. Briefly indicate clinical indication (signs and symptoms) that would lead you to request Lodox imaging of this region on a polytrauma patient (*cervical, thoracic, and lumbar-sacral spine Lodox imaging*).
26. If you obtain images of a diagnostic quality/value from a Lodox scan, would you still refer a patient for conventional chest x-ray imaging? (Yes / No)
27. If you obtain images of a diagnostic quality/value from Lodox scans, why would you still refer a patient for conventional chest x-ray imaging?
28. Why would you refer a patient for conventional x-rays after obtaining Lodox images of diagnostic value?
29. When would you refer a patient for an ultrasound scan without requesting a full-body Lodox scan?
30. When would you refer a patient for a CT scan without requesting a full-body Lodox scan?
31. After obtaining images of diagnostic value from a Lodox x-ray system, when would you refer a patient for a full-body CT scan? What would you like to see on those images?
32. After obtaining a full-body Lodox scan, a contrast-enhanced full-body CT scan may be requested in the following occasions/reasons for referral.
33. In case no CT imaging has been performed, but the patient has undergone Lodox chest imaging, what clinical indication can lead you to refer a patient for a chest ultrasound?

ANNEXURE K: ETHICS. APPROVAL FROM THE UNIVERSITY OF PRETORIA



Faculty of Health Sciences

Institution: The Research Ethics Committee, Faculty Health Sciences, University of Pretoria complies with ICH-GCP guidelines and has US Federal wide Assurance.

- FWA 00002567, Approved dd 22 May 2002 and Expires 03/20/2022.
- IORG #: IORG0001762 OMB No. 0990-0279 Approved for use through February 28, 2022 and Expires: 03/04/2023.

28 September 2020

Approval Certificate Amendment

Ethics Reference No.: 35/2019

Title: DEVELOPMENT OF AN ADULT CHEST IMAGING PROTOCOL FOR LODOX SYSTEMS AT TRAUMA UNITS IN SOUTH AFRICA

Dear Mr MJ Thambura

The **Amendment** as supported by documents received between 2020-08-21 and 2020-09-16 for your research, was approved by the Faculty of Health Sciences Research Ethics Committee on 2020-09-16 as resolved by its quorate meeting.

Please note the following about your ethics approval:

- Please remember to use your protocol number (35/2019) on any documents or correspondence with the Research Ethics Committee regarding your research.
- Please note that the Research Ethics Committee may ask further questions, seek additional information, require further modification, monitor the conduct of your research, or suspend or withdraw ethics approval.

Ethics approval is subject to the following:

- The ethics approval is conditional on the research being conducted as stipulated by the details of all documents submitted to the Committee. In the event that a further need arises to change who the investigators are, the methods or any other aspect, such changes must be submitted as an Amendment for approval by the Committee.

We wish you the best with your research.

Yours sincerely



Dr R Sommers

MBChB MMed (Int) MPharmMed PhD

Deputy Chairperson of the Faculty of Health Sciences Research Ethics Committee, University of Pretoria

The Faculty of Health Sciences Research Ethics Committee complies with the SA National Act 61 of 2003 as it pertains to health research and the United States Code of Federal Regulations Title 45 and 46. This committee abides by the ethical norms and principles for research, established by the Declaration of Helsinki, the South African Medical Research Council Guidelines as well as the Guidelines for Ethical Research: Principles Structures and Processes, Second Edition 2015 (Department of Health).

Research Ethics Committee
Room 4-80, Level 4, Tswelopele Building
University of Pretoria, Private Bag x323
Gezina 0031, South Africa
Tel +27 (0)12 356 3084
Email: deepika.behari@up.ac.za
www.up.ac.za

Fakulteit Gesondheidswetenskappe
Lefapha la Disaense eSa Maphelo

ANNEXURE L: DELPHI QUESTIONS ROUND 2.

CONFIRMATION OF REFERRAL PATHWAY (IMAGING PROTOCOL) GUIDELINES FOR USE ON A PATIENT UNDERGOING LODOX IMAGING

- 1 In previous research you had participated, it was suggested that the below activities be performed during the management of a trauma patient ***at a prehospital setting or within a hospital setting before sending patients for Lodox scanning.*** These activities have been arranged so that they are performed. **(Arrange the following statement such that the first action to be performed will be number one).**
 - Assess the patient's airway: Ensure the patient's airway is open by the maintenance of airway patency and remove a possible obstruction, do c-spine immobilisation, do simple airway manoeuvre and sanctions if necessary.
 - Assess the patient's breathing: Ensure the patient is breathing adequately. Check if there is adequate ventilation. Consider oxygen supply if necessary.
 - Assess the patient's circulation (pulse and bleeding); does the patient have an adequate pulse. Is there serious bleeding/loss of a large amount of blood? Perform haemorrhagic control and sustain blood circulation.
 - Perform rapid physical examination-Rapid physical examination/assessment (Head to toe) Head Neck Chest. Abdomen Pelvis Back Extremities of the entire body.
 - Immobilisation on a spine board and apply a cervical spine protection/collar neck if necessary.
 - Transfer seriously injured patients to higher levels of care for radiological investigation and further intervention.
 - Connect the patient to a monitor for vital sign surveillance while on the way to the hospital.
 - Detailed history informing mechanism of injury, observable injuries, and deaths on sites etc on the way to the hospital to be handed over with the patient at the hospital.

2 The following are clinical indications for a full-body Lodox scan or a regional dedicated Lodox scan. Drag and drop into the box on the right side the appropriate clinical indications.

- Polytrauma patients with suspected injuries at chest, abdomen pelvis and multiple fractures.
- The extremities.
- Ballistic injuries: Injuries caused on a body by the impact of a projectile object. This can be accelerated object or patient e.g., fell off a height, gunshot injuries, pellets, shrapnel, and arrowheads.
- Mechanism of injury; MVA, Motorcycle. Accident (MCA), PVA, mob assault, with multiple injuries and a death/s on the scene, collapsed building.
- Traumatic amputations of a limb, where an extremity or a section of the body has been cut off because of the accident or explosion.
- Forensic investigations; Suspected multiple non-accidental injuries with possible fractures. For example, assault, torture, custodian injuries, suicide attempt and ingested materials (drug smuggling).
- Mass fatalities where conventional x-ray system is in use/ x-rays machines are not available.
- Contrast-enhanced studies, intravascular administration of contrast media for evaluation of patency and vascular pathology where a single scan will show many regions at once.
- Routine follow-up of pulmonary diseases like Pulmonary. Tuberculosis, metastasis, screening of occupational disease and disorders.
- Routine follow-up on patency of prosthesis. E.g., breast implant, hip replacements, and knee replacement.
- Evaluation of stent, e.g., ventriculoperitoneal shunt dysfunction. Lodox would take a single image for multiple regions than a separate image taken using a conventional x-ray system.

- A skeletal radiological survey; for detection of focal or widespread abnormalities of the skeleton.
 - e.g., multiple myeloma, metastasis, congenital skeletal abnormalities in children, babygram on stillbirth. The Lodox uses a low radiation dose and therefore it is appropriate for the use in taking these images.
 - Congenital abnormalities of the spine e.g., spinal deformity e.g., kyphoscoliosis and lordosis, and scoliosis and limb length.
- 3 A medical practitioner (either a doctor or a nurse) that has examined the patient may refer a patient for a full-body Lodox scan or a regional dedicated Lodox scan if only the decision is supported by the rapid physical examination and after evaluation of Airway, Breathing, and Circulation (A, B Cs) of a patient. (Do you agree or disagree)?
- Agree.
 - Disagree.
- 4 Priority one (P1) and priority two (P2) trauma patients may undergo a full-body Lodox scan if only this decision is supported by the rapid physical examination and after evaluation of Airway, Breathing, and Circulation (A, B Cs) of a patient. (Do you agree or disagree).
- Agree.
 - Disagree.
- 5 Priority three (P3) trauma patients may undergo a regional dedicated Lodox scan of the injured regions or parts only if the decision is supported by the focused physical examination. The request can be described as that of a conventional x-ray. (Do you agree or disagree).
- Agree.
 - Disagree.
- 6 Among the list provided below, drag, and drop into the box on the right side the clinical indications that you will use in requesting an abdominopelvic Lodox scan. Drop inside this box.
- Blunt or penetrating trauma injury at the abdominopelvic region. I patient triage.

- Suspected fracture of the pelvis with associated abdominal tenderness.
 - Unstable pelvis, haematuria, and abdominal tenderness.
 - Tenderness on the abdominal and pelvis, unexplained blood loss, bruising or swelling of abdomen and pelvis regions.
 - Painful abdomen and pelvis, deformity limb length discrepancy, decreased range of movement at hips.
 - Abdominal distension, vomiting, constipation, or obstipation after a trauma.
- 7 Among the list provided below, drag, and drop into the box on the right side the clinical indications that you will use in requesting a Lodox x-ray for a limb/extremities (lower and upper limb images).
- Tenderness and deep lacerations.
 - Deep penetrating wounds.
 - Abnormal movement of the limb.
 - Limb length discrepancy.
 - Decreased movement of the joints.
 - Crepitation with limited movement.
 - Deformities of the extremities.
 - Amputation of the limb.
- 8 Among the list provided below, drag, and drop into the box on the right side the clinical indications that you will use in requesting a spine (cervical, thoracic, lumbar, and sacral) Lodox x-rays.
- The fallout of vertebral, and intervertebral disc spaces.
 - Prevertebral tenderness or swelling ration rate (RR).
 - Penetrating midline back injuries.
 - Distracting injuries of the spine.
 - Midline and paraspinal tenderness and swelling.

- Deformity Bogginess Splaying Sensory function fallout.
- Loss of motor function.
- Spinal tenderness and associated neurological shock.
- Spinal swelling with a limited range of movement.

9 Among the list provided below, drag, and drop into the box on the right side the clinical indications that you will use in requesting a chest Lodox scan.

- Any post-traumatic wounds on a chest.
- Blunt and penetrating injury.
- Any abnormal findings on cardiovascular or respiratory examination examinations.
- Chest pain, dyspnoea, tachypnoea.
- Use of accessory muscles in breathing.
- Paradoxical chest movement.
- Suspected aspiration.
- Blunt chest trauma, hypoxia, and penetrating chest trauma.
- Clinical features of Lower respiratory tract infection.
- Suspected metastasis.
- Fail chest, swelling and tenderness.

Identify clinical indications that you may refer for a CT scan without a need for a full-body Lodox scan.

- Suspected isolated injury.
- Suspected multiple injuries of internal structures that require rapid/urgent intervention.
- When multiple systems are involved e.g., cardiovascular, urinary system GIT and nervous system.

- 10 Identify clinical indications that you may refer a patient for a contrast-enhanced full-body CT scan after undergoing full-body Lodox imaging.
- When multiple systems are involved e.g., cardiovascular, urinary system GIT and nervous system.
 - To identify internal structure injuries that cannot be seen on a Lodox
Suspected head injury with altered mental status, comminuted fractures, chest, abdominal and pelvic viscera injuries.
 - After identification of multiple projectiles on Lodox images suggestive of vascular injury, or intra-abdominal injury.
- 11 Identify clinical indications that would suggest a request for a CT scan of the chest after Lodox imaging of a chest.
- Great vessels (angiography).
 - Detailed spine analysis if suspicious of spinal injury on chest x-ray.
 - Fractures of bones of the thoracic cage.
 - Pulmonary contusions.
 - Aortic dissection.
 - Oesophageal rupture.
 - Pericardial injuries.
 - Herniation.
 - The extent of the injuries was noted.
 - Pulmonary contusions.
 - Hemopneumothorax that might be missed on x-rays.
 - Condition of the tracheobronchial tree.
 - Vascular injuries like an aortic rupture.
 - Better soft tissue injury evaluation.
 - Mediastinal structures.
 - Pericardial effusion.

- Mediastinal injury delineation.
- Broncho-pleural fistula.
- Atelectasis /lung collapse.
- Fractures of the ribcage.
- Diaphragm injuries.
- Tracheobronchial injury.
- Widened mediastinum.
- Diaphragm injuries.
- Trachea and bronchial tree.
- Lung parenchymal injuries.

ANNEXURE M : DECLARATION OF PROFESSIONAL EDITING



Blue Diamonds Professional Editing Services (Pty) Ltd

Polishing your brilliance

Email: jacquibaumgardt@gmail.com

Website: www.jaybe9.wixsite.com/bluediamondsediting

2 February 2022

Declaration of professional editing

**DEVELOPMENT OF AN ADULT CHEST IMAGING PROTOCOL FOR LODOX SYSTEMS AT TRAUMA UNITS IN
SOUTH AFRICA
MUCHUI JULIUS THAMBURA**

I declare that I have edited and proofread this thesis. My involvement was restricted to language usage and spelling, completeness and consistency and referencing style. I did no structural re-writing of the content.

I am qualified to have done such editing, being in possession of a Bachelor's degree with a major in English, having taught English to matriculation, and having a Certificate in Copy Editing from the University of Cape Town. I have edited more than 300 Masters and Doctoral theses, as well as articles, books and reports.

As the copy editor, I am not responsible for detecting, or removing, passages in the document that closely resemble other texts and could thus be viewed as plagiarism. I am not accountable for any changes made to this document by the author or any other party subsequent to the date of this declaration. The academic content is the sole responsibility of the student.

Sincerely,

Dr J Baumgardt
UNISA: D. Ed. Education Management
University of Cape Town: Certificate in Copy Editing
University of Cape Town: Certificate in Corporate Coaching

Professional
EDITORS
Guild

Jacqui Baumgardt
Full Member

Membership number: BAU001
Membership year: March 2021 to February 2022

jaybee@telkomsa.net
<https://jaybe9.wixsite.com/bluediamondsediting>

www.editors.org.za

Blue Diamonds Professional Services (Pty) Ltd (Registration Number 2014/092365/07)
Sole Director: J Baumgardt