

Management of segmental bone defects of the upper limb: a scoping review with data synthesis to inform decision making

Nando Ferreira ^{1,*}, Aaron Kumar Saini ², Franz Friedrich Birkholtz ³, Maritz Laubscher ⁴

¹ Division of Orthopaedic Surgery, Department of Surgical Sciences, Faculty of Medicine and Health Sciences, Stellenbosch University, Cape Town, 7505, South Africa. nferreira@sun.ac.za.

² Division of Orthopaedic Surgery, Department of Surgical Sciences, Faculty of Medicine and Health Sciences, Stellenbosch University, Cape Town, 7505, South Africa.

³ Walk-A-Mile Centre and Department of Orthopaedics, University of Pretoria, Pretoria, 0002, South Africa.

⁴ Orthopaedic Research Unit (ORU), Division of Orthopaedic Surgery, Department of Surgery, University of Cape Town, Cape Town, 7505, South Africa.

*Correspondence to Nando Ferreira. Email: nferreira@sun.ac.za

Abstract

Purpose: Injuries to the long bones of the upper limb resulting in bone defects are rare but potentially devastating. Literature on the management of these injuries is limited to case reports and small case series. The aim of this study was to collate the most recent published work on the management of upper limb bone defects to assist with evidence based management when confronted with these cases.

Methods: Following a preliminary search that confirmed the paucity of literature and lack of comparative trials, a scoping review using the Preferred Reporting Items for Systematic Reviews and Meta-Analysis extension for Scoping Reviews (PRISMA-ScR) was conducted. A literature search of major electronic databases was conducted to identify journal articles relating to the management of upper limb long bone defects published between 2010 and 2020.

Results: A total of 46 publications reporting on the management of 341 patients were reviewed. Structural autograft, bone transport, one-bone forearm and the induced membrane technique were employed in an almost equal number of cases. The implemented strategies showed similar outcomes but different indications and complication profiles were observed.

Conclusion: Contemporary techniques for the management of post-traumatic upper limb bone defects all produce good results. Specific advantages, disadvantages and complications for each modality should be considered when deciding on which management strategy to employ for each specific patient, anatomical location, and defect size.

Keywords: Bone defect; Bone transport; Humerus; Induced membrane; Radius; Ulna; Upper limb; Vascularized fibula graft.

Introduction

The optimal strategy for the management of critical sized bone defects of the long bones of the upper limb remains unclear [1]. These cases harbor significant morbidity for the patient and requires meticulous planning, understanding of bone biology and fixation mechanics on the part of the treating physician. This may be even more critical in the case of bilateral injuries or contralateral amputation.

Although less frequent than lower extremity bone defects, upper limb defects can be demanding to manage, as reconstruction must be attained while maintaining adjacent joint motion and hand dexterity to preserve function [2]. There is no single solution to all upper limb bone defects and one needs to individualise treatment from a variety of reconstructive options. Despite the immense challenges these defects pose, literature on their management and outcome is limited to case studies and small series.

In this current concepts scoping review we explored the literature reporting on the management of upper limb bone defects and interpreted the data to provide physicians with up to date evidence upon which to base their management when confronted with these complex cases.

Methods

A preliminary search confirmed the paucity of literature and lack of comparative trials on the topic. For this reason, a scoping review was undertaken according to the Preferred Reporting Items for Systematic Reviews and Meta-Analysis extension for Scoping Reviews (PRISMA-ScR) statement.

Literature search strategy

The literature review focused on the period January 2010–November 2020 to ascertain the most recent management strategies employed by orthopaedic reconstruction surgeons. The literature search of electronic databases was conducted for English language publications, and included Google Scholar, Medline and the central registrar of controlled trials in the Cochrane library. The search terms included “Bone defect, Upper limb, Humerus, Radius, Ulna”, with the Boolean terms “AND” and “OR”. During initial screening and identification, article titles and abstracts were reviewed for relevance. A three-step method was followed to identify articles that were included in this review. Two independent authors reviewed all titles, abstracts and the full articles, which were obtained for all potentially suitable publications. Following this, a secondary similar identification and screening process identified potentially suitable studies from the reference lists of full text articles identified in the initial phase. All the identified articles were then appraised according to specific inclusion criteria. Only publications dealing with post-traumatic bone defects and defects resulting from post-traumatic sequelae involving human participants were considered for inclusion.

Eligibility criteria and assessment

All publications dealing with post-traumatic bone defects and defects resulting from post-traumatic sequelae involving human participants were considered for inclusion. Inclusion and exclusion criteria are shown in Table 1. Papers that didn't provide enough information to allow subgroup analysis were excluded. Any disagreement was resolved by discussion

between the authors. Where consensus could not be reached, a third adjudicator acted as an arbitrator.

Table 1 Inclusion and exclusion criteria

Inclusion criteria	Exclusion criteria
Upper limb bone defect	Post oncological resection defects
Post-traumatic and post osteomyelitis debridement defects	Animal studies
All management strategies	Review articles
	Congress proceedings
	Publications not subject to peer review

Data extraction and analysis

The specific study design, sample size, location, aetiology and size of the bone defect as well as the outcome and complications of the management strategy employed for each identified article was reviewed. Data synthesis involved pooling related cases into anatomical location and treatment strategy groups to ascertain outcomes for each clinical scenario and reconstructive modality.

Results

The initial search identified 829 publications. Initial screening and secondary identification identified 57 potentially relevant studies. Full text review of these 57 studies resulted in 46 publications being retained for final review (Fig. 1).

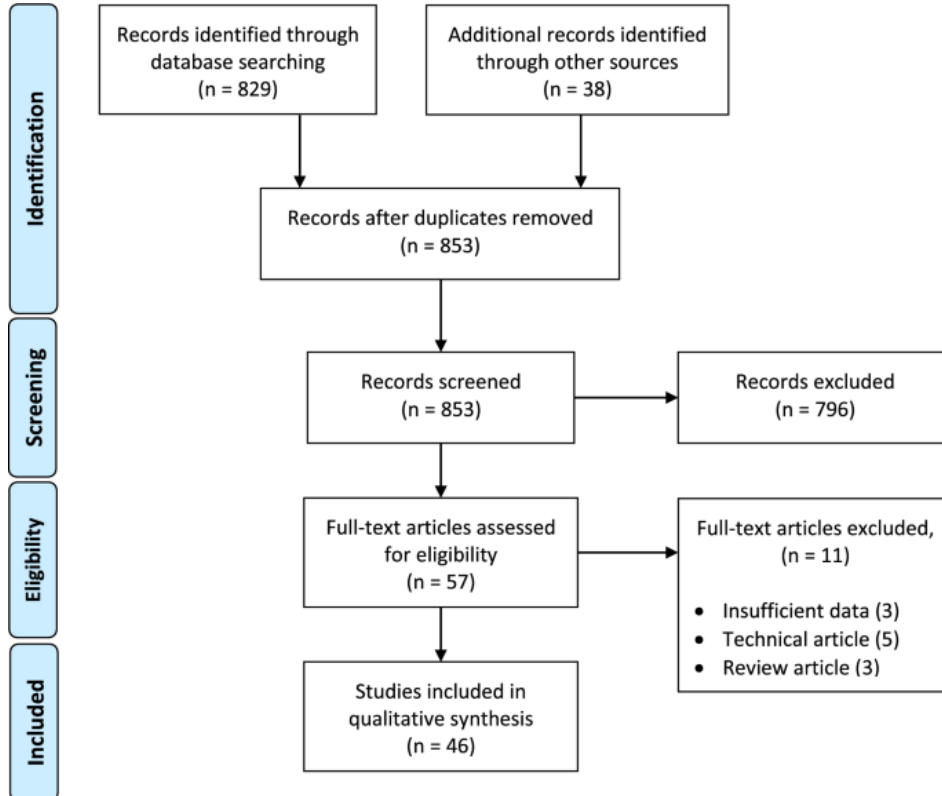


Fig. 1. Flow diagram showing identification and selection of studies

Study characteristics

All included publications were case reports or case series with no comparative studies available for review. Publications were assigned a level of evidence according to Sackett's rule of evidence that rank studies according to the probability of bias leading to a final count of 31 level four and 15 level five studies (Supplementary table) [3].

Study sample sizes ranged from one to 36 cases and included a total of 341 patients with upper limb bone defects (Table 2). The majority of bone defects occurred in forearm bones ($n = 289$, 85%) and were predominantly the result of chronic osteomyelitis debridement ($n = 172$, 50%). The five main treatment strategies were the induced membrane technique ($n = 96$), structural autograft ($n = 89$), bone transport ($n = 82$), one-bone forearm reconstruction ($n = 72$) and titanium mesh cages ($n = 2$). A wide variety of fixation methods were employed across the included studies and are presented in Table 2.

Table 2 Summary of all included cases

	Induced membrane technique [4–20]	Structural auto-graft [21–32]	Bone transport [33–43]	One-bone forearm [44–47]	Titanium cage [48]	Total
Publications (<i>n</i>)	17	13	11	4	1	46
Patients (<i>n</i>)	96	89	82	72	2	341
Limb Segment (<i>n</i> , %)						
Radius or Ulna	64 (64%)	43 (48%)	76 (93%)	0 (0%)	1 (50%)	184 (54%)
Both bone forearm	13 (16%)	14 (16%)	6 (7%)	72(100%)	0 (0%)	105 (31%)
Humerus	19 (20%)	32 (36%)	0 (0%)	0 (0%)	1 (50%)	52 (15%)
Indications (<i>n</i> , %)						
Acute trauma	26 (27%)	15 (17%)	0 (0%)	52 (72%)	2 (100%)	95 (28%)
Non-union	7 (7%)	23 (26%)	10 (12%)	16 (22%)	0 (0%)	56 (16%)
Osteomyelitis	63 (66%)	33 (37%)	72 (88%)	4 (6%)	0 (0%)	172 (50%)
Not reported	0 (0%)	18 (20%)	0 (0%)	0 (0%)	0 (0%)	18 (5%)
Fixation method (<i>n</i> , %)						
Plate	84 (88%)	82 (92%)	0 (0%)	16 (22%)	2 (100%)	184 (54%)
External fixation	8 (8%)	0 (0%)	82 (100%)	1 (1%)	0 (0%)	81 (24%)
Nail	3 (3%)	0 (0%)	0 (0%)	1 (1%)	0 (0%)	4 (1%)
K-wire	0 (0%)	7 (8%)	0 (0%)	0 (0%)	0 (0%)	7 (2%)
None	1 (1%)	0 (0%)	0 (0%)	0 (0%)	0 (0%)	1 (0.3%)
Not reported	–	–	–	54 (75%)	–	54 (16%)
Number of surgeries to obtain union (<i>n</i> , range)	2.6 (2–6)	1.1 (1–2)	1.7 (1–3)	1.5 (1–6)	1 (1–1)	
Time to union (months)	7.4 (4–6)	3.5 (3–5)	5.7 (4–7)	NR	NR	
Complications (<i>n</i> , %)						
Delayed union	1 (1%)	4 (4%)	–	–	–	
Non-union	2 (2%)	6 (7%)	7 (10%)	10 (14%)	–	
Infection	6 (6%)	4 (4%)	3 (4%)	6 (8%)	–	
Pin site infection	–	–	22 (26%)	–	–	
Graft fracture	–	1 (1%)	–	2 (3%)	–	

Data is presented as counts with frequencies indicated in parentheses. NR, not reported

Induced membrane technique

The induced membrane technique was the most frequent reconstruction strategy employed across all included papers. Seventeen publications, comprising 96 patients (30%), reported on the use of this modality [4,5,6,7,8,9,10,11,12,13,14,15,16,17,18,19,20]. The majority of cases ($n = 63$, 66%) were post-osteomyelitis bone defects and stability was conferred using plate

fixation in most cases ($n = 84$, 88%). The number of surgeries to obtain union (mean = 2.6) was consistently more than any other modality.

Structural autograft

Fibula autograft was the only structural autograft used in included literature [19, 21,22,23,24,25,26,27,28,29,30, 32, 49]. Eleven publications comprising 65 patients (73%) reported on the use of vascularized fibula autograft [21,22,23,24,25,26,27,28, 30, 31, 49]. All cases employed the use of a single vascularized fibula graft and no double barrel or Capanna type grafts were used. In 29 cases (44%), all involving the forearm, a vascularized osteoseptocutaneous flap was used for composite defects [19, 21,22,23,24,25,26,27,28, 31]. Two publications comprising 24 patients (27%) used non-vascularized fibula autograft, all for reconstructing humeral bone defects [20, 32]. The majority of cases ($n = 82$, 92%) underwent internal fixation with plates and screws while intramedullary k-wire fixation was used in seven patients (8%). Structural autografts showed the shortest healing time and lowest number of surgeries required to obtain final union compared to the other modalities.

Bone transport

Eleven publications reported on the use of bone transport to reconstruct 82 forearm bone defects [33,34,35,36,37,38,39,40,41,42,43]. The majority of cases ($n = 76$, 91%) were performed for defects post-osteomyelitis debridement and all cases used external fixation for stabilization. One article by Demir et al. reported their results of five patients who underwent forearm transport with an external fixator-based bone transport pulley system, similar to a cable transport apparatus [33, 50]. Bone transport showed the highest complication rate of all reconstruction modalities although most of these (22/36, 61%) were superficial pin site infections.

One-bone forearm

One-bone forearm reconstruction involving radialisation of the ulna was used for 72 patients across four publications [44,45,46,47]. High energy trauma was the main indication ($n = 52$, 72%) and was generally associated with significant soft tissue defects. Two publications specifically focussed on the complications encountered with this technique with non-union ($n = 10$, 14%) and infection ($n = 8$, 6%) being the most common [46, 47].

Titanium mesh cage

A single publication reported on the use of titanium cages for the reconstruction of a single radius and humerus defect respectively [48]. In both instances the cage was filled with autogenous bone graft using the Reamer Irrigator Aspirator (RIA; DePuy-Synthes, Warsaw, Indiana, USA) system and fixed with a plate. In both cases the defect healed uneventfully.

Forearm single-bone defects (Radius or ulna defects)

A total of 184 individuals across 31 publications underwent reconstruction of a defect of a single forearm bone [4, 6, 8,9,10,11, 14, 16,17,18,19,20,21,22, 25, 26, 28, 31, 33, 35, 36, 38,39,40,41,42,43, 48] (Table 3). Bone transport and the induced membrane technique were employed to reconstruct defects with mean sizes of 44.3 mm and 46.8 mm respectively. In contrast, vascularized fibula grafts were used for larger defects with a mean of 80 mm.

Table 3 Radius or Ulna bone defects

	Bone transport [33, 35, 36, 38–43]	Induced membrane Technique [4, 6, 8–11, 13, 14, 16–20]	Structural autograft [21–26, 28, 31]	Titanium cage [48]
Number of patients (n, %)	76 (41%)	64 (35%)	43 (23%)	1 (0.5%)
Age (years)	32.1 (10–62)	39 (11–78)	35.2 (3–90)	17
Defect size (mm)	44.3 (10–90)	46.8 (17–110)	80 (18–110)	70
Aetiology of defect (n, %)				
Acute Trauma	0 (0%)	18 (28%)	10 (23%)	1 (100%)
Non-union	10 (13%)	2 (3%)	1 (2%)	0 (0%)
Osteomyelitis	66 (87%)	44 (69%)	19 (44%)	0 (0%)
Not reported	0 (0%)	0 (0%)	13 (30%)	0 (0%)
Number of surgeries to obtain union	1.6 (1–3)	2 (2–6)	1.2 (1–2)	1 (1–1)
Time to Union (months)	5.7 (2.5–10)	5.4 (2.5–22)	4.2 (2.5–12)	NR
Complications (n, %)				
Delayed union	–	1 (2%)	4 (9%)	–
Non-union	9 (12%)	1 (2%)	4 (9%)	–
Infection	3 (4%)	5 (8%)	1 (2%)	–
Pin site infection	20 (26%)	–	–	–

Data is presented as median (interquartile range) or as counts with frequencies indicated in parentheses. NR, not reported

Forearm both-bone defects (Radius and ulna defects)

Sixteen publications reported on the management of 105 combined radius and ulna defects [7, 11, 19, 20, 22, 25, 27, 28, 34, 37, 38, 42, 44, 45, 46, 47] (Table 4). After the one-bone forearm technique, structural autograft in the form of vascularized grafts were used in the majority of cases ($n = 14$, 42%). This modality was used for the largest defects (mean = 70 mm), required the fewest surgeries (median = 1.6), had the shortest healing time (median = 3.5 months) and lowest complication rate [22, 25, 27, 28].

Table 4 Forearm both bone defects

	One-bone forearm [44–47]	Structural autograft [22, 25, 27, 28]	Induced membrane technique [7, 11, 19, 20]	Bone transport [34, 37, 38, 42]
Number of patients (n, %)	72 (69%)	14 (13%)	13 (12%)	6 (6%)
Age (years)	37 (6–70)	34.1 (8–56)	52 (29–73)	31.7 (23–43)
Defect size (mm)	NR	70 (40–70)	40.1 (20–100)	33.5 (10–80)
Aetiology of defect (n, %)				
Acute Trauma	52 (72%)	5 (36%)	5 (36%)	0 (0%)
Non-union	16 (22%)	0 (0%)	0 (0%)	0 (0%)
Osteomyelitis	4 (6%)	7 (50%)	8 (64%)	6 (100%)
Not reported	0 (0%)	2 (14%)	0 (0%)	0 (0%)
Number of surgeries to obtain union	1.5 (1–6)	1.6 (1–2)	2.8 (2–6)	2.3 (1–3)
Time to Union (months)	NR	3.5 (2.5–5.5)	4.1 (2–6)	6.3 (4–13.5)
Limb length discrepancy (mm)	64 (0–150)	NR	NR	NR
Complications (n, %)				
Delayed union	–	–	–	–
Non-union	10 (14%)	1 (7%)	–	1 (17%)
Infection	6 (8%)	–	1 (9%)	–
Pin site infection	–	–	–	2 (33%)
Graft fracture	2 (3%)	–	–	–

Data is presented as median (interquartile range) or as counts with frequencies indicated in parentheses. NR, not reported

Humeral defects

Twelve publications reported on the management of 52 humeral shaft defects [5, 6, 9, 11, 12, 15, 20, 25, 32, 48, 49] (Table 5). No authors reported the use of bone transport to reconstruct

humeral defects, opting rather for the induced membrane technique and fibula grafts. Structural autograft (24 non-vascularized and 8 vascularized fibulas) was used for predominantly non-union cases ($n = 22$) while the induced membrane technique were mostly used for post-osteomyelitis cases ($n = 11$). Bone defect size (55.2 mm vs 71 mm) and time to union (5 months vs 4.1 months) was similar in these groups, however the induced membrane technique on average required three times more surgical procedures to achieve union. All five complications in the structural autograft group occurred in non-vascularized fibula autograft cases. No articles during the study period reported on humeral shortening as a technique to manage humeral bone defects.

Table 5 Humerus bone defects

	Induced membrane technique [5, 6, 9, 11, 12, 15, 20]	Structural autograft		Titanium cage [48]
		Non-vascularized [29, 32]	Vascularized [25, 49]	
Number of patients ($n, \%$)	19 (37%)	24 (46%)	8 (15%)	1 (2%)
Age (years)	38 (13–69)	40.1 (26–59)	58 (45–65)	19
Defect size (mm)	55.2 (20–125)	80 (12–150)	45 (10–100)	80
Aetiology of defect ($n, \%$)				
Acute Trauma	3 (16%)	0 (0%)	0 (0%)	1 (100%)
Non-union	5 (26%)	17 (71%)	5 (69%)	0 (0%)
Osteomyelitis	11 (58%)	7 (29%)	0 (0%)	0 (0%)
Not reported	0 (0%)	0 (0%)	3 (9%)	0 (0%)
Number of surgeries to obtain union	3.0 (2–6)	1.0 (1–2)	1 (1–1)	1
Time to Union (months)	5 (5–10.6)	4.1 (3–5.4)	4.3 (3–5)	NR
Complications ($n, \%$)				
Delayed union	–	–	–	–
Non-union	1 (5%)	–	–	–
Infection	–	3 (13%)	–	–
Pin site infection	–	–	–	–
Graft fracture	–	2 (8%)	–	–

Data is presented as median (interquartile range) or as counts with frequencies indicated in parentheses. NR, not reported

Discussion

Numerous contemporary strategies exist to reconstruct post-traumatic upper limb bone defects. These include acute or gradual shortening, with or without subsequent lengthening, vascularized fibula graft reconstruction, Masquelet’s induced membrane technique, bone transport, and customised intercalary titanium mesh cage reconstruction. The ultimate choice of one modality over another has predominantly been steered by expert opinion and personal preference rather than evidence. The aim of this paper was to review the current treatment options and outcomes for the management of upper limb segmental bone defects in an attempt to inform decision making when dealing with these complex cases.

Shortening with or without subsequent lengthening

Despite no publications describing acute shortening identified within the search period, this option remains a frequently employed strategy for humeral fractures with segmental comminution or small defects [51] (Fig. 2). The limits of acute shortening have not been confirmed in the literature but absolute figures of < 50 mm and $< 14\%$ of the original length have been suggested [51,52,53]. Although the humerus can be lengthened through distraction osteogenesis, most patients do not complain of functional or cosmetic deficit and it is usually thus not required [54,55,56,57]. Although not specifically reported in the literature under

review, the improved biological activity obtained through distraction osteogenesis may also be useful in improving healing at the compression site [58].

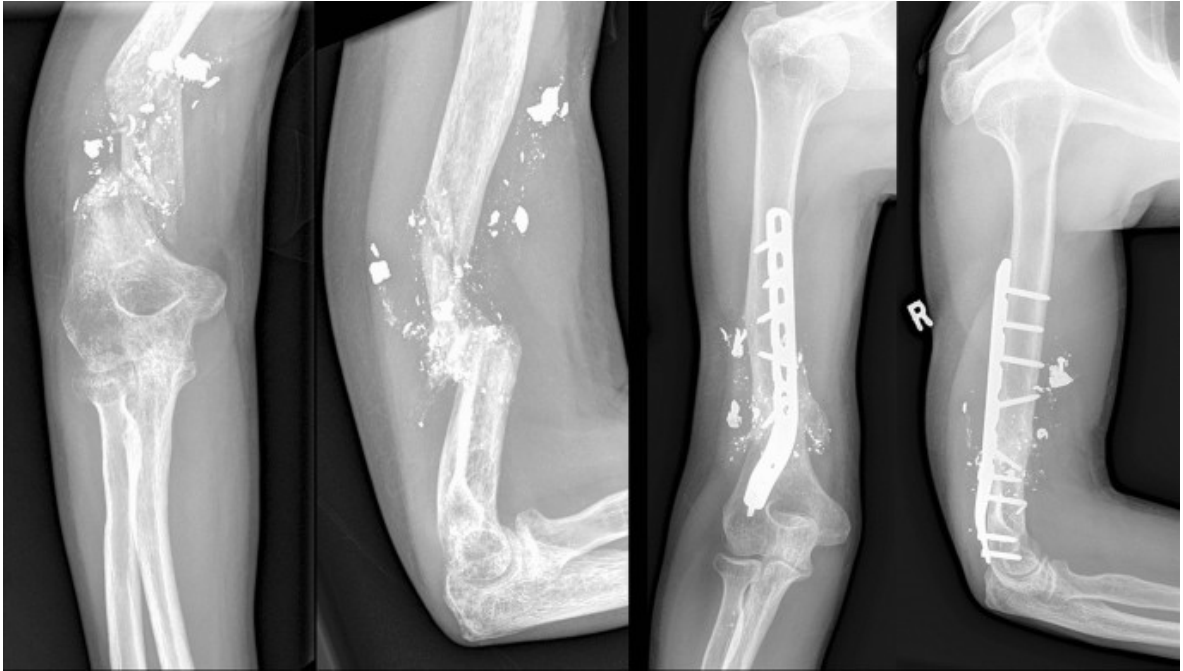


Fig 2. Case example of a 50 mm ulna bone defect treated by monolateral external fixator bone transport

Acute shortening of forearm deficits is technically possible and limited reports have demonstrated minimal impaired function [59, 60]. This strategy is however often difficult to apply, given the curved geometry of the radius which makes simple longitudinal shortening difficult and the fact that radius and ulna must be shortened equally to maintain appropriate rotation and forearm function.

Masquelet's induced membrane technique

The induced membrane technique was originally proposed by Masquelet et al. and entails a staged approach to bone defect reconstruction [61, 62]. The first stage relies on a polymethyl methacrylate (PMMA) cement spacer being inserted into post-debridement bone defects [20, 63] (Fig. 3). The major advantage of this approach is the ability to use a physician-directed antibiotic loaded spacer for dead space management of post-infective defects [64]. This was also demonstrated in the current review where the induced membrane technique was predominantly used in the management of post-infective bone defects and only showed a recurrence of infection rate of 6%.

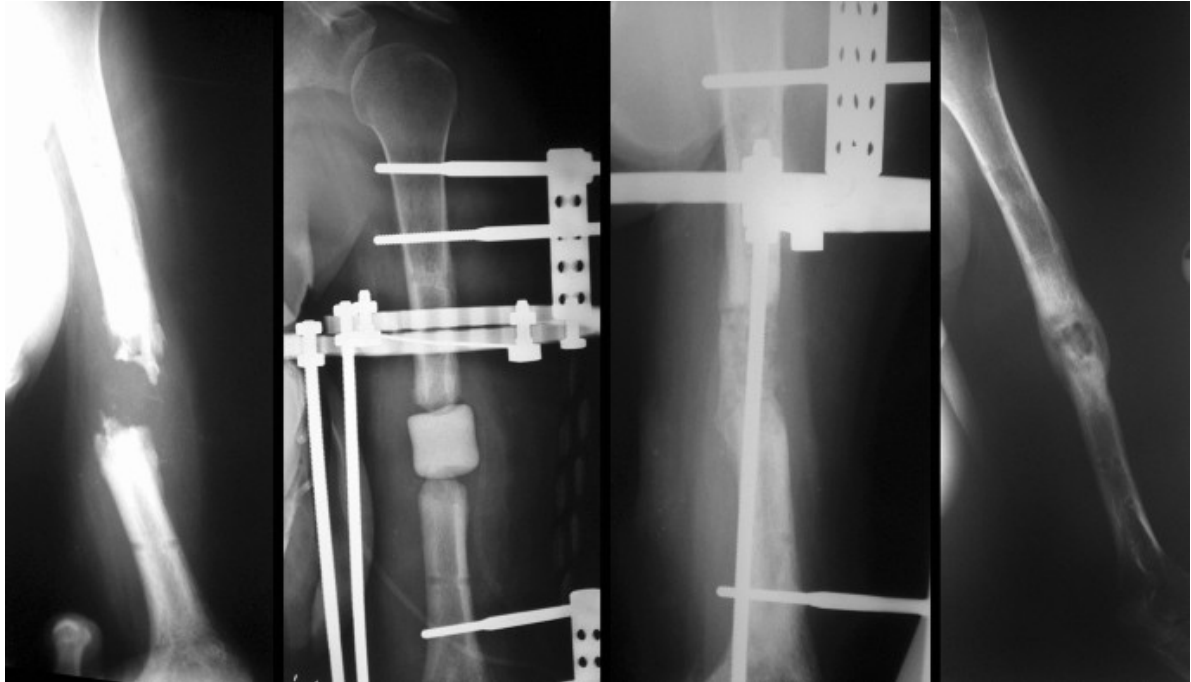


Fig. 3. Case example of a 35 mm infected humeral bone defect treated by circular external fixation and an induced membrane technique with iliac crest bone graft

The second stage is undertaken around 4–6 weeks after the first, and consists of autologous bone graft being inserted into the induced membrane chamber that is created following removal of the cement spacer [20, 63]. Obtaining an adequate volume of autograft is less of a problem with upper limb defects compared to the lower given the relatively smaller size. Modern harvesting techniques like the RIA system (DePuy-Synthes, Warsaw, Indiana, USA) have gained popularity in recent years and aid the process [5, 15, 16, 20].

One of the drawbacks that have been identified with this technique is the often multiple repeat bone grafting procedures required due to graft reabsorption [65, 66]. This is borne out by the fact that, when compared to other strategies, the induced membrane technique required almost twice as many surgeries, and in some instances up to five re-grafting operations, to achieve union.

Structural autograft

Non-vascularized structural autograft was only employed for humeral defects in the current review and showed the highest complication rate (13% infection and 8% fracture) of all reconstructive strategies. Similarly, a 1997 study reported on the use of tricortical bone block allograft to reconstruct radius and ulna bone defects and showed high complication rates including delayed healing, graft resorption and infection [67] (Fig. 4). In comparison, vascularized grafts showed a 8% non-union rate and only 1 of the 65 grafts (2%) became infected.

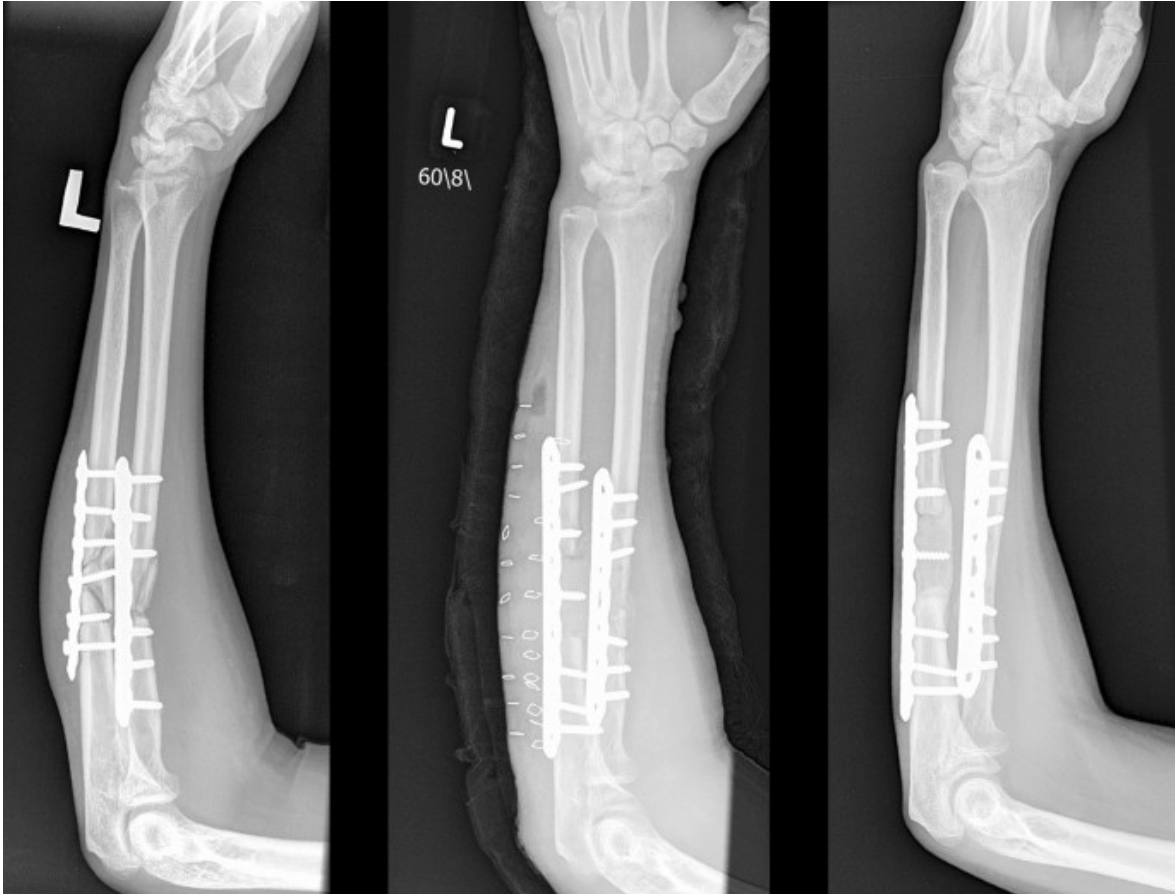


Fig. 4. Case example of an infected non-union of the ulna managed by resection of 25 mm bone and reconstruction with a tricortical iliac crest bone block

High complication rates and better outcomes with bone transport in adult lower limb defects, have relegated the use of vascularized fibula grafts to the upper limb in adults [68, 69]. Despite the technical expertise required to perform vascularized grafts, their value is manifest by the ability to incorporate a cutaneous island to reconstruct combined bone and skin loss [70]. In this review, half of the cases (48%) that were reconstructed with a vascularized graft included a cutaneous paddle for concomitant soft tissue reconstruction [19, 21, 22, 25,26,27,28, 31]. An additional benefit to an osteocutaneous flap is the fact that cutaneous viability can serve as a sentinel for bone viability within the flap [71].

Bone transport

Multiple reports have shown the reliability of bone transport in reconstructing radius or ulna defects [33, 36, 38,39,40,41,42,43] (Fig. 5). This technique can also be combined with a first stage Masquelet followed by bone transport through the induced membrane. This benefits from the dead space management conferred by the antibiotic-loaded cement spacer after osteomyelitis debridement [72]. Although predominantly used for forearm single bone defects in the current review, four publications reported on its application for both bone forearm reconstruction [34, 37, 38, 42]. Birkholtz et al. emphasised the independent transport of the radius and ulna with two monolateral rails to maintain forearm function throughout the reconstructive process [34]. When performing this type of reconstruction some tips and tricks

are useful to remember: cement spacer induced membranes prior to bone transport are useful in providing a biological envelope for transport, but also prevent synostosis formation; The rail fixator is lined up to the desired pathway of new bone generation, ensuring the regenerate shape mimics the original anatomical shape of the forearm bone; Distraction rate is slowed down, due to the small surface area of the osteotomy site; Formal open docking is indicated, with bone grafting of the docking site; Rehabilitation focus throughout the treatment phase emphasizes active and passive pro- and supination.

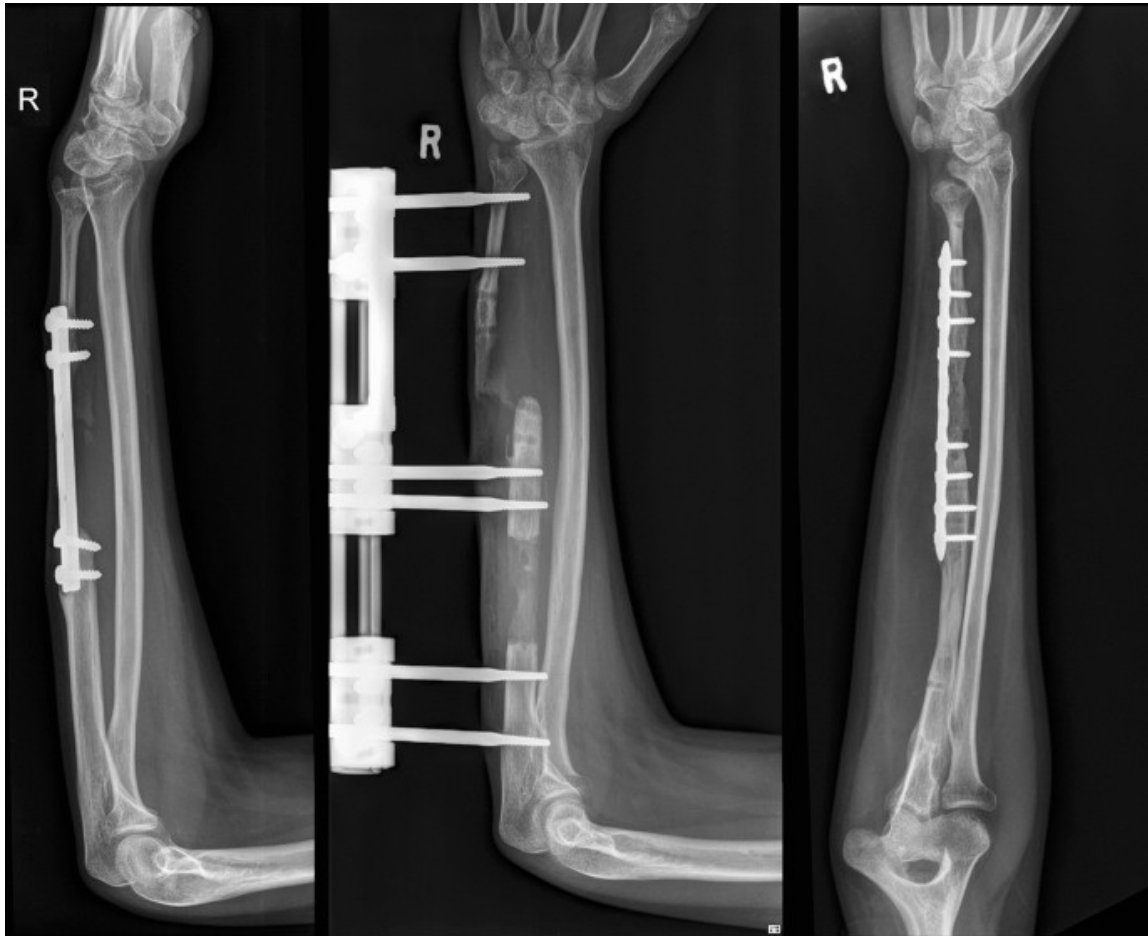


Fig. 5. Case example of a 40 mm ulna bone defect treated by monolateral bone transport followed by internal fixation after docking

One-bone forearm

One-bone forearm reconstruction is generally reserved for salvage procedures following major trauma and tumour resections. Limb length discrepancy and loss of forearm rotation impacts functional outcome but this may be preferable in terms of function, cosmesis, and patient preference compared with amputation. The ideal position of forearm rotation is controversial with recommendations varying from 0° to 45° supination [46, 47, 73]. Devendra et al. used fusion positions of full supination for the dominant hand and 10° pronation for the non-dominant hand to assist with eating and personal hygiene respectively, although this report is from the Indian subcontinent and could be culturally driven [44].

Titanium mesh cage

Additive manufacturing techniques has seen huge technological advancement in recent years [74, 75]. Computer software, printer technology, and advances in materials have provided surgeons the opportunity to rapidly produce relatively inexpensive custom solutions for patients. Recently this technology has been applied to the management of extra-articular segmental long bone defects [48, 76, 77]. Although most literature focusses on the reconstruction of lower limb defects, Attias et al. reported good results following the reconstruction of an 80 mm humeral bone defect and 70 mm radius defect with a combination of a titanium mesh cage, RIA bone graft and plate fixation [76, 78].

The recommendations that can be extracted from this study are limited by the paucity and quality of publications; all of the included reports being either retrospective case series or case reports. The heterogeneity and quality of the included studies precluded performing a meta-analysis. This review also focused on the results of bony reconstruction which do not necessarily reflect functional outcome. Data on patient reported outcome measures is also lacking. We implore orthopaedic trauma and reconstructive surgeons to publish their treatment strategies and outcomes for managing long bone defects of the upper limb, We appreciate that prospective research or trials in the condition are difficult given the relatively low numbers and heterogeneity of injuries, as well as skill set and experience of treating surgeons.

Conclusion

Contemporary techniques for the management of post-traumatic upper limb long bone defects all produce good results. The specific advantages, disadvantages and complications for each modality should be considered when deciding on which management strategy to employ for each specific patient, anatomical location, and defect size.

Ethics declarations

Conflict of interest

The authors declare that they have no conflict of interest.

Ethical approval

The authors declare that this submission is in accordance with the principles laid down by the Responsible Research Publication Position Statements as developed at the 2nd World Conference on Research Integrity in Singapore, 2010.

References

1. Gan AWT, Puhaindran ME, Pho RWH (2013) The reconstruction of large bone defects in the upper limb. *Injury* 44(3):313–317.
<https://doi.org/10.1016/j.injury.2013.01.014>
2. Hu W, Le Nen D, Kerfant N et al (2020) Management of complex forearm defects: a multidisciplinary approach. *Ann Chir Plast Esthétique* 65(5–6):625–634.
<https://doi.org/10.1016/j.anplas.2020.06.011>

3. Sackett DL (1993) Rules of evidence and clinical recommendations for the management of patients. *Can J Cardiol* 9(6):487–489.
<https://www.ncbi.nlm.nih.gov/pubmed/8221340>
4. Suranigi S, Babu A, Pandian S, Ramdas A, Najimudeen S (2017) Application of the induced membrane technique for treatment of diaphyseal bone defect secondary to osteomyelitis of ulna: a modified approach. *J Curr Res Sci Med* 3(2):125.
https://doi.org/10.4103/jcrsm.jcrsm_59_17
5. Litvina EA, Semenisty AA (2020) A case report of extensive segmental defect of the humerus treated with Masquelet technique. *J Shoulder Elb Surg* 29(7):1368–1374.
<https://doi.org/10.1016/j.jse.2020.03.018>
6. Allende C (2010) Cement spacers with antibiotics for the treatment of posttraumatic infected nonunions and bone defects of the upper extremity. In: *Techniques in hand and upper extremity surgery*. <https://doi.org/10.1097/BTH.0b013e3181f42bd3>
7. Kawakami R, Konno S-I, Ejiri S, Hatashita S (2015) Surgical treatment for infected long bone defects after limb-threatening trauma: application of locked plate and autogenous cancellous bone graft. *Fukushima J Med Sci* 61(2):141–148.
<https://doi.org/10.5387/fms.2015-17>
8. Kyriakopoulos C, Trintafyllopoulos I, Kostakos T, Kostakos A (2016) Implementation of the Masquelet technique in complicated septic non-union of the Ulna—a case report. *J Pharm Pharmacol*. <https://doi.org/10.17265/2328-2150/2016.07.002>
9. Masquelet AC, Kishi T, Benko PE (2019) Very long-term results of post-traumatic bone defect reconstruction by the induced membrane technique. *Orthop Traumatol Surg Res* 105(1):159–166. <https://doi.org/10.1016/j.otsr.2018.11.012>
10. Micev AJ, Kalainov DM, Soneru AP (2015) Masquelet technique for treatment of segmental bone loss in the upper extremity. *J Hand Surg Am* 40(3):593–598.
<https://doi.org/10.1016/j.jhssa.2014.12.007>
11. Anoumou NM, Traoré M, Kouamé M, Yepié A, Varango G (2017) Preliminary results of the induced membrane in upper limb. About 6 cases. *Hand Surg Rehabil* 36(1):53–57. <https://doi.org/10.1016/j.hansur.2016.07.007>
12. Kombate NK, Walla A, Ayouba G et al (2017) Reconstruction of traumatic bone loss using the induced membrane technique: preliminary results about 11 cases. *J Orthop* 14(4):489–494. <https://doi.org/10.1016/j.jor.2017.06.009>
13. Bourgeois M, Loisel F, Bertrand D et al (2020) Management of forearm bone loss with induced membrane technique. *Hand Surg Rehabil* 39(3):171–177.
<https://doi.org/10.1016/j.hansur.2020.02.002>
14. Walker M, Sharareh B, Mitchell SA (2019) Masquelet reconstruction for posttraumatic segmental bone defects in the forearm. *J Hand Surg Am* 44(4):342.e1-342.e8. <https://doi.org/10.1016/j.jhssa.2018.07.003>
15. Gaillard J, Masquelet AC, Boutroux P, Cambon-Binder A (2020) Induced-membrane treatment of refractory humeral non-union with or without bone defect. *Orthop Traumatol Surg Res* 106(5):803–811. <https://doi.org/10.1016/j.otsr.2020.02.015>
16. Hanna W, Mueller CA (2013) RIA grafting for the treatment of a large bone defect in the distal radius—first case report of a new treatment option. *Inj Extra* 44(2):19–22.
<https://doi.org/10.1016/j.injury.2012.10.006>
17. Dhar SA, Dar TA, Mir NA (2019) Management of infected nonunion of the forearm by the Masquelet technique. *Strateg Trauma Limb Reconstr* 14(1):1–5.
<https://doi.org/10.5005/jp-journals-10080-1411>
18. Bech N, Kloen P (2020) Recalcitrant Septic Nonunion of the Ulna. *Cureus*.
<https://doi.org/10.7759/cureus.7195>

19. Luo TD, Nunez FA, Lomer AA, Nunez FA (2017) Management of recalcitrant osteomyelitis and segmental bone loss of the forearm with the Masquelet technique. *J Hand Surg Eur* 42(6):640–642. <https://doi.org/10.1177/1753193416650171>
20. Giannoudis PV, Harwood PJ, Tosounidis T, Kanakaris NK (2016) Restoration of long bone defects treated with the induced membrane technique: protocol and outcomes. *Injury* 47:S53–S61. [https://doi.org/10.1016/S0020-1383\(16\)30840-3](https://doi.org/10.1016/S0020-1383(16)30840-3)
21. Vicenti G, Maruccia M, Carrozzo M, Elia R, Giudice G, Moretti B (2018) Free vascularized osteoseptocutaneous fibular flap for radius shaft nonunion: The final solution when the iliac crest autograft fails. A case report. *Injury* 49:S63–S70. <https://doi.org/10.1016/j.injury.2018.11.030>
22. Noaman HH (2013) Management of upper limb bone defects using free vascularized osteoseptocutaneous fibular bone graft. *Ann Plast Surg* 71(5):503–509. <https://doi.org/10.1097/SAP.0b013e3182a1aff0>
23. Monreal R (2017) free osteocutaneous fibular graft for infected bone defect of the ulna: case report. *Juniper Online J Orthop Orthoplastic Surg* 1(1):1–4. <https://doi.org/10.19080/JOJOOS.2017.01.555551>
24. ElSayed S, Sweed T, El Nakeeb R (2014) Vascularized fibular grafting for reconstruction of bone defect of the radius. *Egypt Orthop J* 49(3):193. <https://doi.org/10.4103/1110-1148.148185>
25. Soucacos PN, Korompilias AV, Vekris MD, Zoubos A, Beris AE (2011) The free vascularized fibular graft for bridging large skeletal defects of the upper extremity. *Microsurgery* 31(3):190–197. <https://doi.org/10.1002/micr.20862>
26. Windhofer C, Michlits W, Karlbauer A, Papp C (2011) Treatment of segmental bone and soft-tissue defects of the forearm with the free osteocutaneous lateral arm flap. *J Trauma Inj Infect Crit Care* 70(5):1286–1290. <https://doi.org/10.1097/TA.0b013e3182095df5>
27. Cavadas PC, Thione A (2014) Skeletal reconstruction of the forearm with a double-barrel fibular flap and second metatarsal head. *Injury* 45(12):2106–2108. <https://doi.org/10.1016/j.injury.2014.10.014>
28. Cano-Luís P, Andrés-Cano P, Ricón-Recarey FJ, Giráldez-Sánchez MA (2018) Treatment of posttraumatic bone defects of the forearm with vascularized fibular grafts. Follow up after fourteen years. *Injury* 49(Suppl 2):S27–S35. <https://doi.org/10.1016/j.injury.2018.07.021>
29. Gopisankar G, Justin ASV, Nithyananth M, Cherian VM, Lee VN (2011) Non-vascularised fibular graft as an intramedullary strut for infected non-union of the humerus. *J Orthop Surg (Hong Kong)* 19(3):341–345. <https://doi.org/10.1177/230949901101900316>
30. Wang C, Xu J, Wen G, Chai Y (2018) Reconstruction of complex tissue defect of forearm with a chimeric flap composed of a sural neurocutaneous flap and a vascularized fibular graft: a case report. *Microsurgery* 38(7):790–794. <https://doi.org/10.1002/micr.30334>
31. Molina AR, Ali E, van Rensburg L, Malata CM (2010) Successful reconstruction of a gunshot segmental defect of the radius with a free vascularised fibular osteocutaneous flap. *J Plast Reconstr Aesthetic Surg* 63(12):2181–2184. <https://doi.org/10.1016/j.bjps.2010.03.022>
32. Kashayi-Chowdojirao S, Vallurupalli A, Chilakamarri VK et al (2017) Role of autologous non-vascularised intramedullary fibular strut graft in humeral shaft nonunions following failed plating. *J Clin Orthop Trauma* 8:S21–S30. <https://doi.org/10.1016/j.jcot.2016.12.006>

33. Demir B, Ozkul B, Lapcin O, Beng K, Arikan Y, Yalcinkaya M (2019) A modification of internal bone transport method for reconstruction of nonunion of forearm. *Indian J Orthop* 53(1):196. https://doi.org/10.4103/ortho.IJOrtho_52_17
34. Birkholtz F, Greyling P (2016) Independent segmental bone transport of the radius and ulna: a case report. *SA Orthop J*. <https://doi.org/10.17159/2309-8309/2016/v15n2a4>
35. Liu T, Zhang X, Li Z, Zeng W (2012) Management of chronic radial head dislocation associated with segmental bone defect in ulna after osteomyelitis. *J Trauma Acute Care Surg* 73(4):1014–1017. <https://doi.org/10.1097/TA.0b013e318254a933>
36. Zhang Q, Yin P, Hao M et al (2014) Bone transport for the treatment of infected forearm nonunion. *Injury* 45(12):1880–1884. <https://doi.org/10.1016/j.injury.2014.07.029>
37. Ditsios K, Iosifidou E, Kostretzis L et al (2017) Combined bone transportation and lengthening techniques for the treatment of septic nonunion of the forearm followed by tendon transfer. *Case Rep Orthop* 2017:1–4. <https://doi.org/10.1155/2017/9672126>
38. Liu T, Liu Z, Ling L, Zhang X (2013) Infected forearm nonunion treated by bone transport after debridement. *BMC Musculoskelet Disord* 14(1):273. <https://doi.org/10.1186/1471-2474-14-273>
39. Eljabu W, Fabian C, Wissmann K, Reichstein K (2013) Segmental bone transport with the monorail technique in reconstructing a bone defect in the forearm. *JBJS Case Connect* 3(3):e87. <https://doi.org/10.2106/JBJS.CC.L.00298>
40. Liu Y, Yushan M, Liu Z, Liu J, Ma C, Yusufu A (2020) Treatment of diaphyseal forearm defects caused by infection using Ilizarov segmental bone transport technique. *BMC Musculoskelet Disord*. <https://doi.org/10.21203/rs.3.rs-97249/v1>
41. Kliushin NM, Stepanenko P, Mekki WA (2019) Treatment of forearm diaphyseal defect by distraction compression bone transport and continued distraction for radial head reduction: A case study. *Chinese J Traumatol = Zhonghua chuang shang za zhi* 22(5):304–307. <https://doi.org/10.1016/j.cjtee.2019.04.005>
42. Ebied A, Elseedy A (2018) Treatment of infected nonunion of forearm bones by ring external fixator. *Egypt Orthop J* 53:341–347. https://doi.org/10.4103/eoj.eoj_71_18
43. Borzunov DY, Shastov AL (2019) Mechanical solutions to salvage failed distraction osteogenesis in large bone defect management. *Int Orthop* 43(5):1051–1059. <https://doi.org/10.1007/s00264-018-4032-6>
44. Devendra A, Velmurugesan PS, Dheenadhayalan J, Venkatramani H, Sabapathy SR, Rajasekaran S (2019) One-bone forearm reconstruction. *J Bone Jt Surg* 101(15):e74. <https://doi.org/10.2106/JBJS.18.01235>
45. Wang Y, Zhou M, Wu Y, Ma Y, Liu J, Rui Y (2020) One-bone forearm reconstruction and distal radioulnar joint fusion for emergency one-stage operation in traumatic major bone defect of forearm. *Injury* 51(8):1828–1833. <https://doi.org/10.1016/j.injury.2020.06.024>
46. Kim SY, Chim H, Bishop AT, Shin AY (2017) Complications and outcomes of one-bone forearm reconstruction. *HAND* 12(2):140–144. <https://doi.org/10.1177/1558944716643305>
47. Jacoby SM, Bachoura A, DiPrinzio EV, Culp RW, Osterman AL (2013) Complications following one-bone forearm surgery for posttraumatic forearm and distal radioulnar joint instability. *J Hand Surg Am* 38(5):976-982.e1. <https://doi.org/10.1016/j.jhsa.2013.02.005>
48. Attias N, Thabet AM, Prabhakar G, Dollahite JA, Gehlert RJ, DeCoster TA (2018) Management of extra-articular segmental defects in long bone using a titanium mesh

- cage as an adjunct to other methods of fixation. *Bone Joint J* 100-B(5):646–651. <https://doi.org/10.1302/0301-620X.100B5.BJJ-2017-0817.R2>
49. Kerfant N, Valenti P, Kilinc AS, Falcone MO (2012) Free vascularised fibular graft in multi-operated patients for an aseptic non-union of the humerus with segmental defect: Surgical technique and results. *Orthop Traumatol Surg Res* 98(5):603–607. <https://doi.org/10.1016/j.otsr.2012.03.013>
 50. Kucukkaya M, Armagan R, Kuzgun U (2009) The new intramedullary cable bone transport technique. *J Orthop Trauma* 23(7):531–536. <https://doi.org/10.1097/BOT.0b013e3181a2a8e7>
 51. Kusnezov N, Dunn JC, Stewart J, Mitchell JS, Pirela-Cruz M (2015) Acute limb shortening for major near and complete upper extremity amputations with associated neurovascular injury: a review of the literature. *Orthop Surg* 7(4):306–316. <https://doi.org/10.1111/os.12213>
 52. Wang S, Li P, Xue Y, Yiu H, Li Y-C, Wang H (2013) Contralateral C7 nerve transfer with direct coaptation to restore lower trunk function after traumatic brachial plexus avulsion. *J Bone Jt Surg* 95(9):821–827. <https://doi.org/10.2106/JBJS.L.00039>
 53. Brady RJ, Dean JB, Skinner TM, Gross MT (2003) Limb length inequality: clinical implications for assessment and intervention. *J Orthop Sport Phys Ther* 33(5):221–234. <https://doi.org/10.2519/jospt.2003.33.5.221>
 54. Kiss S, Pap K, Vizkelety T, Terebessy T, Balla M, Szoke G (2008) The humerus is the best place for bone lengthening. *Int Orthop* 32(3):385–388. <https://doi.org/10.1007/s00264-007-0327-8>
 55. Liu T, Zhang X, Li Z, Zeng W, Peng D, Sun C (2008) Callus distraction for humeral nonunion with bone loss and limb shortening caused by chronic osteomyelitis. *J Bone Jt Surg Br* 90(6):795–800. <https://doi.org/10.1302/0301-620X.90B6.20392>
 56. Khan MS, Sahibzada AS, Khan MA, Sultan S, Younas M, Khan AZ (2005) Outcome of plating, bone grafting and shortening of non-union humeral diaphyseal fracture. *J Ayub Med Coll Abbottabad* 17(2):44–46. <http://www.ncbi.nlm.nih.gov/pubmed/16092650>
 57. Brennan ML, Taitsman LA, Barei DP, Puttler E, Nork SE (2008) Shortening osteotomy and compression plating for atrophic humeral nonunions: surgical technique. *J Orthop Trauma* 22(9):643–647. <https://doi.org/10.1097/BOT.0b013e318177eb23>
 58. Aronson J (1994) Temporal and spatial increases in blood flow during distraction osteogenesis. *Clin Orthop Relat Res* (301):124–131. <http://www.ncbi.nlm.nih.gov/pubmed/8156663>
 59. Chauhan C, Howard A, Saleh M (1995) Severely comminuted forearm fracture treated with acute shortening. *Injury* 26(6):415–416. [https://doi.org/10.1016/0020-1383\(95\)00036-9](https://doi.org/10.1016/0020-1383(95)00036-9)
 60. Sharma H, Colleary G, Marsh D (2004) Acute forearm shortening. *Injury* 35(5):531–533. [https://doi.org/10.1016/S0020-1383\(02\)00175-4](https://doi.org/10.1016/S0020-1383(02)00175-4)
 61. Masquelet AC, Fitoussi F, Begue T, Muller GP (2000) [Reconstruction of the long bones by the induced membrane and spongy autograft]. *Ann Chir Plast Esthet* 45(3):346–353. <http://www.ncbi.nlm.nih.gov/pubmed/10929461>
 62. Karger C, Kishi T, Schneider L et al (2012) Treatment of posttraumatic bone defects by the induced membrane technique. *Orthop Traumatol Surg Res* 98(1):97–102. <https://doi.org/10.1016/j.otsr.2011.11.001>
 63. Calori GM, Giannoudis PV, Mazzola S, Colombo M (2016) Application of the induced membrane technique for forearm bone defects. *Tech Orthop* 31(1):29–41. <https://doi.org/10.1097/BTO.000000000000139>

64. Pincher B, Fenton C, Jeyapalan R, Barlow G, Sharma HK (2019) A systematic review of the single-stage treatment of chronic osteomyelitis. *J Orthop Surg Res* 14(1):4–11. <https://doi.org/10.1186/s13018-019-1388-2>
65. Mathieu L, Durand M, Demoures T, Steenman C, Masquelet A-C, Collombet J-M (2020) Repeated induced-membrane technique failure without infection: a series of three consecutive procedures performed for a single femur defect. *Case Rep Orthop* 2020:1–7. <https://doi.org/10.1155/2020/8892226>
66. Mathieu L, Durand M, Collombet J-M, de Rousiers A, de l'Escalopier N, Masquelet A-C (2020) Induced membrane technique: a critical literature analysis and proposal for a failure classification scheme. *Eur J Trauma Emerg Surg*. <https://doi.org/10.1007/s00068-020-01540-9>
67. Barbieri CH, Mazzer N, Aranda CA, Pinto MM (1997) Use of a bone block graft from the iliac crest with rigid fixation to correct diaphyseal defects of the radius and ulna. *J Hand Surg Br* 22(3):395–401. [https://doi.org/10.1016/s0266-7681\(97\)80411-1](https://doi.org/10.1016/s0266-7681(97)80411-1)
68. Song H-R, Kale A, Park H-B et al (2003) Comparison of internal bone transport and vascularized fibular grafting for femoral bone defects. *J Orthop Trauma* 17(3):203–211. <https://doi.org/10.1097/00005131-200303000-00009>
69. Dumont CE, Exner UG (2009) Reconstruction of large diaphyseal defects of the femur and the tibia with autologous bone. *Eur J Trauma Emerg Surg* 35(1):17–25. <https://doi.org/10.1007/s00068-008-8224-4>
70. Hollenbeck ST, Komatsu I, Woo S et al (2011) The current role of the vascularized-fibular osteocutaneous graft in the treatment of segmental defects of the upper extremity. *Microsurgery* 31(3):183–189. <https://doi.org/10.1002/micr.20703>
71. Hallock GG (2005) Free-flap monitoring using a chimeric sentinel muscle perforator flap. *J Reconstr Microsurg* 21(6):351–354. <https://doi.org/10.1055/s-2005-915200>
72. Ferreira N, Marais LC (2015) Bone transport through an induced membrane in the management of tibial bone defects resulting from chronic osteomyelitis. *Strateg Trauma Limb Reconstr* 10(1):27–33. <https://doi.org/10.1007/s11751-015-0221-7>
73. Allende C, Allende BT (2004) Posttraumatic one-bone forearm reconstruction. *J Bone Jt Surg* 86(2):364–369. <https://doi.org/10.2106/00004623-200402000-00022>
74. Javaid M, Haleem A (2018) Additive manufacturing applications in orthopaedics: a review. *J Clin Orthop Trauma* 9(3):202–206. <https://doi.org/10.1016/j.jcot.2018.04.008>
75. Javaid M, Haleem A (2019) Current status and challenges of additive manufacturing in orthopaedics: an overview. *J Clin Orthop Trauma* 10(2):380–386. <https://doi.org/10.1016/j.jcot.2018.05.008>
76. Tetsworth K, Woloszyk A, Glatt V (2019) 3D printed titanium cages combined with the Masquelet technique for the reconstruction of segmental femoral defects. *OTA Int* 2(1):e016. <https://doi.org/10.1097/oi9.0000000000000016>
77. O'Malley NT, Kates SL (2012) Advances on the Masquelet technique using a cage and nail construct. *Arch Orthop Trauma Surg* 132(2):245–248. <https://doi.org/10.1007/s00402-011-1417-z>
78. Attias N, Lehman RE, Bodell LS, Lindsey RW (2005) Surgical management of a long segmental defect of the humerus using a cylindrical titanium mesh cage and plates. *J Orthop Trauma* 19(3):211–216. <https://doi.org/10.1097/00005131-200503000-00011>