

## **Case Report: Lightning-Induced Pneumomediastinum**

**Blumenthal, Ryan PhD\*; Saayman, Gert MD**

University of Pretoria, Pretoria, South Africa.

The authors report no conflict of interest.

\*Correspondence to: Ryan Blumenthal, PhD, Department of Forensic Medicine, University of Pretoria, P/Bag X323, Arcadia, 0007, Pretoria, South Africa. E-mail: [ryan.blumenthal@up.ac.za](mailto:ryan.blumenthal@up.ac.za).

### **Abstract**

Abstract: We present the case of a 41-year-old woman who was fatally injured during a witnessed lightning strike event and in whom autopsy revealed the unusual keraunopathological finding of overt pneumomediastinum. The possible pathophysiological mechanism(s) of causation of this phenomenon are discussed, with specific reference also to the “Macklin” effect and the role of blast overpressures associated with lightning strike. It is suggested that the latter may lead to sudden alveolar rupture, with subsequent rapid tracking of air along bronchovascular sheaths in a centripetal manner toward the hilum of the lung and thus into the mediastinum. A review of the blast literature suggests that this victim would have been exposed to a blast pressure wave of approximately 29-psi (200 kPa) to 72-psi (500 kPa) magnitude.

**Key Words:** lightning; keraunopathology; pneumomediastinum; surgical emphysema; traumatic emphysema; Macklin effect

### **BACKGROUND HISTORY**

In a witnessed incident, lightning struck at a busy informal taxi rank in Pretoria, South Africa, in immediate proximity to a small shelter that had been constructed for the purpose of selling fruit and vegetables. The 41-year-old female fruit vendor was immediately thrown to the ground and was unresponsive thereafter. There were no attempts at resuscitation. A 23-year-old woman (who was carrying her infant child) and who was purchasing vegetables from the vendor at the time, was also immediately struck down, but neither mother nor child sustained any notable injuries.

### **POSTMORTEM EXAMINATION**

The body of the victim was kept in a refrigerated state until the autopsy was performed approximately 72 hours later. No external injuries were identified, but the clothing of the victim was irregularly tattered and torn and showed burn marks in keeping with lightning strike. There was no rupture of the tympanic membranes. Upon removal of the chest plate, the striking and relatively widespread presence of fine air bubbles in the soft tissues of the

mediastinum was noted, extending around the esophagus and pericardial sac and being similar in appearance to that which is seen in traumatic emphysema (pneumomediastinum) (Figs. 1–3). No evidence of hemorrhage was present. There were no signs of pneumoperitoneum. No signs of autolysis or early decomposition were present. No other internal injuries or significant abnormalities were noted macroscopically. Histology of the lungs showed disruption of the normal pulmonary parenchymal architecture, with irregularly overdistended peripheral air spaces and attenuated and ruptured alveolar walls, with minimal intra-alveolar red blood cell accumulations. Toxicological analysis was negative. The probable mechanism of death was thought to be due to lightning's effect on the cardiovascular and/or neurological systems.

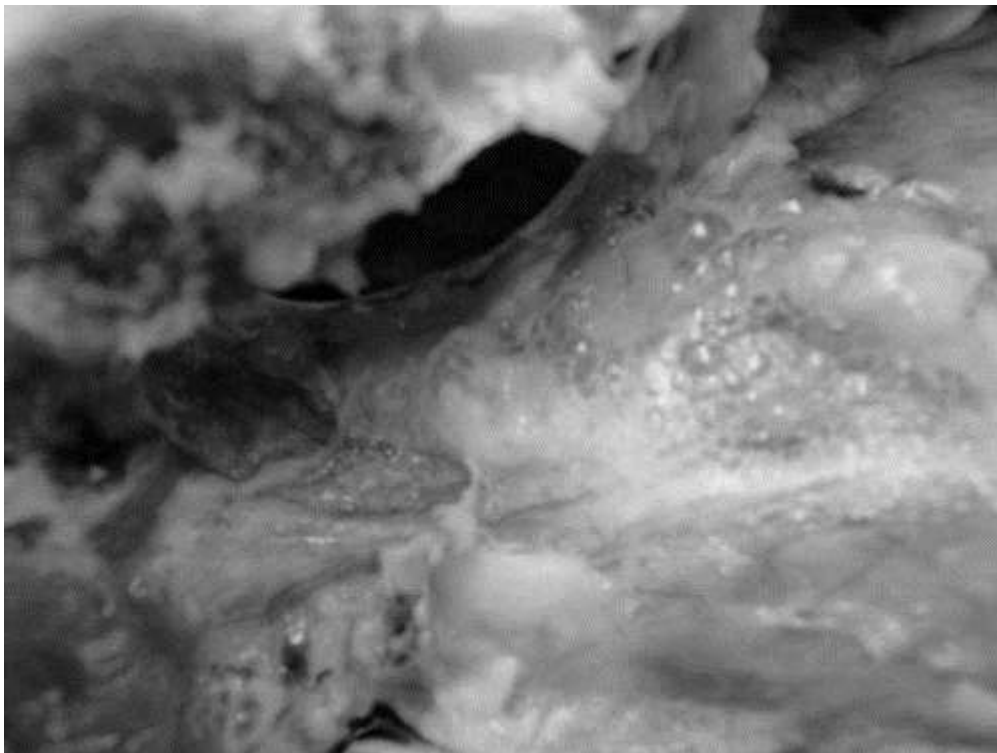


FIGURE 1. Upon removal of the chest plate, the striking and relatively widespread presence of fine air bubbles in the soft tissues of the mediastinum was noted, extending around the esophagus and pericardial sac and being similar in appearance to that which is seen in traumatic emphysema (pneumomediastinum).




FIGURE 2. Histology of the lungs showed disruption of the normal pulmonary parenchymal architecture, with irregularly overdistended peripheral air spaces as well as attenuated and ruptured alveolar walls, with minimal intra-alveolar red blood cell accumulations.

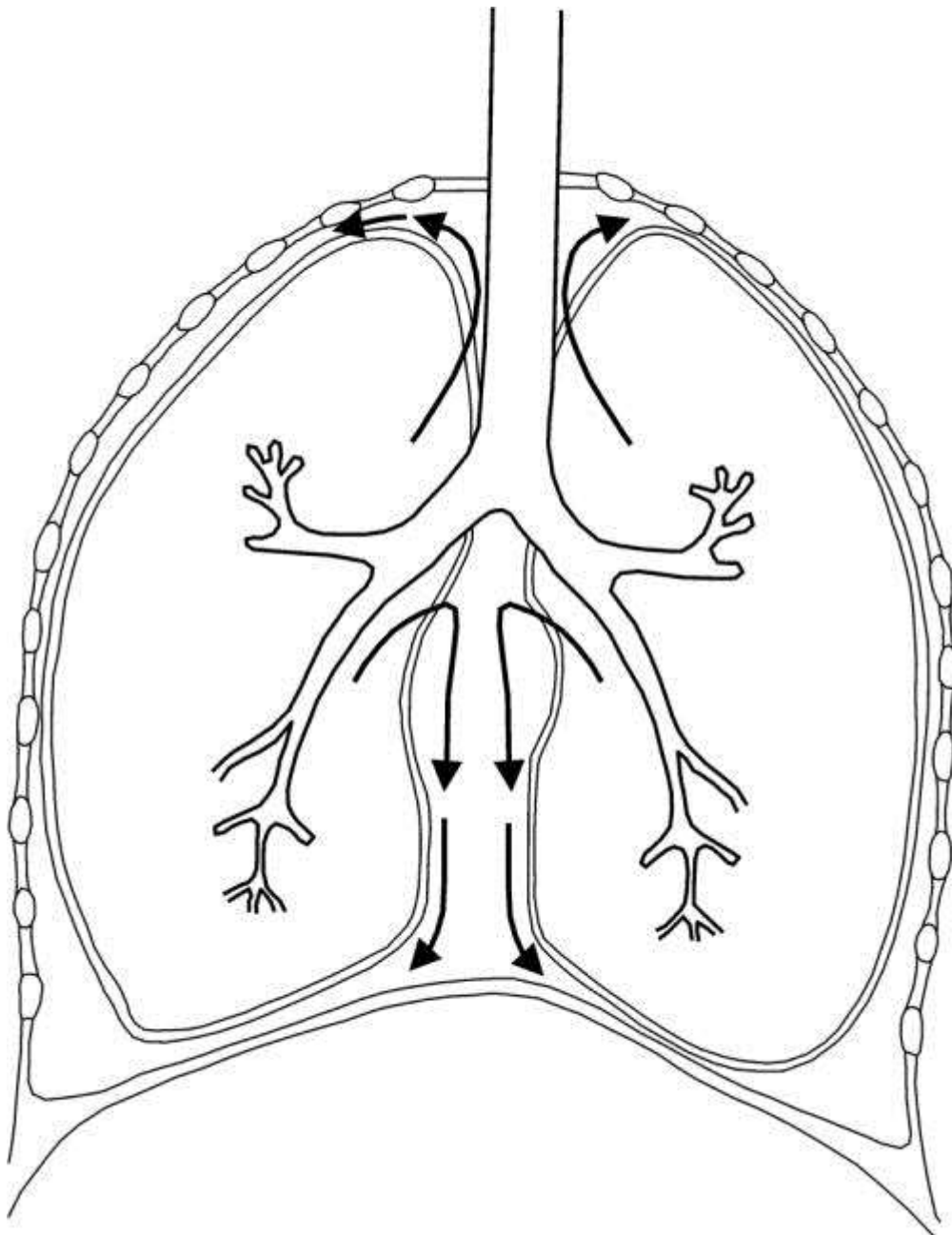


FIGURE 3. Schematic representation of the possible pathophysiology behind overt traumatic emphysema (pneumomediastinum). The black arrows represent air escaping from ruptured alveoli into the surrounding soft tissues. According to Macklin, the air does not reach the mediastinum through the visceral pleura, but rather through bronchovascular sheaths.<sup>3</sup>

## DISCUSSION

Pneumomediastinum, otherwise known as mediastinal emphysema, relates to air collection within the mediastinal structures.<sup>1,2</sup> A frequent etiology for pneumomediastinum has been ascribed to blunt chest trauma; the associated pathophysiologic process was first described by Macklin in 1939—which has subsequently been referred to as the “Macklin effect.”<sup>3</sup> Pneumomediastinum has also been reported in various other conditions, such as neonatal respiratory distress syndrome, asthma crises, positive-pressure mechanical ventilation, Valsalva maneuvers (parturition, Boerhaave syndrome, and even epileptic seizures).<sup>1</sup> The mediastinal air is thought to arise by various routes or mechanisms: tracheobronchial or

esophageal rupture may create a direct air leak into the mediastinum, whereas the Macklin effect is thought to involve alveolar rupture with air dissection along bronchovascular sheaths toward the hilum of the lung and consequently into the mediastinum.<sup>3</sup>

Pneumomediastinum associated with lightning was reported by Halldorsson and Couch<sup>4</sup> in 2004, in a 28-year-old lightning strike survivor who underwent computed tomography scan examination. The mechanism of injury was thought to be due to a blast effect caused by a sudden large fluctuation in temperature close to the victim's body.<sup>4</sup> Lightning may cause almost instantaneous superheating and expansion of air close to the victim's body, followed almost immediately by an implosion as the air rapidly cools.<sup>4</sup> Halldorsson and Couch believed that this explosion/implosion phenomenon surrounding lightning's luminous channel may cause trauma, which may mimic the patterns of blast injuries seen in bomb blast victims. Pneumomediastinum after blunt trauma is rare without associated pneumothorax. Blast injuries to the lungs in victims of lightning strike have been previously reported by Moulson<sup>5,6</sup> and Soltermann et al.<sup>5,6</sup> Recently, a sixth mechanism of lightning injury was proposed, which may be thought of as a "pressure-shock wave," which is directly proportional to the current of the lightning discharge and which is present immediately surrounding lightning's luminous channel.<sup>7,8</sup>

Tympanic membrane rupture may be seen in such victims.<sup>9-14</sup> A review of the otolaryngological literature suggests that rupture of the normal eardrum is a function of age as well as of the effective blast pressure. A study by Richmond et al.<sup>15</sup> suggests a minimum threshold of about 29 psi (200 kPa) to produce minor eardrum ruptures. One can therefore deduce from human victims with tympanic membrane rupture that lightning's blast wave must have had a minimum overpressure of approximately 29 psi (200 kPa).<sup>15</sup> A review of the chest and lung medical literature suggests that approximately 29 psi (200 kPa) to 72 psi (500 kPa) is required to induce lung damage.<sup>16</sup>

The diagnosis of traumatic pneumomediastinum is not generally a cause for alarm among clinicians, and it is not often deemed to be a fatal entity. Blunt thoracic trauma pneumomediastinum is thought to be a benign and self-limiting condition among clinicians, with spontaneous regression to be expected within about a week.<sup>17</sup>

We know also that lightning victims do not commonly have severe blast-related disfigurement. To be injured by a blast wave, one has to be in the immediate vicinity of the explosion, within about 1 m. About 100 psi (690 kPa) is the minimum threshold for serious damage to humans.<sup>18</sup> We can therefore deduce from the barotrauma literature that lightning's blast wave must be less than 100 psi (690 kPa).

## CONCLUSION

We present a case of pneumomediastinum in a middle-aged woman who was fatally injured during a lightning strike and in whom no other plausible explanation for the phenomenon could be identified. It is proposed that the effect of lightning's blast wave resulted in acute alveolar rupture, with tracking of air into the mediastinum via the hilar regions of the lungs.

Research has indicated that it is possible to estimate the minimum overpressure to which a lightning victim was exposed, based on features of barotrauma as seen at autopsy.<sup>16</sup> The presence of pneumomediastinum at autopsy, which cannot readily be ascribed to any other mechanism of causation, suggests that the victim in this instance had been exposed to a

lightning-induced blast overpressure (barotrauma) of approximately 29-psi (200 kPa) to 72-psi (500 kPa) magnitude.

## ACKNOWLEDGMENT

The authors would like to thank and acknowledge the permissions and authorizations granted by the South African Police Services, the Director of Public Prosecutions, and the Ethics and Integrity Committee of the University of Pretoria.

## REFERENCES

1. Wintermark M, Schnyder P. The Macklin effect: a frequent etiology for pneumomediastinum in severe blunt chest trauma. *Chest*. 2001;120:543–547.
2. Assenza M, Passafiume F, Valesini L, et al. Pneumomediastinum and pneumoperitoneum after blunt chest trauma: The Macklin effect. *J Trauma Treatment*. 2012; doi:10.4172/jtm.1000107.
3. Macklin CC. Transport of air along sheaths on pulmonic blood vessels from alveoli to mediastinum: clinical implications. *Arch Intern Med*. 1939;64:913–926.
4. Halldorsson A, Couch MH. Pneumomediastinum caused by a lightning strike. *J Trauma*. 2004;57:196–197.
5. Moulson AM. Blast injury of the lungs due to lightning. *Br Med J (Clin Res Ed)*. 1984;289:1270–1271.
6. Soltermann B, Frutiger A, Kuhn M. Lightning injury with lung bleeding in a tracheotomized patient. *Chest*. 1991;99:240–242.
7. Blumenthal R, Jandrell IR, West NJ. Does a sixth mechanism exist to explain lightning injuries? investigating a possible new injury mechanism to determine the cause of injuries related to close lightning flashes. *Am J Forensic Med Pathol*. 2012;33:222–226.
8. Blumenthal R, West NJ. Investigating the risk of lightning's pressure blast wave. *S Afr J Sci*. 2015;111(3/4), Art. #2014-0187, 5 pages. <http://dx.doi.org/10.17159/sajs.2015/20140187>.
9. Redleaf MI, McCabe BF. Lightning injury of the tympanic membrane. *Ann Otol Rhinol Laryngol*. 1993;102:867–869.
10. Gordon MA, Silverstein H, Willcox TO, et al. Lightning injury of the tympanic membrane. *Am J Otol*. 1995;16:373–376.
11. Jones DT, Ogren FP, Roh LH, et al. Lightning and its effects on the auditory system. *Laryngoscope*. 1991;101:830–834.
12. Bergstrom L, Neblett LW, Sando I, et al. The lightning-damaged ear. *Arch Otolaryngol*. 1974;100:117–121.
13. Kristensen S, Tveterås K. Lightning-induced acoustic rupture of the tympanic membrane: (a report of two cases). *J Laryngol Otol*. 1985;99:711–713.
14. Gluncic I, Roje Z, Gluncic V, et al. Ear injuries caused by lightning: report of 18 cases. *J Laryngol Otol*. 2001;115:4–8.

15. Richmond DR, Yelverton JT, Fletcher ER, et al. Physical correlates of eardrum rupture. *Ann Otol Rhinol Laryngol Suppl.* 1989;140:35–41.
16. Blumenthal R. The explosive effects of lightning: what are the risks? *Acad Forensic Pathol.* 2016;6:89–95.
17. Bouwen L, Bosmans E. Posttraumatic pneumomediastinum: not always cause for alarm. *Acta Chir Belg.* 1997;97:145–147.
18. Saukko P, Knight B. *Knight's Forensic Pathology.* 3rd ed. London: Arnold Publishers; 2004:274–275.